
Radiographical outcomes of fixed dental prosthesis abutment teeth (Retrospective study)

*Enas A.Khamakhim

**Seham A. Elsaawaay

■ Abstract

The aim of the present study was to evaluate abutments of crowns and conventional fixed dental prosthesis in terms of complying Ante's law, and periapical lesions through a retrospective analysis of orthopantomographs (OPTGs) of patients in private dental clinic. In this study, the digital OPTGs of adult patients between the ages of 30 and 75 who appealed to private dental clinic for the first time to have their fixed prosthetic treatment needs met were used. The routine dental radiographs were taken in the first appointment of the patients. The periapical health of all teeth restored with crowns and bridges were evaluated by radiographic criteria according to periapical index (PAI). The present study comprised panoramic radiographs belongs to 43 women and 27 men with an age range of 30 to 75 years old. No relationship was observed between gender and periapical lesion. While the amount of fixed prosthesis was highest in the lower jaw with 54%. The most commonly used abutment tooth were premolar teeth. 36% of bridges didn't meet the requirements of Ante's law. More periapical lesion were observed among the restorations which doesn't meet the requirements of Ante's law. According to the results of the present study, the restoring of missing teeth with FPDs may cause different periapical pathologies. Optimum evaluation of abutments regarding to Ante's law and periapical status may decrease the complications that could be observed in long term prognosis of FPDs

● **Key words:** Abutment teeth, radiology, fixed partial denture, periapical index, and Ante's law.

*Staff member at Faculty of Dentistry, Tripoli University/ Libya

** Staff member at Faculty of Dentistry, Tripoli University/ Libya

■ **Introduction:**

Most textbooks on prosthodontics and dental occlusion have stated that tooth loss often to be replaced because the masticatory system needs a complete dentition. Many studies have refuted this statement, and the successful application of the SDA concept has indicated that tooth loss and its sequelae have been over-dramatized in the past (Gerritsen AE. *et.al.* 2013 pp59-66).

However, most patients who have lost teeth, especially in the anterior part of the mouth, wish to have them replaced. There is a number of treatment options for tooth replacement.

Crowns may be utilized to improve appearance of discolored or malformed teeth. They are also utilized to confer protection and to restore form and function to teeth which may be compromised due to loss of tooth structure. The loss of tooth structure may occur due to caries, endodontic procedures, erosion, abrasion, attrition or trauma. Crowns are also indicated as retainers for fixed partial dentures.

While their approved long term success (Pjetursson, *et.al.* 2015 pp24-39) and low cost make fixed partial dentures (FPD), one of the option therapy for both clinicians and patients to treat missing tooth/teeth. Tooth preparation for FPDs causes extensive loss of intact enamel and dentin. In the dental literature numerous papers describe the failures caused from biological factors such as secondary caries, periapical lesions and tooth loss related to FPD treatments because of extensive tooth substance loss, use of variety of dental materials and operative procedures harmful to the dental pulp (Jun S, *et.al.* 2017 pp 81-92)

The treatment decisions for patients requiring crowns and fixed partial dentures should be based on sound scientific evidence, treatment needs and desires of the patient, clinical factors in the oral cavity, the patient's economic circumstances and skillful clinician. Several complications may arise related to crown and fixed partial denture work, these include biological, mechanical and esthetic complications which if unattended may lead to eventual loss of prosthesis and the abutment teeth (Patel DR, *et.al* 2014 pp421-433). The scientific evidence can be acquired from an evaluation of treatment outcomes which will reveal survival, successes, failures and complications of various treatment modalities.

Most of research papers investigating the survival of restorations define the survival of a FPD as remaining the prosthesis in situ or without modification over the study period. On the other hand, periapical status of a FPD has a

major importance related to survival rate of treatment because the periapical status determine the prognosis of abutments and also FPDs (Pol C, *et.al* 2018).

Orthopantomographs is a widely accepted radiographic technique which produces a single image of the facial structures including both maxillary and mandibular teeth and jaws with TM joints. It is widely used for screening patients before any prosthodontics treatment as it may reveal roots, cysts, foreign bodies and even neoplasms in completely edentulous jaws with no clinical signs (Ahlqwist, *et.al.*1986 pp79–84). It helps in evaluation of resorptive changes of the jaws (Rushton, *et.al.* 2002 pp 275–279). However, if some teeth are present in the patient’s jaws it may offer even more useful information. Although panoramic radiograph is affected by both magnification errors and displacement, it has been proved that linear dimensions of the structures on the radiogram are similar to the actual dimensions of the filmed structures, as long as the distances measured do not traverse the midline (Stamatakis, *et.al.* 2000 pp 28–34). The radiation dose is significantly lower for orthopantomographic radiographs in comparison with the dose needed for oral status using retroalveolor radiographs (White, *et.al.* 1999).

Although there seemed to be no standard criteria for the registration of Apical Periodontitis (AP) in epidemiological surveys, either for periapical radiographs or panoramic radiographs, recently the ‘periapical index’ (PAI) scoring system has been modified and applied to epidemiological (Jime´nez, *et.al.* 2004 pp167–173) and clinical comparative of treatment outcome (Segura,*et.al.* 2005 pp 564–569). The possibility of comparisons amongst studies carried out with calibrated observers makes this system attractive (Huomonen, *et.al.* 2002 pp 3–25). PAI provides an ordinal scale of five scores ranging from healthy to severe periodontitis with exacerbating features. The PAI is based on reference radiographs with verified histological diagnoses published originally by Brynolf 1967 (Brynolf, 1967 pp 1–176). PAI was first described for periapical radiographs by Ørstavik *et al.*1986 (Ørstavik, *et.al.*1986 pp 20–34), but some epidemiological studies have used PAI for panoramic radiographs (De Cleen, *et.al.*1993 pp 112–119), or a combination of panoramic radiographs and periapical radiographs (Eriksen and Bjertness, 1991 pp1–4).

■ Aim of the study

The aim of this study was to radiographically examine Ante’s law, and the periapical status of rootfilled and non rootfilled abutment teeth restored with crowns or bridge retainers in private dental clinic in Tripoli.

Materials & Methods:

Study Sample:

Present study is conducted at the Al-Shams private dental clinic. Panoramic radiographs evaluated in the present study were routine dental radiographs taken in the first appointment of the patients and none of the panoramic radiograph was taken for the methodology of the present study. Totally 70 panoramic radiographs (43 females and 27 male) were evaluated that belongs to the patients applied to the clinics taken from patient files. Current FPDs were evaluated in terms of complying «Ante's law» and periapical lesions of abutments radiographically.

Ante's laws states that: «the total periodontal membrane area of the abutment teeth must equal or exceed that of the teeth to be replaced».

A total of 205 FPDs (125 bridges and 80 single crowns) of participants were evaluated radio graphically.

■ Data Records:

Selected 70 adult patients (aged between 30 and 75) having fixed partial dentures. From patients files and radiographic department computer the information regarding age and gender, number of units of fixed partial denture, number of abutment teeth, number and location of rootfilled abutment teeth with and without AP, number of non rootfilled abutment teeth with AP, and number of crowns, fixedfixed bridges, and cantilever bridges was recorded on a customized form for each patient. Impacted teeth and implant were excluded. The teeth appear in panoramic view with radiopaque material (Pulpotic) in coronal/ and or in radicular area (Root Canal Treated) were regarded as rootfilled.

The data obtained were registered to Microsoft Excel program (Microsoft Excel 2007) by two dentists.

■ Radiographic Measurements:

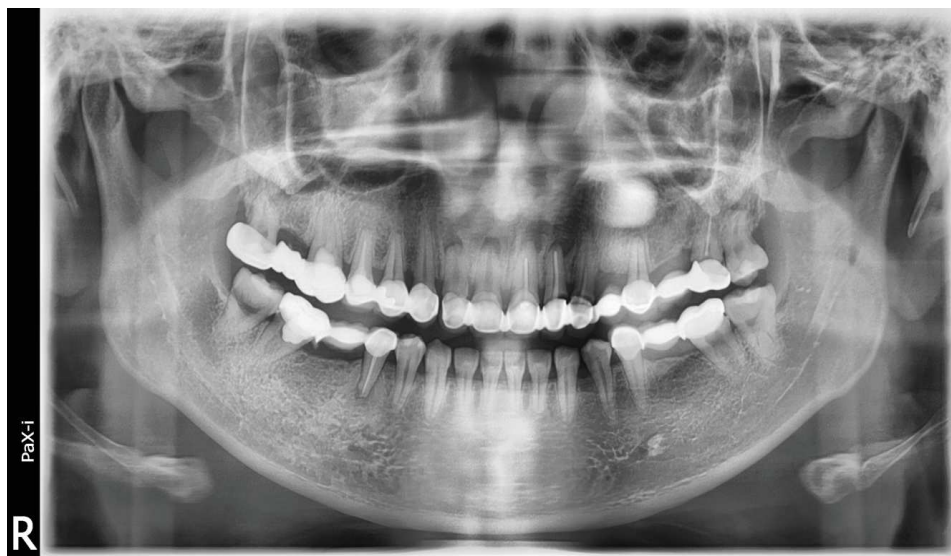Radiographs were routine diagnostic digital images which were taken using a digital x-ray imaging system (Vatech, KOREA) with standard exposure values (90 Kvp,10 Ma, 18 sec) in order to evaluation current status of patients before any dental approach. Measurement and interpretation were performed with paX-i version (2012). The method of viewing the periapical radiographs was standardized. The interpretation of radiographs was performed independently by two specialist with extensive clinical experience

in fixed dental prosthesis and endodontics, radiographs of randomly selected 70 individuals were double scored at 5-months intervals.

The “periapical index” (PAI) was used in the assessment and categorization of the periapical health status of rootfilled abutment teeth. PAI is a visual fivepoints index which has an ordinal scale of five scores ranging from healthy periapical bone to severe AP and is proposed by (Ørstavik, et. al.1986).

Description of the PAI scoring system is; I- Normal periapical structures, II- Small changes in bone structure, III- Changes in bone structure with some mineral loss, IV- Periodontitis with well-defined radiolucent area, V- Severe periodontitis with exacerbating features was considered to be a sign of periapical pathology PAI III, IV and V (PAI > 2). Class II is a stage to observe histological symptoms and there is no a visible sign of bone destruction. Class II stage is included in the Class I stage because that evaluation was made on the radiographically in the present study. (Figure 1).

Abutments teeth were recorded. Cantilevers were recorded and the periapical status of abutment teeth were evaluated. Restorations were assessed in terms of complying the requirements of Ante’s law and recorded as “Complies” or “Does not comply”.



Figure(1) Panoramic radiograph represent periapical changes of abutments of fixed dental prosthesis

■ **Results:**

The survey was carried out using the OPTGs of 70 adult patients composed of 43 women and 27 men aged between 35 and 70. 414 teeth served as abutments of crowns and bridges. The fixed dentures were either single crowns ($n = 80$), fixedfixed bridges ($n = 114$), cantilever bridges ($n = 11$). While the amount of fixed prosthesis was highest in the lower jaw with 54%. The most commonly used abutment tooth were premolar teeth.

11.2% of patients had cantilever on their FPDs. Cantilevers were mostly used to restore the lower and upper first premolar teeth region.

Among 70 patients, 213 of the total 414 abutment teeth were rootfilled and 119 (55.87%) of them presented signs of AP radiologically, while 201 of the total abutment teeth were non rootfilled and 111 (55.22%) of them were with AP (Table 1).

No relationship was observed between gender type and periapical lesion existence (Table2) and (Figure2). 36% of bridges didn't meet the requirements of Ante's law.

Among 125 bridges, 45 of the total 125 bridges were not comply Ant's Law and with AP, while 80 of the total bridges were comply Ant's Law and 72 of them were with AP (Table 3) (Figure 3).

Table (1) Distribution of the radiographically examined abutment teeth according to periapical status

Periapical status	Root filled abutment teeth	Non root filled abutment teeth	Total
With apical periodontitis	(55.87%) 119	(55.22%)111	230 (55,56%)
Without apical periodontitis	(44.13%) 94	(44.78%) 90	184 (44,44%)
Total	(100%) 213	(100%) 201	(100%) 414

Table (2) Relationship between periapical lesion and sex

Periapical lesion	Women	Men	Total
Not exist	(6.98%) 3	(3.70%) 1	(5.71%) 4
Exist	(93.02%) 40	(96.30%) 26	(94.29%) 66
Total	(100%) 43	(100%) 27	(100%) 70

Table (3) Relationship between periapical lesion and Ante's law

Periapical lesion	Ante's Law		Total
	Not comply	Comply	
Not exist	0	(10%) 8	(6.4%) 8
Exist	(100%) 45	(90%) 72	(93.6%) 117
Total	(100%) 45	(100%) 80	(100%) 125

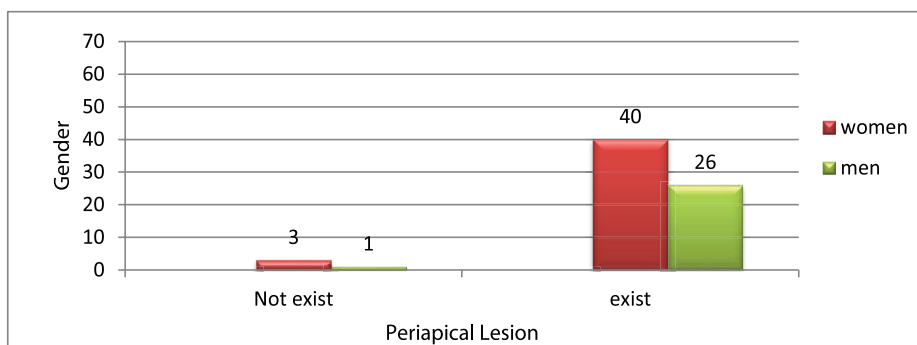


Figure (2) Relationship between periapical lesion and sex

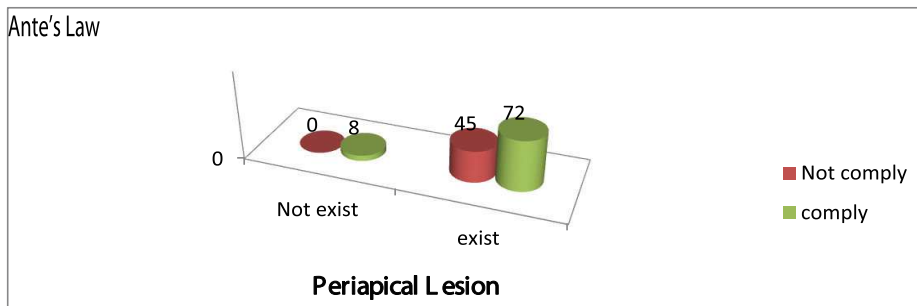


Figure (3) Relationship between periapical lesion and Ante's law

■ Discussion:

There is a lack of data available on the quality of recording and reporting outcome measurements in tooth-supported fixed prostheses. Furthermore, there is evidence showing improvements in reporting radiological outcome measurements of fixed prostheses in recent years (Patel, et.al. 2014 pp 421–433). However, an understanding of favorable indications and reasonable limitations of abutments for fixed partial dentures is essential (Talabani, 2016 pp 1-7). In the evaluation of the periapical health, as the absence of clinical symptoms may be misleading, histological examination is the ideal approach but is not clinically applicable. Therefore, radiographic examination is the main method in the determination of the periapical health of teeth. The use of OPTGs, taken as general screening radiographs, was preferred in this study because of their availability. Since OPTGs enable the visualization of all teeth on one radiograph and provide lower patient radiation doses, their use in epidemiological studies is supported (Molander, et.al. 1995 pp191-198). On the other hand, it is commonly argued that this imaging technique does not allow the precise analysis of periapical health. De Cleen et al., 1993 studied the prevalence of peri-radicular disease using OPTGs and he was found that the periapical status of a considerable number of teeth could not be classified due to difficulties in interpretation. The objective of this study was to assess the radiographic periapical changes in teeth restored with crowns and bridges as well as complying Ant's law.

Three different indices have been proposed for evaluation of periapical health (Reit and Gröndahl 1983 pp213-218). The main reason for choosing the PAI scoring system was that it had been increasingly used to evaluate periapical health conditions in recent years. Furthermore, PAI presents good accuracy and reproducibility (intra- and inter-observer agreement). The two observers in each group with the highest agreement rates for panoramic radiography similar to the technique adopted by Kaffe and Gratt 1991.

In this study, the dividing line between healthy and diseased periapical status has been set between scores II and III as in most of the epidemiological studies using the PAI. However, it is questionable whether this dichotomization represents a real borderline between healthy and pathologic periapical status.

According to the results of the present study found that the amount of fixed

prosthesis was highest in the lower jaw with 54%. This was in controversial with TURKER N et al. 2019, who reported that the amount of restoration was highest in the upper jaw with 56%. While we were in the same line that the most used abutment tooth for FPDs were second premolars. The reason may be originated from the early loss of mandibular first molars since first molars were the first teeth erupted in the oral cavity.

There is no significant gender correlation with the occurrence of AP however, in this study female more prone to replace missing teeth than male, and this may be due to women have more awareness to restore the same than men.

The results of this study also showed 11.2% of patients had cantilever on their FPDs. Cantilevers were mostly used to restore the lower and upper first premolar teeth region. This finding might be due to orthodontic extractions, or fracture of weekend endodontically treated premolars. This finding is similar to the findings of other studies (Hochman, et.al. 2003 pp165-170).

167 bridge were assessed for their compliance to Ante's law by Leempoel et.al.1995, they stated that the bridges which didn't meet the requirements of Ante's law had shorter survival rate. Although, Balevi, et.al.2012 claimed that Ante's law is not "evidence based". Periapical status presence and their relationship with Ante's law were assessed in our study, 45 of the total 125 bridges didn't comply Ant's Law and with AP, while 80 of the total bridges were comply Ant's Law and 72 of them were with AP since the long span bridges bend much more than short.

On the other hand, Nyman and Ericsson, 1982 monitored the restorations which didn't meet the requirements of Ante's Law about 8-11 years and they observed that there were not periodontal problem or bone loss. One of the some limitation of the present study was that there were no any clinical or radiographical information about condition of abutment teeth and periodontal tissues prior to FPD treatment. Another limitation is the lifetime of the bridges did not investigated because of the study was retrospective and performed only on the dental radiograph.

Among 70 patients, 213 of the total 414 abutment teeth were rootfilled and 119 of them presented signs of AP radiologically. A comparison of the results of this study with previous studies seems controversial due to variations

in study design, population selection, evaluation criteria, and length of the observation period. Saunders and Saunders, 1998 reported the frequency of AP to be 19% for non rootfilled and 51% for rootfilled crowned teeth. In this study, these values were found to be 55, 22% and 55, 87% respectively.

■ **Conclusions:**

According to the results of the present study, the rehabilitation of edentulous regions with conventional FPDs may cause different periapical pathologies. Ideal planning of FPDs and careful evaluation of abutments regarding to Ante's law and periapical status may decrease the complications that could be observed in long term prognosis of FPDs. Follow up appointments may be a critical point in evaluation of abutments both clinically and radiographically.

■ **References:**

- 1- Gerritsen AE, Witter DJ, Bronkhorst EM, and Creugers NH. An observational cohort study on shortened dental arches—clinical course during a period of 27-35 years. *Clin Oral Investig.* 2013; 17:859-66.
- 2- Pjetursson BE, Sailer I, Makarov NA, Zwahlen M, and Thoma DS. All-ceramic or metal-ceramic tooth-supported fixed dental prostheses (FDPs)? A systematic review of the survival and complication rates. Part II: Multiple-unit FDPs. *Dent Mater.* 31:624-39 ;2015 .
- 3- Jun S, Mahapatra C, Lee H, Kim H, and Lee J. Biological effects of provisional resin materials on human dental pulp stem cells. *Oper Dent.* 2017; 42:E81-92.
- 4- Patel DR, O'Brien T, Petrie A, and Petridis H. A Systematic Review of Outcome measurements and Quality of Studies Evaluating fixed Tooth-Supported Restorations. *J prosthodont.* 2014; 23:421-33.
- 5- Pol C, Raghoobar G, Kerdijk W, Boven C, Cune M, and Meijer H. A systematic review and meta-analysis of three-unit fixed dental prostheses: are the results of two abutment implants comparable to the results of two abutment teeth. *J oral rehabil.* 2018.
- 6- Ahlqwist JR, Halling A, and Hollender L. Rotational panoramic radiography in epidemiological studies on dental health. *Swed Dent J.* 1986; 10, 79–84.
- 7- Rushton VE, Horner K, and Worthington HV. Screening panoramic radiography of new adult patients: diagnostic yield when combined with bitewing radiography and identification of selection criteria. *Br Dent J.* 2002; 9, 275–9.
- 8- Stamatakis HC, Welander U, and McDavid WD. Physical properties of a photostimulable phosphor system for intraoral radiography. *Dentomaxillofac Radiol.* 2000; 29, 28–34.
- 9- White SC, and Pharoah MJ. *Principles and Interpretation of Oral radiology*, 4th edn. St Louis, MO: Mosby (Harcour Health Sciences). 1999.
- 10- Jimenez-Pinzo'n A, Segura-Egea JJ, Poyato-Ferrera M, Velasco- Ortega E, and Ríos-Santos JV. Prevalence of apical periodontitis and frequency of root filled teeth in an adult Spanish population. *Int Endod J.* 2004; 37, 167–73.
- 11- Segura-Egea JJ, Jimenez-Pinzo'n A, Ríos-Santos JV, Velasco- Ortega E, Cisneros-Cabello R, and Poyato-Ferrera MM. High prevalence of apical periodontitis amongst type 2 diabetic

- patients. *Int Endod J.* 2005; 38, 564–9.
- 12-Huomonen S, and Ørstavik S. Radiological aspects of apical periodontitis. *Endod Topics.* 2002; 1, 3–25.
 - 13-Brynolf I. A histological and roentgenological study of the periapical region of human upper incisors. *Odontologisk.* 1967; Revy 18(Suppl. 11) 1–176.
 - 14-Ørstavik D, Kerekes K, and Eriksen HM. The periapical index: a scoring system for radiographic assessment of apical periodontitis. *Endod Dent Traumatol.* 1986; 2, 20–34.
 - 15-De Cleen MJ, Schuurs AH, Wesselink PR, and Wu MK. Periapical status and prevalence of endodontic treatment in an adult Dutch population. *Int Endod J.* 1993; 26, 112–9.
 - 16-Eriksen HM, and Bjertness E. Prevalence of apical periodontitis and results of endodontic treatment in middle-aged adults in Norway. *Endod Dent Traumatol.* 1991; 7, 1–4.
 - 17-Patel RD, Tim OB, Petrie A, and Haralampos P. A Systematic Review of Outcome Measurements and Quality of Studies Evaluating Fixed Tooth-Supported Restorations. *J Prosthodont.* 2014; 23, 421–33.
 - 18-Talabani RM. Influence of abutment evaluation on designing of fixed partial denture: A clinical study. *Int J Oral Health Med Res.* 2016; 3:1-7.
 - 19- Muhammed AH, Manson Hing LR, and Ala B. A comparison of panoramic and intraoral radiographic surveys in evaluating a dental clinic population. *Oral Surg Oral Med Oral Pathol* 1982; 54:108-17.
 - 20- Molander B, Ahlqwist M, and Gröndahl HG. Panoramic and restrictive intraoral radiography in comprehensive oral radiographic diagnosis. *Eur J Oral Sci* 1995; 103:191-8.
 - 21- Reit C, and Gröndahl HG. Application of statistical decision theory to radiographic diagnosis of endodontically treated teeth. *Scand J Dent Res* 1983;91:213-8.
 - 22- Rohlin M, Kullendorff B, Ahlqwist M, and Stenstrom B. Observer performance in the assessment of periapical pathology: a comparison of panoramic with periapical radiography. *Dentomaxillofac Radiol*, 1991.
 - 23- Türker N, Özarlan M, Büyükkaplan UŞ, and Özarlan MM. Radiographical assessment of fixed partial denture abutment teeth. *Med J SDU.* 2019; 26: 1-7.
 - 24- Hochman N, Mitelman L, Hadani P, and Zalkind M. A clinical and radiographic evaluation of fixed partial dentures (FPDs) prepared by dental school students: a retrospective study. *J oral Rehabil.* 2003;30:165-70.
 - 25- Leempoel P, Käyser A, Rossum G, and HAAN A. The survival rate of bridges. A study of 1674 bridges in 40 Dutch general practices. *J oral rehabil.* 1995;22:327-30.
 - 26-Balevi B. Ante's law is not evidence based. *J Am Dent Assoc.* 2012;143:1011-2.
 - 27-Nyman S, and Ericsson I. The capacity of reduced periodontal tissues to support fixed bridgework. *J Clin periodontal.* 1982;9:409-14.
 - 28- Saunders WP, and Saunders EM. Prevalence of periradicular periodontitis associated with crowned teeth in an adult Scottish subpopulation. *Br Dent J.* 1998;185:13740.