

Influence of rapid unilateral mandibular lengthening by distraction osteogenesis on the temporomandibular Joint (An experimental study)

Elsagaly A.H. *, Abd Elmonem K. **, Metwalli S.A. ***, and Elkasaby M.***

* Lecturer, Oral and Maxillofacial Surgery, Tripoli University.

** Lecturer, Oral and Maxillofacial Surgery, Ain Shams University.

***Assistant professor, Oral and Maxillofacial surgery, Ain Shams University.

Corresponding Author: k.monem74@gmail.com

Abstract : Purpose: Evaluation of the effect of unilateral mandibular lengthening by distraction osteogenesis at a rapid, hyperphysiologic, rate of 2 mm per day on the temporomandibular joint. **Materials and Methods:** Eighteen young adult healthy female goats weighing 20-25Kg were included in the study. Animals were divided into 3 equal groups (n=6 in each): group I(control), while group II and III (the experimental groups). All animals of group II, III were subjected to unilateral mandibular body lengthening of the right mandibular side by distraction osteogenesis through the use of custom made stainless steel distractor. Distraction was performed at a rate of 2 mm per day for five days and a consolidation phase for four weeks. Animal sacrifice was performed post consolidation phase by one month in group II and by 6 months in group III. All temporomandibular joints were evaluated radiographically for joint spaces evaluation and histologically for detection of changes in Joint architecture. The measured Joint spaces were subjected to statistical analysis. **Results:** Statistical analysis showed that comparing changes in measurements of Joint spaces between different groups revealed no significant differences. Evaluation of histological changes in Temporomandibular joint(TMJ) revealed that in group II mild inflammatory and degenerative changes were detected. All these changes were within the adaptive capacity of the joints as; all these changes were mostly reversible in group III (6 months post consolidation). **Conclusion:** The results of the present study showed that mandibular unilateral lengthening by distraction osteogenesis at a rate of 2 mm per day may lead to initial mild inflammatory and degenerative changes in TMJ. However, all condyles showed adaptive and remodeling signs within 6 month period post consolidation.

[Elsagaly A.H., Abd Elmonem K., Metwalli S.A., and Elkasaby M. **Influence of rapid unilateral mandibular lengthening by distraction osteogenesis on the temporomandibular Joint (An experimental study).** *J Am Sci* 2013;9(12s):1-10]. (ISSN: 1545-1003). <http://www.jofamericanscience.org>. 1

Key words: Osteogenesis, Condyles, Mandibular unilateral lengthening

1.Introduction

Reconstruction of bony defects resulting from trauma, infection, tumors, and congenital defects is a challenging issue especially when there is a combination of bone and soft tissue deficiency. Standard procedures for reconstruction include autogenous bone grafts, vascularised osteomyocutaneous flaps, free vascularised bone grafts, allogenic bone grafts, and heterogenic bone grafts. These procedures were reported to have several problems such as complicated surgery, infection, loss of graft, and donor site morbidity (Marx,1993; Perrott et al., 1993; Quereshy and Powers,2000;Rubio-Bueno et al., 2001; Mommaerts and Nagy,2002).Distraction osteogenesis is the technique of gradual bone lengthening that allows the body's natural healing mechanisms to generate new bone for reconstruction and lengthening of bony defects. It has the advantage of augmenting both bony and soft tissues deficiencies simultaneously (Papageorge and Apostolidis,1999; Gaggi et al., 1999). Distraction osteogenesis is safely applied for regenerating new bone tissue where large

amount of bone is required and alleviates the need for grafting with consequently lower risk of all reported bone grafting procedures related complications (Swennen et al., 2002).

However, there are still some limitations regarding wide application of distraction osteogenesis for reconstruction of maxillofacial defects. These limitations include complexity and cost of distraction device, lengthy treatment protocols, and possible temporomandibular joint (TMJ) changes (Troulis et al., 2000; Troulis,2001;Thurmuller et al.,2002).

It was reported that the recommended, most physiologic distraction rate is one millimeter per day to produce bony regenerate of superior biomechanical properties (Troulis et al.,2000; Al Ruhaimi,2001).

Several trials have been reported in literature to overcome the lengthy protocols for distraction osteogenesis and minimize treatment time through alteration in rate, rhythm, consolidation time, with the simultaneous application of biological tissue healing enhancers (Farhadieh et al.,2000; Mengchum et al.,2006).

As regards to the effect of distraction technique on the TMJ. Distraction procedure leads to bony separation by force transduction through both mandibular segments. Mechanical loading on osteotomized mandible will have an effect on the TMJ leading to possible structural alterations and or positional changes. This could result in an unfavourable clinical outcome on TMJ following distraction procedure (Stelnicki et al., 2001; Elgazzar et al., 2008).

Although mandibular lengthening has become a common technique, changes in the TMJ have not been well documented. In particular the correlation between TMJ changes and the change in distraction rate aiming to minimize the overall treatment time is not clearly illustrated (McCormick et al., 1995; Karaharju-Suvanto et al., 1996; Zou et al., 2001).

It was reported in literature that a distraction rate of 0.5 – 1 mm per day was acceptable and safe for TMJ, with no observed degenerative TMJ changes in both distraction and nondistraction sides. While faster rates resulting in hyperphysiologic loads on TMJ might lead to degenerative or even early arthritic changes in the condyle (Kruse-Losler et al., 2001; Kim et al., 2003).

This study was conducted to evaluate the effect of a considerably rapid distraction rate of 2mm per day on the TMJ in cases of unilateral mandibular lengthening.

2. Materials and Methods:

2.1. Materials:

2.1. Samples:

This study was conducted on a total of 18 young healthy adult male goats weighing 20-25 kg. Animals were divided into 3 groups; each group constitutes six goats:

Group I served as a control group

Group II, III are the study groups.

All animals in group II, III were subjected to right side unilateral mandibular lengthening by distraction osteogenesis at a rate of 2mm per day for 5 days with a total distraction zone of 10 mm. A consolidation phase of one month was carried out in both groups.

In group II, animal sacrifice was performed one month post consolidation, while in group III, animal sacrifice was performed six months post consolidation.

2.2. Methods:

Surgical protocol

All animals were pre-medicated half an hour pre-operatively using Atropine sulphate 0.25mg/kg body weight (Atropine sulphate inj., Memphis Co. Cairo), and 1 gm Amoxicillin (E-Mox 1gm vial, Amoxycillin, Egyptian Int. Pharmaceutical Industries EIPI, Co.A.R) which were injected intramuscularly.

Animals were submitted to general anesthesia by intravenous injection into a cannulated ear vein of Sodium thiopental 35mg/kg body weight (Thiopental sodium vial 500mg Egypt, Int.Pharma. Indust. Co., EIPI, Co.A.R). Half of the dose was given initially for induction with subsequent administration of small doses through the surgery for maintenance of general anesthesia.

After shaving the skin over the right side and inferior border of the mandible and sterilizing using Iodine 10 % (Iodine -The Nile Co. for Pharma. and chemical industries-Cairo. A.R.E), a skin incision of about 3-4 cm length was performed along the inferior mandibular border. Blunt dissection was carried out till reaching the periosteum, which was sharply incised along the inferior border. Careful flap reflection was then performed caring to preserve the mental neurovascular bundle.

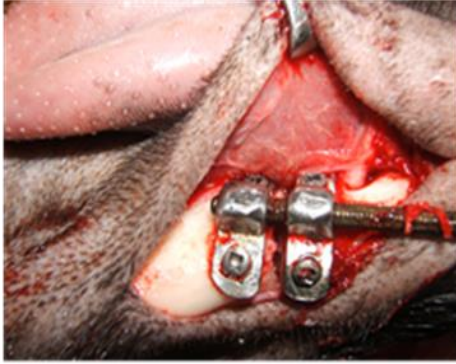After bony exposure, a custom made distractor, formed of 2 miniplates and threaded rod, was adapted to the buccal cortical plate in the edentulous premolar gap which is devoid of teeth.

The proposed sites for screws were drilled on each side of the planned osteotomy site using a 1.5 mm drill.

Initial corticotomy was then performed using surgical fissure bur, with caution to preserve the vascular bundle, under copious irrigation with normal saline solution (Normal saline –Sodium chloride 0.2% El Nasr Pharmaceutical Chemical Co. Egypt). The distractor was then fixed in place using the pre-corticotomy prepared screw holes using four 2.0 mm screws of 9 mm length. The osteotomy was then completed through the use of surgical bur and finally by using spatula chisels till complete separation of the bony segments as confirmed by device activation followed by complete deactivation and achieving maximum contact between bony segments (Fig. 1).

The wound was then thoroughly irrigated and suturing was performed using 3-0 black silk.

All animals received 1 gm. Amoxicillin every 12 hours for 5 days postoperatively and ketolgen 25mg (Ketolgen 100 mg ampoule, Amoun, Co) twice daily for 2 days.



Fig(1): The distractor fixed in place.

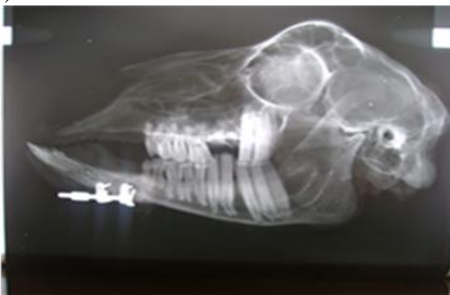2.2.1. Distraction regimen

After a 5 days latency period, distractor activation started at a rate of 2 mm per day, divided into 1mm in the morning and 1 mm in the evening. This regimen was carried out for 5 days with a total distraction zone of 10mm. This was followed by a consolidation phase of 4 weeks.

Animal sacrifice was performed one month post consolidation phase in group II and 6 month post consolidation in group III.

2.2.2. Radiographic evaluation

Post sacrifice Contact standardized lateral radiographs were taken to the dissected hemiskulls to examine the right ipsilateral (distracted) and left contralateral (non-distracted) T.M.Js. using an enclosed X-ray unit (Panorama Yoshida, Tube Toshiba, Japan). The radiographic films were scanned by Epson scanner, (Epson perfection 1250, Japan), (Fig.2).



Fig(2): lateral contact X ray of hemiskull illustrating distraction site and TMJ.

Geometrical analysis of the anterior (A), posterior (P), and superior (S) joint spaces were done as follows:

The **anterior joint space was the distance between two reference lines. These lines are L3 and L4:

L3: Is a tangent line passes through the most convex point of the slope of articular eminence.

L4: Is a tangent line passes through the most convex point of the anterior slope of the condylar head. (Fig.3)

The **posterior joint space was the distance between two reference lines. These lines are L5 and L6.

L5: Is a tangent line passes through the most convex point of the posterior slope of the condylar head.

L6: Is a tangent line passes through the most convex point of the posterior slope of the glenoid fossa. (Fig. 3)

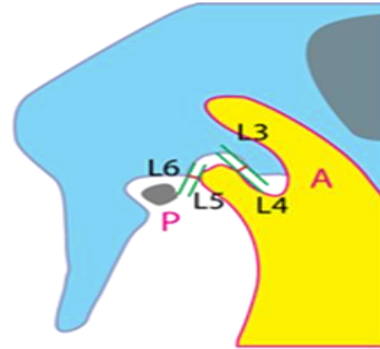
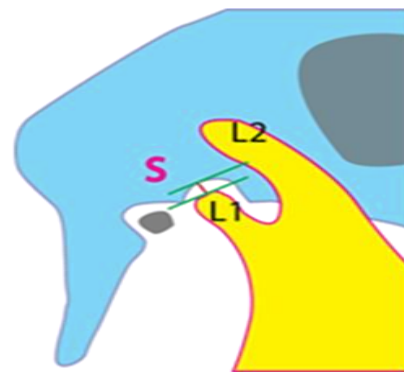


Fig (3): Schematic drawing for anterior and posterior joint spaces measurements (A, P).

The **superior joint** space was the distance between two reference lines. These lines are L1 and L2:

L1: Is a line connecting the articular eminence and the post glenoid spine (squamo-tympanic fissure) and touching the most superior convex point of condylar head.

L2: Is a tangent line drawn parallel to L1 and passing through the deepest point of the glenoid fossa. (Fig. 4).



Fig(4): Schematic drawing for superior joint space measurement (S).

The radiographic films were scanned by Epson scanner (Epson perfection 1250, Japan). Measurements of joint scores will be performed on the scanned X-ray images. All

measurements were recorded, tabulated and subjected to statistical analysis (Figs.5-7).




Fig (5): A is the anterior joint space as measured on scanned xray image.

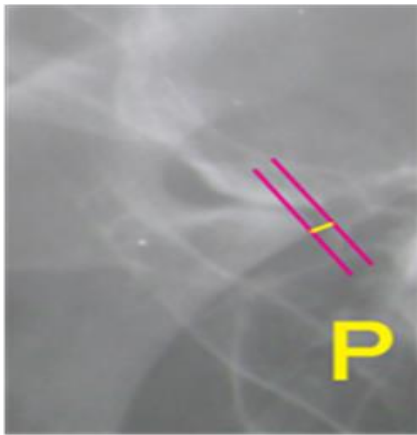


Fig (6): P is the posterior joint space as measured on scanned x ray image.




Fig (7): S is the superior joint space as measured on scanned x ray image.

Paired t- tests were utilized to examine and compare the difference in joints spaces measurements between the right (ipsilateral) condyle with the left (contra-lateral) condyle in each group.

Whereas, analysis of variance, one way ANOVA test was used to compare the differences in right (ipsilateral) TMJ spaces measurements between all groups. Also this test was used to compare the left (contralateral) TMJ measurements between all groups.

2.2.3.Histopathological examination

TMJs areas were harvested and preserved in 10% neutral buffered formalin solution for 1 week.

Decalcification of the specimens was performed using 20% Ethylene diamine tetra acetic acid (EDTA) changed every 2 days for 4 days. After decalcification, midsagittal sections of the condyle and temporal bone were prepared. The tissue sections were stained with haematoxylin and eosin (H&E) stain and examined under light microscope (B x 60, Olympus, Japan.) for standard histological description and photograph was captured by video camera (Camedia C5060, Olympus Japan).

3.Results

All animals tolerated the surgery very well and also tolerated the active distraction procedure. All experimental group II and III animals showed an obvious asymmetric protrusion and deviation of the mandible in the form of lateral cross bite and shifting of the midline toward the non-distorted left side.

3.1.Radiographic Findings:

Examination of the lateral contact radiographs in group I (control), group II (one month), and group III (6 months) revealed no growth changes in the general morphology and architecture of the condyle and the glenoid fossa in comparison to the control group. There was no erosions, no thickening of the articular surfaces or abnormal deformity of the joints.

Geometric reference measurements in the form of anterior joint space (A), posterior joint space (P), and superior joint space (S) were measured, tabulated and analyzed.

Group I (control)

The mean anterior joint space (A) of the right side was $0.7433 \text{ mm} \pm 0.38004 \text{ mm}$ while the mean of the left side was $0.7133 \text{ mm} \pm 0.31374 \text{ mm}$.

The mean posterior joint space (P) of the right side was $0.3933 \text{ mm} \pm 0.12503 \text{ mm}$ while the mean of the left side was $0.4267 \text{ mm} \pm 0.6110 \text{ mm}$.

The mean superior joint space (S) of the right side was $3.1933 \text{ mm} \pm 0.71459 \text{ mm}$ while the mean of the left side was $2.3000 \text{ mm} \pm 1.01975 \text{ mm}$.

Group II

The mean anterior joint space (A) of the right side was 0.7633 mm ± 0.33501 mm while the mean of the left side was 0.3167 mm± 0.19348 mm.

The mean posterior joint space (P) of the right side was 0.3633 mm ± 0.03512 mm while the mean of the left side was 0.3233 mm ±0.07234..

The mean superior joint space (S) of the right side was 2.3200 mm ± 0.26211 mm while the mean of the left side was 2.5400 mm ± 0.66551mm.

Group III:

The mean anterior joint space (A) of the right side was 0.4117 mm ± 0.29590 mm while the mean of the left side was 0.6783 mm ± 0.46536 mm.

The mean posterior joint space (P) of the right side was 0.4925 mm ± 0.18666 mm while the mean of the left side was 0.2425 mm ± 0.10305 mm.

The mean superior joint space (S) of the right side was 2.6450 mm ± 0.90060 mm while the mean of the left side was 3.1050 mm ± 0.93716.

In group I (control group), there was no difference in the anterior, posterior and superior joint spaces measurements between the right and left joints. Statistical analysis using t-test to compare the different joint spaces between left and right joints showed that there was no significant difference in the anterior, posterior and superior joint spaces in group I (Figs. 8 - 10) (table1).

Analyzing measurements of group II (one month) showed slight difference with some increase in the right anterior joint space and some decrease in the right superior joint space

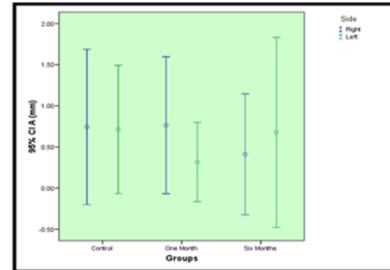


Fig (8): Error bars showing the mean and the standard error of the anterior joint space (A) measurements (mm) in all groups

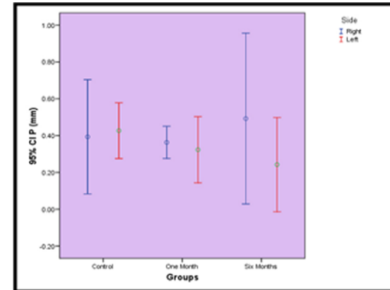


Fig (9): Error bars showing the mean and the standard error of the posterior joint space (P) measurements (mm) in all groups.

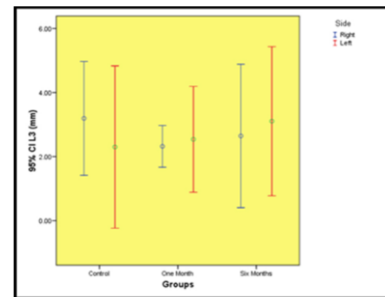


Fig (10): Error bars showing the mean and the standard error of the superior joint space (S) measurements (mm) in all groups.

Table (1): t-test-comparing between the right and left TMJ spaces in group I.

Group Statistics					
	Side	N	Mean	Std. Deviation	Std. Error Mean
S(mm)	Right	6	3.1933	0.71459	0.41257
	Left	6	2.3000	1.01975	0.58876
A(mm)	Right	6	0.7433	0.38004	0.21942
	Left	6	0.7133	0.31374	0.18114
P (mm)	Right	6	0.3933	0.12503	0.07219
	Left	6	0.4267	0.06110	0.03528

Statistical analysis using t-test comparing between the right and left TMJ spaces in group II showed that there was no significant difference in the anterior, posterior and superior joint spaces in group II (table2) (Figs. 8 - 10)..

Analyzing measurements of group III revealed that there was no difference in the superior joint space between the right and left joints. The anterior joint space showed slight increase in the left joint,

while the posterior joint space showed slight increase in the right side more than on the left side. Statistical analysis using t-test comparing between the right and left TMJ spaces in group III showed that there was no significant difference in the anterior, posterior and superior joint spaces in group III (table3) (Figs. 8- 10).

Table (2): t-Test – comparing between the right and left TMJ spaces in Group II.

Group Statistics					
	Side	N	Mean	Std. Deviation	Std. Error Mean
<i>S (mm)</i>	<i>Right</i>	6	2.3200	0.26211	0.15133
	<i>Left</i>	6	2.5400	0.66551	0.38423
<i>A (mm)</i>	<i>Right</i>	6	0.7633	0.33501	0.19342
	<i>Left</i>	6	0.3167	0.19348	0.11170
<i>P (mm)</i>	<i>Right</i>	6	0.3633	0.03512	0.02028
	<i>Left</i>	6	0.3233	0.07234	0.04177

Table (3): t-Test – comparing between the right and left TMJ spaces in Group III.

Group Statistics					
	Side	N	Mean	Std. Deviation	Std. Error Mean
<i>S (mm)</i>	<i>Right</i>	6	2.6450	.90060	.51996
	<i>Left</i>	6	3.1050	.93716	.54107
<i>A (mm)</i>	<i>Right</i>	6	.4117	.29590	.17084
	<i>Left</i>	6	.6783	.46536	.26867
<i>P (mm)</i>	<i>Right</i>	6	.4925	.18666	.10777
	<i>Left</i>	6	.2425	.10305	.05949

Moreover, statistical analysis using ANOVA test to compare the anterior, posterior and superior joint spaces between the right side of the TMJ in all groups and the left side in all groups showed that there was no significant difference in the joint spaces between groups I, II, III (tables 4,5). Multiple

comparisons between all groups revealed no significant difference in the anterior, posterior and superior joint spaces of both right and left sides when comparing each group to the other two groups (tables 4, 5).

Table (4): ANOVA test comparing between joint spaces in the right side of all groups.

		Sum of Squares	df	Mean Square	F	Sig.
<i>S (mm)</i>	<i>Between Groups</i>	1.169	2	0.585	1.261	0.349
	<i>Within Groups</i>	2.781	6	0.463		
	<i>Total</i>	3.950	8			
<i>A (mm)</i>	<i>Between Groups</i>	0.234	2	0.117	1.020	0.416
	<i>Within Groups</i>	0.688	6	0.115		
	<i>Total</i>	0.923	8			
<i>P (mm)</i>	<i>Between Groups</i>	0.027	2	0.014	0.795	0.494
	<i>Within Groups</i>	0.103	6	0.017		
	<i>Total</i>	0.131	8			

Table (5): ANOVA test comparing between joint spaces in the left side of all groups.

		Sum of Squares	df	Mean Square	F	Sig.
<i>S (mm)</i>	<i>Between Groups</i>	1.025	2	0.512	0.651	0.555
	<i>Within Groups</i>	4.722	6	0.787		
	<i>Total</i>	5.747	8			
<i>A (mm)</i>	<i>Between Groups</i>	0.289	2	0.145	1.232	0.356
	<i>Within Groups</i>	0.705	6	0.117		
	<i>Total</i>	0.994	8			
<i>P (mm)</i>	<i>Between Groups</i>	0.051	2	0.026	3.916	0.082
	<i>Within Groups</i>	0.039	6	0.007		
	<i>Total</i>	0.090	8			

3.2. Histological Findings

Group I (Control Group):

The examined TMJs were found to consist of the glenoid fossa of the temporal bone, the articular disc, and the condyle of the mandible. The condyle was covered by fibrous connective tissue with many fibroblasts on the articular surface, and this formed a fibrous articular zone. The Proliferative zone contained random prechondroblasts and chondroblasts with oval nuclei. The upper and

lower hypertrophic cartilaginous zones contained calcified cartilaginous matrix. Endochondral ossification was present in the subchondral bone with many osteoblasts and marrow spaces (Fig. 11).

Group II:

Some areas showed reduction in thickness of fibrous layer and the thickness of the cartilaginous layer. Some areas of osteoclastic activity and bone resorption were detected in the subchondral bone indicating starting inflammatory and degenerative changes in the ipsilateral side. While some areas showed proliferation of the cartilaginous zone of the condylar head with randomly oriented chondroblasts and chondrocytes in the Proliferative zone of the ipsilateral side than on the contralateral side. Some endochondral bone formation was seen in the calcified cartilaginous matrix of ipsilateral side and smaller amounts were also detected in the contralateral side (Fig. 12).

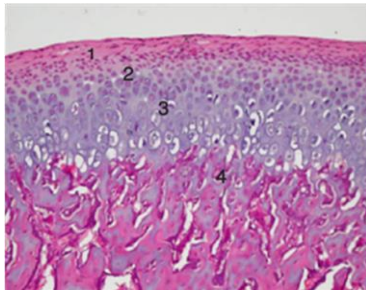


Fig (11): Condylar layers in control group consisting of (1) fibrous layer, (2) proliferative, (3) hypertrophic cartilaginous zones, and (4) subchondral bone with marrow spaces (haematoxylin and eosin, original magnification $\times 100$)

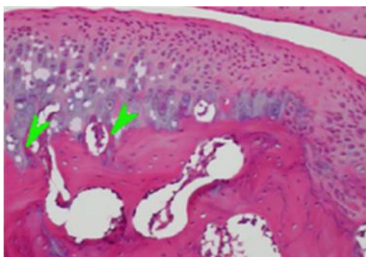


Fig (12): microphotograph of the condyle in group II showing some areas of thinning of cartilaginous zones with less endochondral ossification (arrowheads) (haematoxylin and eosin, original magnification $\times 100$).

Group III:

The ipsilateral side showed more proliferation and increase in thickness of both the fibrous layer and the cartilaginous zone of the condylar head. There was also considerable proliferation of cells in the proliferative zone. Both proliferative and hypertrophic zones contained more cells with increased number of hypertrophic chondrocytes. On both sides there was some endochondral ossification, but more active bone-forming osteoblasts were noted on the ipsilateral side than on the opposite side. Minimum osteoclastic activity was also detected in the subchondral bone (Fig 13).

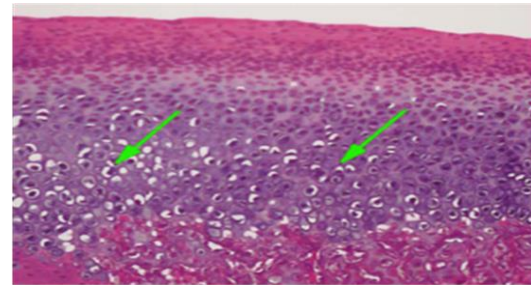


Fig (13): Microphotograph of the condyle in group III showing many hypertrophic chondrocytes in the hypertrophic cartilaginous zone and endochondral ossification was also observed in the subchondral bone (arrows). (haematoxylin and eosin, original magnification $\times 100$).

4. Discussion

Distraction osteogenesis of the mandible is considered one of the most successful treatment modalities for treating major combined skeletal and soft tissue defects in maxillofacial region (Rachmiel et al., 1995; Sadakah et al., 2006; Elgazzar et al., 2008).

Distraction rate was considered to be one of the most important clinical parameters that affect treatment outcome. It was reported that a rate of 0.5 – 1 mm mandibular lengthening per day was the most physiologic rate resulting in best bone regeneration and soft tissue healing (Cortesse et al., 1996; Al Ruhaimi, 2001).

On the other hand, the length of treatment period was considered a problem that limits the wide application of distraction osteogenesis in maxillofacial reconstruction. Shortening of treatment time could make such treatment protocol more applicable and convenient to the patient. Minimizing time protocol for distraction osteogenesis treatment modality can be achieved through the acceleration of distraction rate, while enhancing the quality and quantity of bone formation through the application of different tissue healing enhancers (Troulis et al., 2000; CHO et al., 2003; Mengchum et al., 2006).

Distraction osteogenesis procedure was reported to induce effects on different oral and maxillofacial region tissues including bone, muscles, nerves, and TMJ, Sin-Young Ahn and Su-Gwan Kim(2011).

One of the reported shortcomings of mandibular lengthening by distraction osteogenesis is TMJ impairment. It was reported that during mandibular distraction, although the body of the mandible receives a direct stretch, the condyle, especially on the operated side, undergoes an indirect compression against the articular fossa creating stress on the condylar surface(Zou et al.,2001;Sin-Young Ahn and Su-Gwan Kim,2011; katamish et al.,2012).

Distraction of the mandible at a rate of 1 mm per day was found to be well tolerated by the condylar heads in the studied animals(McCormick et al.,1995; McCormick et al.,1995; Mihmanli et al.,2012).Harper et al.,(1997)reported TMJ changes in the form of thickening of fibrous and cartilaginous zones which returns to baseline subsequently.

Kruse-Losler et al., (2001) reported that a positive correlation was found between the degree of mechanical loading and the development of degenerative alterations in the cartilage. This was reflected in reduction of all cartilaginous layers in animals distracted at hyper physiologic strain magnitudes. It was reported that accelerating distraction rate led to degenerative or inflammatory alterations of the condyle and cartilage in white rats, Liu et al., (2003).

Thurmuller et al.,(2002)reported that a distraction rate of 4mm per day resulted in degenerative or inflammatory changes in the condyle; however such changes were not evident when the distraction rate was 1 mm per day.

There have been a considerable amount of researches focusing on understanding the adaptive changes of TMJ in response to changes in biomechanical and biophysical environment. It was reported that long term follow up post distraction is recommended to find out the adaptive changes in TMJ and its relation to the extent of mandibular distraction procedures (McNamara et al., 1982; Copray et al., 1985;Thurmuller et al., 2002).

Mihmanli et al.,(2012) reported that changes in TMJ following distraction osteogenesis in rabbits were reversible in a time of 6 month after distraction owing to the adaptation process of the condyle. It was also reported that a distraction rate of 3mm per day resulted in degenerative changes in rabbits in the 1st and 2nd weeks post distraction. However, most of the rabbits showed adaptive and remodeling signs in the following 3rd and 4th weeks Elgazzaret al.,(2008).

In the present study, we used a distraction rate of 2 mm per day which was reported to be considered a

hyper-physiological rapid rate that might induce degenerative changes in TMJ, Zou et al.,(2001).

A considerably long follow up time for 6 month post distraction was carried out in group III to evaluate the adaptive capacity of the TMJ in response to mechanical loading of the joint through the distraction procedure. Moreover, a relatively short follow up time for 1 month was carried out in group II.

Our radiographic findings showed no significant differences in joints morphology between different groups. Geometric analysis of Joint spaces (A, P, S) showed some decrease in superior joint space of the ipsilateral joint in group II which may be attributed to the indirectly applied pressure on the condyle. However, statistical analysis revealed no significant differences when comparing ipsilateral and contralateral joints in each group or when comparing the joints between different groups.

Our histopathological findings suggested that a rate of 2 mms per day for distraction result in initial inflammatory and degenerative changes in TMJ in the form of partial loss of thickness in condylar layers and some osteoclastic activity and bone resorption in the sub-chondral bone as shown in group II, 1 month post distraction.

However, these changes were mostly reversible and within the adaptive power of the condyles as demonstrated in group III, 6 month post distraction,in the form of hypertrophy in condylar layers and areas of new subchondreal osteoblastic activity.

These results were in agreement with the previously mentioned studies as regard the long-term adaptive process of the TMJ following mandibular distraction osteogenesis.

In conclusion, our results revealed that a 2 mm per day distraction rate for mandibular lengthening is within the adaptive capacity of the TMJ, allowing gradual reversal of any initial inflammatory or degenerative changes as time elapse after the distraction procedure.

References

- 1.Al Ruhaimi KA. Comparison of different distraction rates in the mandible: an experimental investigation. *Int J Oral Maxillofac Surg*, 30:220,2001.
- 2.CHO BC, Moon JH, Chung HY, Park JW, Kweon IC, and Kim IS. The regenerative effect of growth hormone on consolidation in mandibular distraction osteogenesis of a dog model.*J Craniofac Surg*, 14:417, 2003.
- 3.Copray JC, Jansen HW, Duterloo HS. Effects of compressive forces on proliferation and matrix synthesis in mandibular condylar cartilage of the rat in vitro. *Arch Oral Biol*, 30:299, 1985.

4. Cortesse CLA, Zupi A, and Tajana G. Mandibular lengthening by external distraction: An experimental study in rabbit. *J Oral Maxillofac Surg*, 52:1179, 1994.
5. Elgazzar RF, El-Bialy TH, and Megahed E. Effect of mandibular distraction on the condylar cartilage: An experimental study on rabbits. *The Open Dentistry Journal*, 2:103, 2008
6. Farhadieh RD, Gianoutsos MP, Dickinson R, and Walsh WR. Effect of distraction rate on biomechanical, mineralization, and histologic properties of an ovine mandible model. *Plast Reconstr Surg*, 105:889, 2000.
7. Gaggi A, Schultes G, and Karcher H. Distraction implants- a new possibility for augmentative treatment of the edentulous atrophic mandible: case report. *Br.J.Oral Maxillofac Surg*, 51:481, 1999
8. Harper RP, Bell WH, Hinton RJ, Browne R, Cherkashin AM, Samchukov ML. Reactive changes in the temporomandibular joint after mandibular midline osteodistraction. *Br J Oral Maxillofac Surg*, 35:20, 1997.
9. Karaharju-Suvanto T, Peltonen J, Laitinen O, Kahri O. The effect of gradual distraction of the mandible on the sheep temporomandibular joint. *Int J Oral Maxillofac Surg*, 25:152, 1996.
10. Katamish A.M., Elmonem K.A., and Metwalli A.A.S. Magnetic resonance imaging of the temporomandibular joint after mandibular osteodistraction versus mandibular advancement osteotomy. *Egyptian Dental Journal*, 58:553, January, 2012.
11. Kim SG, Park JC, Kang DW, *et al.* Correlation of immunohistochemical characteristics of the craniomandibular joint with the degree of mandibular lengthening in rabbits. *J Oral Maxillofac Surg*, 61:1189, 2003.
12. Kruse-Losler B, Meyer U, Floren C, Joos U. Influence of distraction rates on the temporomandibular joint position and cartilage morphology in a rabbit model of mandibular lengthening. *J Oral Maxillofac Surg*, 59:1452, 2001.
13. Liu ZJ, King GJ, Herring SW. Alterations of morphology and microdensity in the condyle after mandibular osteodistraction in the rat. *J Oral Maxillofac Surg*, 61:918, 2003.
14. Marx RE: Mandibular reconstruction. *J Oral Maxillofac Surg*, 51:466, 1993.
15. Mengchun QI, Jing HU, Shujuan ZOU, Haixiao ZHOU, and Lichi Han. Mandibular distraction osteogenesis enhanced by bone marrow mesenchymal stem cells in rats. *J Craniomaxillofac Surg*, 34:283, 2006.
16. McCormick SU, McCarthy JG, Grayson BH, Staffenberg D, McCormick SA. Effect of mandibular distraction on the temporomandibular joint: part 1: Canine study. *J Craniofac Surg*, 6:358, 1995.
17. McCormick SU, Grayson BH, McCarthy JG, Staffenberg D. Effect of mandibular distraction on the temporomandibular joint: Part II. Clinical study. *J Craniofac Surg*, 6:364, 1995.
18. McNamara JA, Hinton RJ and Hoffman DL. Histological analysis of temporomandibular joint adaptation to protrusive function in young adult rhesus monkeys (*Macaca mulatta*). *Am J Orthod*, 82: 288, 1982.
19. Mihmanli A, Dolanmaz D, Tuz H, Pampu A, and Donmez HH. Histomorphometric examination of long-term changes in temporomandibular joints after mandibular lengthening by distraction osteogenesis in rabbits. *Oral Surg Oral Med Oral Pathol Oral Radiol*, 113:600, 2012.
20. Mommaerts MY, Nagy K. Is early osteodistraction a solution for the ascending ramus compartment in hemifacial microsomia? A literature study. *J Craniomaxillofac Surg*, 30:201, 2002.
21. Papageorge MB and Apostolidis C. Simultaneous mandibular distraction and arthroplasty in a patient with temporomandibular joint ankylosis and mandibular hypoplasia. *J Oral Maxillofac Surg*, 57: 328, 1999.
22. Perrott DH, Berger R, Vargervik K, and Kaban LB. Use of skeletal distraction device to widen the mandible: A case report. *J Oral Maxillofac Surg*, 51: 435, 1993.
23. Quereshy FA and Powers MP. Reconstruction of the maxillofacial cancer patient. In, Powers MP, Barber HD: *Reconstructive and Implant Surgery, Fonseca Oral and Maxillofacial Surgery*. 1st ed, W.B. Saunders Company. Vol 7, Chapter 15, pp 366, 2000.
24. Rachmiel JM, Levy M, Laufer D. Lengthening of the mandible by distraction osteogenesis: Report of cases. *J Oral Maxillofac Surg*, 53:838, 1995.
25. Rubio-Bueno P, Villa E, Carreno A, *etal.* Intraoral mandibular distraction osteogenesis: special attention to treatment planning. *Craniomaxillofac Surg*, 29:254, 2001
26. Sadakah AA, Elgazzar RF, Abdelhady AI. Intraoral distraction osteogenesis for the correction of facial deformities following temporomandibular joint ankylosis: a modified technique. *Int J Oral Maxillofac Surg*, 35:399, 2006.
27. Sin-Young Ahn, Su-Gwan Kim. Condylar cartilaginous changes after mandibular distraction osteogenesis in rabbits. *Oral Surg Oral Med Oral Pathol Oral Radiol Endod*, 112:416, 2011.
28. Stelnicki EJ, Stuck-McCormick SU, Rowe N, McCarthy JG. Remodeling of the temporomandibular joint following mandibular

- distraction osteogenesis in the transverse dimension. *Plast Reconstr Surg*, 107:647, 2001.
29. Swennen G, Dempf R, and Schliephake H. Craniofacial distraction osteogenesis: a review of the literature. Part II: Experimental studies. *Int J Oral Maxillofac Surg*, 31:123, 2002.
30. Thurmuller P, Troulis MJ, and Rosenberg A and Kaban LB. Changes in the condyle and disc in response to distraction osteogenesis of the minipig mandible. *J Oral Maxillofac Surg*, 60: 1327, 2002.
31. Troulis MJ, Glowacki J, Perrott DH, and Kaban LB. Effect of latency and rate on bone formation in a procine mandibular distraction model. *J Oral Maxillofac Surg*, 58:507, 2000.
32. Troulis MJ. Influence of distraction rates on the temporomandibular joint position and cartilage morphology in a rabbit model of mandibular lengthening. *J Oral Maxillofac Surg*, 59: 1460, 2001.
33. Zou S, Hu J, Wang D, Li J, Tang Z. Changes in the temporomandibular joint after mandibular lengthening with different rates of distraction. *Int J Adult Orthodon Orthognath Surg*, 16:221, 2001.

11/12/2013