

Expression of MyoD in the DMBA-Treated Hamster Pouches Following Thymoquinone Injection.

Haethm M. Algharyni*, Wafaa HH. El-Hossary**, Ahmed MM. Korraah** and Magda MA Hassan***

* Dentist at Ministry of Health, Lybia.

** Lecturers of Oral Pathology, Faculty of Dentistry, Suez Canal University.

*** Professor of Oral Pathology, Faculty of Dentistry, Suez Canal University.

Corresponding Author: Thymoquinone Injection.

Abstract: Aim of study: To follow the sequential expression of Myo D in the DMBA-painted hamster buccal pouches, following early thymoquinone intraperitoneal injections.

Material and Methods: Eighty male golden Syrian hamsters were divided into 3 groups: Group I: (10 animals) served as negative control, 5 hamsters were euthanized before starting the experiment, and the other 5 at end of the experiment. Group II: (10 animals) positive control (the left buccal pouches were painted with the carcinogen 0.5% DMBA 3/wk / 6 weeks), five hamsters were euthanized at second day of last painting and 5 hamsters 2 weeks later. Group III: (60 animals) thymoquinone (TQ)-treated group: were painted with DMBA, as in group II, then subdivided into two equal subgroups: IIIa: were given one i.p. injection of TQ (0.1 mg/kg). IIIb: were given two i.p. injections of TQ every other day. Blood samples were withdrawn for evaluation of TNF- α level before euthanization. Five animals, from the TQ-treated groups, were euthanized at 4, 24, 48 hrs, one week and two weeks after the last injection. All buccal pouches were surgically excised, fixed, and processed for H&E, and Myo D immunohistochemical (IHC) stains.

Results: The results showed significant elevation of serum TNF- α after 6 weeks of DMBA as compared to the negative control group, and higher significant elevation following one i.p. injection of TQ as compared to all groups. Two i.p. injections of TQ resulted in significant elevation from the second day, then declined to near the DMBA-only group level. Clinically, after two weeks of 2 TQ i.p injections, elongation of the DMBA-painted pouches, was achieved to near normal control pouches' length. IHC results showed Myo D expression was seen in perivascular mononuclear cells at areas of increasing muscle fibers' bulk, in the TQ- treated groups, from day 2 of injections. These cells could be mesenchymal stem cells or pericytes. It was also expressed in the lower two thirds of the hyperplastic epithelium, near the distal necrotic side, as well as the nuclei of the bulk mature muscle fibers, from the first to the second week of injections.

Conclusion: One and two ip injections with thymoquinone had promising effect to induce regeneration of the striated muscle layer independent on TNF- α or the muscle satellite cells, but due to other non-myogenic cell precursors.

Keywords: Experimental oral carcinogenesis (DMBA/ HBP model), TNF- α , Thymoquinone, Muscle regeneration, Myo D expression, Nonmyogenic precursor cells, Mesenchymal Stem Cells, Pericytes.

Date of Submission: 26-01-2019

Date of acceptance: 09-02-2019

I. Introduction

The hamster buccal pouch (HBP) / DMBA carcinogenesis model, is one of the most well characterized tumor-induction models, and functions as a paradigm for oral oncogenesis.⁽¹⁾ The early few DMBA paintings results in necrosis of the distal pouch, with reduction of its length from about 5-6 cm to about 2cm.^(2,3)

Thymoquinone (TQ) (2-methyl-5-isopropyl-1,4-benzoquinone), a monoterpene present in the seeds' oil of *Nigella sativa* (NS), has been thoroughly studied in vitro and in vivo. It has a wide range of therapeutic properties, including the potential anticancer effects.⁽⁴⁾

TNF is expressed mostly by monocytes and macrophages, T-cells, natural killer cells, neutrophils,⁽⁵⁾ and myoblasts.⁽⁶⁾

Serum TNF- α was found to be elevated in different chronic diseases as type 1 diabetes mellitus (T1DM),⁽⁷⁾ Behçet's disease,⁽⁸⁾ and some cancers.^(9,10) In vivo TNF can exist in membrane-bound as well as in soluble forms.⁽¹¹⁾ It was found to be expressed in damaged muscle fibers⁽¹²⁾ and performs two different roles in muscle regeneration, depending on its concentration.⁽⁶⁾ At high levels it suppresses myogenesis through

proteolysis of Myo-D, or the NF- κ B-TNF pathway. (13) On the other hand it induces myogenesis at lower concentration. (6)

In that HBP / DMBA model, when TQ was injected at the same time with DMA-painting, had resulted in elongation of the pouches with negative expression of TNF- α in both the epithelial cells and expelled inflammatory cells. (2)

Classically, muscle regeneration following its damage, is mediated by myogenic precursor cells (satellite cells). The process of satellite cell activation and differentiation is controlled by a family of muscle-specific transcription factors called MRFs, where PAX-7 and Myo-D are very important. (5)

Once activated, satellite cell progeny can follow one of two fates depending on MyoD activity. Satellite cells may downregulate MyoD and self-renew. Alternatively, they maintain MyoD expression but downregulate Pax7 and activate myogenin expression, thus committing to differentiation. (14)

Other cells leading to myogenesis include the bone marrow (BM)-derived stem cells. They can differentiate into muscle cells in vitro, and contribute to muscle regeneration in vivo. (15) These cells could be the pericytes that are activated during local injury, after being released from their vascular wall. Furthermore, the fibro/adipogenic progenitors (FAPs) are capable of giving rise to fibroblasts or adipocytes, and play a supportive role in the myogenic differentiation. (16)

II. Material and Methods

The current study was carried out on eighty male golden Syrian hamsters (*Mesocricetus auratus*), weighting 100-120 grams. They were purchased from the Holding Company for Biological Products and Vaccines (VACSERA), Cairo, Egypt. The study was held at the Animal House, Faculty of Dentistry, Suez Canal University. They were housed 5 per cage, with controlled temperature, and given water and food ad libitum.

Chemicals: *Carcinogen:* The chemical carcinogen, was 0.5% solution of 7,12-dimethylbenza-(a)-anthracene (DMBA) dissolved in heavy mineral oil, both from Sigma-Aldrich Co., Saint Louis, MO, USA. The carcinogen was topically applied to the left hamster buccal pouches (HBP) using number 4 camel hair brush. *Thymoquinone (TQ):* (Sigma Aldrich Co., Saint Louis, MO, USA). Thymoquinone solution (0.1 ml/L) was prepared by dissolving 1gm of TQ in 100 ml propylene glycol, using a magnetic stirrer, to get a homogenous solution. *Myo D:* Clone 5.8A & MYD712. Item # RA0233-C.5. Scy Tek Laboratories. Utah 84323, USA. The used dilution was 1:50. The steps followed the manufacturer's instructions. Evaluation of IHC findings by counting cells with positive nuclei for Myo-D.

Animals' grouping and treatments:

Group I: Ten (10) hamsters served as the untreated, negative control.

Group II: Ten (10) hamsters served as the positive control, the left buccal pouches were painted with DMBA, 3/wk/ 6 weeks.

Group III: Sixty (60) hamsters served as the TQ- treated group. They were painted with DMBA as in group II, then were subdivided into two equal subgroups:

IIIa: were given one i.p injection with TQ (0.1 mg/kg body weight).

IIIb: were given two i.p injections with TQ (0.1 mg/kg body weight) every other day.

Euthanization of all animals by a heavy dose inhalation of ether in a tightly closed container. All pouches were surgically excised, fixed and processed for H&E, and Myo D IHC stain

TNF- α Blood samples (2 ml) were withdrawn from the orbital sinus through the mesial angle of the eye, for evaluation of TNF- α level from all hamsters before euthanization. TNF- α was evaluated by ELISA technique.

Statistical analysis: Results of serum TNF- α were statistically analyzed using One-Sample Test. The mean difference was set to be significant at $p \leq 0.05$ level, and highly significant at $p \leq 0.001$.

III. Results

Clinical observations: Group I: (negative control group): Animals of this group, appeared healthy, and active along the experiment. Both pouches appeared normal and measured about (5-6 cm) in length (Fig.1a). Same pouches' length was recorded for all right (un-painted) pouches of other groups.

Group II (positive control group): The animals were skinny, debilitated and inactive. The DMBA-painted left pouches were reduced in length to about 2 cm with distal necrotic end. (Fig.1b).

Group IIIa (One i.p TQ injection): The length of left pouches was between 2-2.5 cm from the 4th day of DMBA-painting. There were gradual increase of painted pouches length to about 4cm, after 2 weeks. (Fig.1c).

Group IIIb (two i.p TQ injections): Gradual increase of the painted pouches' length from the second day to end of the experiment (2 wks), from 2.5cm to about 5cm. Grossly, they appear normal in color and showed smooth shiny appearance. The distal necrosis was clinically absent. (Fig.1d).

Results of serum TNF-α : Tables (1,2), Fig.(2).

Statistical analysis of TNF-α between group II (positive control group) and group I (negative control group) showed elevated serum level in a statistically significant difference. Highly elevated TNF-α was reported in group IIIa (one i.p TQ injection) after 2 days of the injection up to end of the experiment (2 weeks). Following 2 i.p TQ injections TNF-α level was increased in a statistical significant level after 2 days to one week of the second injection, as compared to groups I and II. The level was decreasing at week 2 to near the positive control group that was not statistically significant.

Table 1: Showing comparison of statistical significance of serum TNF-α level between the TQ-treated groups, and both control groups:

	Groups								
	M&SD	Group IIIa (1 ip TQ. after 2days)	Group IIIa (1 ip TQ. after 4days)	Group IIIa (1 ip TQ. after 1week)	Group IIIa (1 ip TQ. after 2weeks)	Group IIIb (2 ip TQ. after 2days)	Group IIIb (2 ip TQ. after 4days)	Group IIIb (2 ip TQ. after 1week)	Group IIIb (2 ip TQ. after 2weeks)
Group I (Negative control)	1.6750 ± .40	.00*	.00*	.00*	.00*	.00*	.00*	.00*	.00*
Group II (Positive control)	36.95 ± 5.81	.00*	.00*	.00*	.00*	.004*	.015*	.024*	.631

* The significant difference was considered when the p value was ≤ 0.05.

M: Mean.

SD: Standard deviation

Table 2: Showing comparison of statistical significance of serum TNF-α level between group IIIa (One i.p TQ injection) and group IIIb (two ip TQ injections) at different time intervals:

	Groups				
	M&SD	Group IIIa (1 ip TQ. after 2days)	Group IIIa (1 ip TQ. after 4days)	Group IIIa (1 ip TQ. after 1week)	Group IIIa (1 ip TQ. after 2weeks)
Group IIIb (2 ip TQ. after 2days)	60.9 .081	.00*			
Group IIIb (2 ip TQ. after 4days)	51.7 .073		.00*		
Group IIIb (2 ip TQ. after 1week)	49.2 .060			.00*	
Group IIIb (2 ip TQ. after 2weeks)	38.5 5.06				.00*

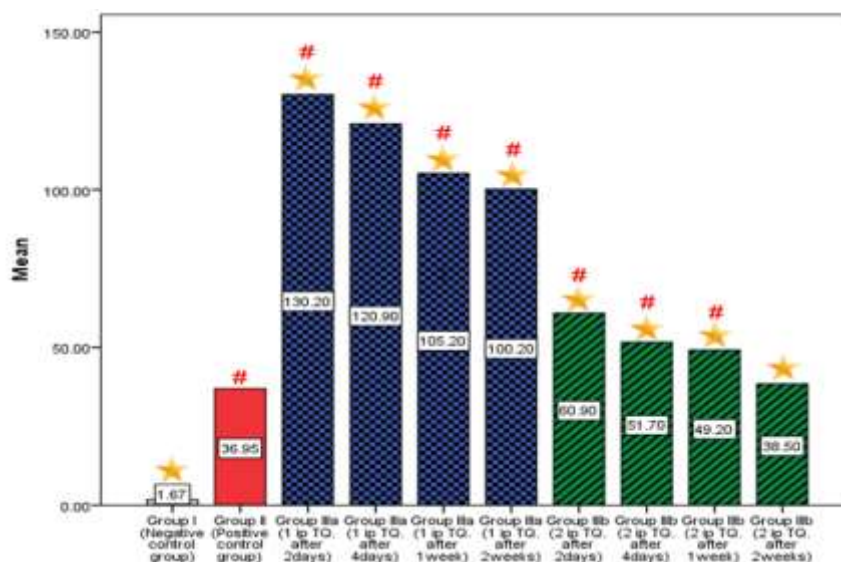


Figure (2): A graph showing statistical results of TNF-α in all groups

* The significant difference was considered when the p value ≤ 0.05.

#: Significant to group I (negative control group).

★: Significant to group II (positive control group).

Histopathological and IHC results:

For the negative control group (G I), both pouches and right pouches of other groups showed normal appearing HBP mucosa. The IHC results revealed negative Myo D expression at all-time intervals, in the mature muscle fibers (Fig. 3a H&E, 3b Myo D). On the other hand, the positive control group (G II) showed large necrotic mass, at the distal pouch end, surrounded by hyper-keratinized hyperplastic surface epithelium. The lamina propria was infiltrated by mixed inflammatory cells (mainly chronic inflammatory cells), and no muscle fibers were seen at these areas (Fig. 3c& d). Whereas at areas of new muscle formation, they were multinucleated and showed mild diffuse Myo D stain (Fig. 3e& f).

In group IIIa (one i.p TQ injection): the histopathologic findings revealed reduction of the distal necrosis, the nearby epithelium was hyperplastic with no muscle fibers in these areas. Followed by progressive increase of muscle fibers. IHC results revealed positive Myo D for perivascular MCs (Fig. 4 a& b).

After 2 days of two i.p TQ injections (G IIIb), the inflammatory cells were focally aggregated in the subepithelial areas then extruded from the surface epithelium, with no muscle fibers are seen in these areas. Meanwhile, in the same pouches increased perivascular MCs are seen in areas of new muscle formation (Fig. 5a& b). From one and two weeks, the nuclei of muscle fibers become loose and were positively stained with Myo D (Fig. 6a). While at areas of continuous muscle fibers' formation, the perivascular MCs were positive for Myo D (Fig. 6b). At the periphery of the necrotic end spindle shape cells predominate the border between the necrotic end and the area of perivascular mononuclear cells, which was seen from day 4 to end of the experiment, in pouches of group III (Fig. 7a).

Fig. 8 shows the increase of MFs from an area of thick collagenous lamina propria where the perivascular mononuclear cells are evident (8a), and when the lamina propria became thinner, the muscle fibers were thicker and compact (8b).

IV. Discussion

The present work aimed to look at the early events of muscle regeneration, following shortening of the hamster buccal pouch due to DMBA painting for 6 weeks, under the influence of thymoquinone (TQ). TQ, was used for its strong anti-inflammatory effect, especially in a carcinogenesis model.⁽¹⁷⁾ The time of euthanization was determined according to the sequence of differentiation of satellite cells (Myo D expression), starting from 2-4 days post injury,⁽¹⁸⁾ as well as the time taken from an ip injection to reach the hamster pouch (2 hrs).⁽¹⁹⁾ In a recent study carried out in that lab, TQ ip injections (0.1 mg/kg body weight), in hamsters, at the same time with DMBA painting for 6 weeks, had resulted in elongation of the painted pouches to near normal, with no gross changes (as redness, ulcerations, or tumors). Inflammatory cells were focally aggregated and expelled from the surface epithelium from the second week, (time of first euthanization).⁽²⁾ In the present study, this interesting finding was observed 2 days after the first ip TQ injection. That would confirm the efficient anti-inflammatory effect of TQ. Supporting this notation is the significant increase of serum TNF- α level at the same time. i.e. TQ has both acute local and systemic anti-inflammatory actions with a very minimal dose.

By end of the present work, the animals given TQ, showed elongation of normal appearing pouches, however, remains of the distal necrosis covered by hyperplastic epithelium, was seen histologically. The rest of the pouches' mucosa showed progressive increase of muscle layer bulk, under normal appearing epithelium and non inflamed lamina propria. Comparable finding was reported by Hassan et al (2017)⁽²⁾ and El-Sherbiny et al (2016).⁽¹⁹⁾

It is known that the classic pathway for muscle repair, following damage, takes place by activation of stem cell populations (either muscle satellite cells, or other non-muscle stem cells).^(18, 20) This step depends, in part, on the TNF-NF- κ B pathway,^(21, 22) as well as TNF- α concentration.⁽¹²⁾ DMBA for six weeks, in the present work, results in systemic toxicity to most body tissues/ organs,⁽²³⁾ TQ appears to result in expulsion/ excretion of the formed TNF in the affected tissue cells, as seen in the present work. This finding was supported, in a comparable study, when IHC expression of TNF- α was negative in both inflammatory cells and surface epithelium of the TQ-treated hamsters, NF- κ B was negative as well in these groups.⁽²⁾ In both studies, the present and referred one, focal aggregation and extrusion of inflammatory cells was a constant finding within 2 days of ip TQ (in the present work), or during DMBA painting (the defined 2 weeks interval for euthanization). This explains absence of inflammatory cells in pouches of TQ-treated animals, from the second day of last injection. Regression of serum TNF level after 2 ip TQ injections would be due to excretion of most TNF from affected cells after the first TQ injection that suppressed the inflammatory response of DMBA-treated groups.

Following muscle damage, satellite cells escape quiescence and proliferate, forming multinucleated myotubes and proceed through regeneration and terminal differentiation.⁽¹⁸⁾ This sequence was observed when DMBA painting was sustained, in group II, of the present work. Most muscle fibers were multinucleated, and all

fibers were (-ve) for Myo D. It is possible that increased TNF in these pouches had resulted in destabilization of Myo-D, as reported by Langen et al, ⁽²⁴⁾ in a NF-kappa B-dependent manner. Or the timing of euthanization did not detect Myo-D expression during this regenerating process of muscle fibers. Of interest is that after 1 and 2 weeks of 2 TQ injections, when the pouches' appearance and length were near normal, the muscle fibers were mature compact, and their nuclei were Myo D positive. It is proposed that remodeling of the highly increased muscle bulk is taking place from these time periods, as shown earlier by Musarò (2014). ⁽¹⁸⁾ The author indicated that from day 10-15 post cardiotoxin injury, remodeling of muscle fibers take place. El-Sherbiny et al, reported an elongated hamster pouch, normal appearing muscle layer was seen after 6 weeks of TQ injections. ⁽¹⁹⁾

This model of muscle injury, chemical carcinogenesis, appears to follow the classic model of muscle regeneration at least after sustained carcinogen painting. As the newly formed muscle fibers were multinucleated, at the remaining part of the painted pouches only, indicating satellite cells activation and differentiation. However their localization by Myo D expression could not be detected at the time of euthanization (a day following the last painting). Whereas, TQ injections in that model, appears to be different than the classic models of muscle injury. ^(14,18) The local environment created by absence of inflammatory cells as well as loss of TNF- α , muscle regeneration with a very small TQ concentration and dose(s) as well as the short time of follow up, could take place through three non-myogenic lineages. **First** is perivascular mononuclear cells (MCs) that were Myo D positive from the earlier follow-up days, in groups given TQ. These MCs are expected to be bone marrow-derived stem cells [mesenchymal stem cells (MSCs)], ⁽²⁵⁾ or the pericytes, ⁽¹⁵⁾ due to their persistent relation to the local vessels in close proximity to the newly forming muscle fibers. **Second** is transition of FAP cells (near the area of necrosis) to the myogenic lineage. ^(16, 26) They appear spindle-shape elongated cells originating from the necrotic side towards the increasing muscle tissue. Hassan et al (2017) reported the same finding with transition of fibrotic to myogenic lineage by Masson's trichrome stain of similar spindle-shape elongated cells from the necrotic end. ⁽²⁾ **Third** is transition of fibroblasts, in the fibrotic lamina propria, to the myogenic lineage. ⁽¹⁶⁾ It would explain reduction of the thicker, dense lamina propria (in the DMBA only group) to thinner layer (TQ-injected groups) to be replaced by increasing muscle bulk.

V. Conclusion

Muscle regeneration, in the present model, appears to be through non myogenic satellite cells, after one or two ip TQ injections. It appears to be through its strong anti-inflammatory effect and independent on TNF- α .

Conflict of Interests: The authors declare that no conflict of interests.

Ethics approval: the study began before establishing the Research Ethics Committee (REC), Faculty of Dentistry, Suez Canal University.

References

- [1]. Mognetti B, Di Carlo F and Berta GN. Animal models in oral cancer research. *Oral Oncol.* 2006; 42(5): 448-508.
- [2]. Hassan MM, Abdel-Latif GA and El-Hossary WH. Protective and promising myogenic effect of two thymoquinone formulations in relation to the pouch-induced carcinogenic model. *IOSR J Dent Med Sci (IOSR-JDMS).* 2017; 16(5): 54-66.
- [3]. El-Khoriby SAS. Chemopreventive effect of different doses of nano-thymoquinone on chemically-induced oral carcinogenesis. M.Sc. thesis, Suez Canal University, Egypt, 20015
- [4]. Schneider-Stock R, Fakhoury IH, Zaki AM, El-Baba CO, Gali-Muhtasib HU.: Thymoquinone: fifty years of success in the battle against cancer models. *Drug Disc Today*, 2014; 19(1): 18-30
- [5]. Lionel B. The History, basic science and biology of TNF. Special Report. HSS Genomics Center, Hospital for Special Surgery, on line Posted: 9/20/2003
- [6]. Chen SE, Jin B, Li YP. TNF- α regulates myogenesis and muscle regeneration by activating p38 MAPK. *Am J Physiol Cell Physiol.* 2007; 292(5): C1660-C1671
- [7]. Qiao YC, Chen YL, Pan YH, Tian F, Xu Y, Zhang XX and Zhao HL. The change of serum tumor necrosis factor alpha in patients with type I diabetes mellitus: A systematic review and meta-analysis. *PLoS One.* 2017; 12(4): e0176157.
- [8]. El Menyawi M, Fawzy M, Al-Nahas Z, Hussein AE, Shaker O and Elwan H. Serum tumor necrosis factor alpha (TNF-a) level in patients with Behçet's disease: Relation to clinical manifestations and disease activity. *Egy Rheum.* 2014; 36: 139-143.
- [9]. Zidi I, Mestiri S, Bartegi A, Amor NB. TNF-alpha and its inhibitors in cancer. *Med Oncol.* 2010; 27(2): 185-198
- [10]. Ferrajoli A, Keating MJ, Manshoury T, Giles FJ, Dey A, Estrov Z, et al. The clinical significance of tumor necrosis factor-alpha plasma level in patients having chronic lymphocytic leukemia. *Blood.* 2002; 100(4): 1215-1219
- [11]. Pfeffer K. Biological functions of tumor necrosis factor cytokines and their receptors. *Cytokine Growth Factor Rev* 2003; 14(3-4):185-191
- [12]. Renström L, Song Y, Stål PS, Forsgren S. TNF-alpha in an overuse muscle model-Relationship to muscle fiber necrosis/regeneration, the NK-1 receptor and an occurrence of bilateral involvement. *J Clin Cell Immunol.* 2013; 4:138- 145
- [13]. Guttridge DC, Mayo MW, Madrid LV, Wang CY, Baldwin AS Jr. NF-kappa B-induced loss of MyoD messenger RNA: possible role in muscle decay and cachexia. *Science.* 2000; 289:2363-2366.
- [14]. Shi X and Garry DJ. Muscle stem cells in development, regeneration, and disease. *Genes Dev.* 2006; 20(13): 1692-1708.
- [15]. Caplan A, Correa D. The MSC: An injury drugstore. 2011; 9: 11-15
- [16]. Joe AW, Yi L, Natarajan A, Le Grand F, So L, Wang J, Rudnicki MA, Rossi FM. Muscle injury activates resident fibro/adipogenic progenitors that facilitate myogenesis. *Nat Cell Biol.* 2010; 12(2): 153-163.
- [17]. Mutabagani A, El-Mahdy A and Samiha H. Study of anti-inflammatory activity of Nigella sativa L. and thymoquinone in rats. *Saudi Pharm J.* 1997; 5: 110-113.

- [18]. Musarò A. The basis of muscle regeneration: Review article. *Adv Biology*, 2014; 2014: 1-16
- [19]. El-Sherbiny R, Hassan MA, Korraa A. Effect of different nanothymoquinone concentrations on the chemically-induced epithelial dysplasia in the hamster buccal pouch. *SCU Med J*. 2017; 20(1): 75-89.
- [20]. Davis RD, Weintraub H and Lassar AB. Expression of a single transfected cDNA converts fibroblasts to myoblasts. *Cell*. 1987; 51(6): 987-1000.
- [21]. Mardjiati S, Wulan M, Laswati H, Purnomo W, Pangkahila A, Yunifiar-Nasronudin MQ, Hadi U. Tumor necrosis factor alpha (TNF- α), nuclear factor-kappa B (NF-kB) p65 and calcineurin expression play a role in the regulation of muscle regeneration process through aerobic exercise in HIV patients.. *Bali Med J*, 2017; 6(2): 421-426
- [22]. Messina S, Vita GL, Aguenouz M, Sframeli M, Romeo S, Rodolico C, Vita G. Activation of NF-kB pathway in Duchenne muscular dystrophy: relation to age. *Acta Myologica*, 2011; 30(1): 16-23
- [23]. Nersesyan AK, Koumkoumdjian VA. The comparative mutagenic action of 7,12-dimethylbenz (a) anthracene in the Armenian hamsters and mice. *Arch Onc*, 2001; 9(3): 193-194
- [24]. Langen RC, Van Der Velden JL, Schols AM, Kelders MC, Wouters EF, Janssen-Heininger YM. Tumor necrosis factor-alpha inhibits myogenic differentiation through MyoD protein destabilization. *FASEB J*. 2004 Feb; 18(2):227-37
- [25]. Avolio E, Alvino VV, Ghorbel MT, Campagnolo P. Perivascular cells and tissue engineering: Current applications and untapped potential. *Pharmacol Therapeut*, 2017; 171: 83–92
- [26]. Uezumi A, Fukada S, Yamamoto N, Takeda S, Tsuchida K. Mesenchymal progenitors distinct from satellite cells contribute to ectopic fat cell formation in skeletal muscle. *Nature Cell Biol*, 2010; 12: 143-153

Thymoquinone Injection.. “Expression of MyoD in the DMBA-Treated Hamster Pouches Following Thymoquinone Injection.” *IOSR Journal of Dental and Medical Sciences (IOSR-JDMS)*, vol. 18, no. 2, 2019, pp 35-40.