

## **SUCCESSFUL CONSERVATIVE SURGICAL APPROACHE OF LARGE PAEDIATRIC RADICULAR CYSTS USING MARSUPIALIZATION TECHNIQUE: A RARE TWO CASE REPORTS**

Nuri Mustafa Alarabi\*, Salma S. Mo Zariba\*\*, Intesar Hassan Hussein Rih\*\*\*, Abdurahman Musbah Elmezwghi\*\*\* and Abeer Hussen Elsagali\*\*\*\*

### **ABSTRACT**

Children exhibit many pathological lesions involving the jaw bones. Radicular cysts are common inflammatory odontogenic cysts that arise from epithelial cell rests of Malassez due to periapical infection, originating from pulpal necrosis of a non-vital tooth. Radicular cysts are relatively rare in the primary dentition because of the distinct biological cycle of primary teeth. It comprise about 52% to 68% of all the cysts which affect the human jaw. Radicular cysts are usually asymptomatic, unless secondary infected, and discovered during routine dental radiographic examination. The lesion is seen radiographically as a circumscribed, well-defined radiolucent area bound by a thin radiopaque line. The treatment of the cysts can be either non-surgical management or surgical management being either marsupialization or enucleation. However, the treatment option should be kept as conservative as possible.

### **INTRODUCTION**

Most of the osteolytic lesions observed in children have inflammatory origin and arise as consequence of progression of caries in the deciduous teeth.<sup>(1)</sup> Radicular cyst is the most common inflammatory odontogenic cyst, <sup>(2)</sup> originates from epithelial remnants of the periodontal ligament (cell rests of Malassez) as a result of inflammation that is generally a consequence of pulp necrosis <sup>(3)</sup> which proliferate to form cyst wall.<sup>(4)</sup> Its pathological

cavity completely lined by non-keratinized stratified squamous epithelium of variable thickness.<sup>(5)</sup> Radicular cyst (RC) also known as periapical cyst, apical periodontal cyst, root-end cyst, or dental cyst.<sup>(6)</sup> Although dental caries is very common in children,<sup>(7)</sup> radicular cysts (RCs) are rare in the primary dentition, representing only 0.5 to 3.3% of the total number of RCs in both the primary and permanent dentition.<sup>(8)</sup> It can occur at any age,<sup>(9)</sup> with male predominance <sup>(10)</sup> and increased incidence

\* Assisstant Prof. in Oral and Maxillofacial Surgery Department

\*\* Lecturer in Oral & Maxillofacial Surgery Department.

\*\*\* Lecturer in Oral Pathology Department.

\*\*\*\* Assisstant Prof. in Oral & Maxillofacial Surgery Department Faculty of Dentistry, University of Tripoli, Libya.

in anterior maxillary region.<sup>(11)</sup> RCs are often seen in the periapical region but they can also develop lateral to the roots due to the presence of accessory canals.<sup>(12)</sup> Most reported cases of RCs were in molar teeth with apical infection caused by caries. It has been reported that RCs associated with primary incisor teeth are very rare.<sup>(13)</sup> Over the years, the cyst might regress, remain static or increase in size.<sup>(14)</sup> It usually grows slowly, rarely attains a large size.<sup>(15)</sup> Cyst formation in children may cause bony expansion and resorption, delayed eruption, malposition, enamel defects or damaging of the developing permanent successors.<sup>(16)</sup> Dental caries is the most common etiology for development of RC but it may also develop secondary to traumatic injuries,<sup>(17)</sup> which causes the necrosis (death) of the pulp tissue,<sup>(18)</sup> toxins exit at the apex of the tooth which leads to periapical inflammation. This inflammation further stimulates the epithelial cell rests of Malassez, which are present in the apical periodontal ligament, resulting in the formation of a periapical granuloma. Eventually, this epithelium undergoes necrosis caused by a lack of blood supply and a granuloma becomes a RC.<sup>(19)</sup> Most of the RCs are asymptomatic and are discovered accidentally when periapical radiographs are taken.<sup>(20)</sup> Radiographically, the classic description of the lesion is a round or oval, well-circumscribed radiolucent image involving the apex of the infected tooth.<sup>(21)</sup> Chair side diagnosis of periapical cyst can be made based on the following: (i) the periapical lesion involves one or more teeth with non-vital pulps, (ii) the lesion has size  $>200 \text{ mm}^2$ , (iii) radiographically lesion is circumscribed, well-defined radiolucent area bound by thin radiopaque line and (iv) produces a straw-coloured fluid on aspiration or as drainage through an accessed root canal<sup>(22)</sup>. The treatment of the cysts can be either nonsurgical management or surgical management being either marsupialization or enucleation.<sup>(23)</sup> The treatment of choice is dependent on the size and localization of the lesion, the bone integrity of the cystic wall and its proximity to vital

structures, the treatment option should be kept as conservative as possible.<sup>(24)</sup> Marsupialization is usually preferred for large RCs and dentigerous cysts, particularly in children.<sup>(25)</sup> Marsupialization is defined as opening a window in the cyst wall which enables integration of the cyst lining with oral mucosa.<sup>(26)</sup> The mechanism of the reduction in the size of cysts by marsupialization is well known. An intra-cystic pressure stimulates the release of epithelial inflammatory cytokines such as IL-1 $\alpha$  and could initiate bone resorption by stimulating and activating the osteoclasts. The marsupialization inhibits the epithelial IL-1 $\alpha$  expression and reduces bone resorption and decreases the size of the cyst<sup>(27)</sup>. However, inflammatory cysts do not recur after adequate treatment. Failures may arise due to inadequate control of infection or incomplete removal of the cystic lining.<sup>(28)</sup>

### Case 1

A Libyan 8 years old girl, with no significant medical history was referred to the Oral and Maxillofacial Surgery Department, Faculty of Dentistry, University of Tripoli, for diagnosis and management of an asymptomatic unilocular radiolucency in the right side of the mandibular body, which was discovered during routine Orthopantomogram (OPG) examination for filling of a decayed tooth. On extra-oral examination, the face was symmetrical (fig.1) with non-palpable submental and submandibular lymph nodes. The federation Dentaire Internationale (FDI) tooth numbering system was used to record teeth present and the teeth involved. Intra-oral examination revealed extensive proximal carious lesion on the lower right primary first molar 84 (FDI) and large amalgam filling on the lower right primary second molar 85 (FDI) (fig.2). Electrical pulp testing revealed a negative response for both teeth and 84 (FDI) was slightly tender on percussion. Cone beam computed tomography (CBCT) examination revealed unerupted lower right permanent

premolar successor 44 (FDI) surrounded by well defined, unilocular radiolucency. The unilocular radiolucency was oval shaped with well demarcated radiopaque margins, measuring approximately 2cm x 2cm that extending from the distal aspect of the root of lower right primary canine 83 (FDI) to the mesial root surface of lower right permanent first molar 46 (FDI) (fig.3). On the basis of clinical and radiographic findings a provisional diagnosis of RC was made and surgical marsupialization technique was planned because the margins of the cyst was closely related to the mandibular canal and to save 44 (FDI) which is surrounded by a large cystic lesion. The marsupialization technique was performed by extraction of 84 (FDI) and 85 (FDI), a window was created through the exposed cyst for a better view as well as decompression of the lesion (fig.4) The cyst lining under 84 (FDI) could not be removed therefore histological examination was not performed. A plastic device of suitable length made of intubation tube was used, inserted in the cystic cavity to help decompression of the cyst (fig.5), a few small holes was made by a bur in order to which has a design preventing it from falling in or coming out from the cystic cavity and fixed easily with the surrounding soft tissue on suturing. The Six months postoperative clinical and radiographic follow-up indicated regression in the size of the cystic lesion and bone regeneration were noticed (fig.6). After 11 months, there was no clinical and radiographic evidence of recurrence, complete healing occurred and 44 (FDI) and 45 (FDI) were erupted spontaneously and guided to their correct position by orthodontic therapy (fig.7).

### Case 2

A Libyan 8 years old girl reported to the Department of Oral and Maxillofacial Surgery, Faculty of Dentistry, University of Tripoli, with

chief complaint of painless swelling of the left side of the lower jaw which was noticed since 1 month. Otherwise the child was physically healthy with insignificant medical history. On extra oral examination, there was a diffuse, non-tender hard bony swelling, in the left mandibular body region measuring 2 cm x 2 cm. The skin over the swelling appeared normal in color (fig.8). Intraoral examination revealed firm hard bony swelling with buccal cortical expansion, extending from lower left primary first molar 74 (FDI) to the permanent first molar 36 (FDI) and the mucosa over the swelling was red and inflamed. Clinical findings: 74 (FDI) showed proximal carious lesion with grade I mobility, 75 (FDI) showed extensive carious lesion with grade II mobility, both were non-tender on percussion with obliteration of the buccal sulcus. Electrical pulp test was negative. CBCT examination revealed a well-defined radiolucent area measuring 2.5 cm x 2.5 cm, the crown of the permanent first premolar 34 (FDI) involved in the radiolucent area while the second premolar 35(FDI) displaced downward by the cystic lesion (fig.9 a & b). On the basis of history, clinical and radiographic findings a provisional diagnosis of RC was made and surgical marsupialization technique was planned. 74 (FDI) and 75 (FDI) were extracted, a window was created and a plastic device was inserted and fixed as case1 procedures (fig.10 a & b). Band and loop space maintainer was given after post-surgical uneventful healing (fig.11). The Six months postoperative CBCT with regular clinical follow-up showed regression in the size of the cystic lesion and new bone formation were evident (fig.12). After 11 months of clinical and radiographic follow up a well-formed bone formation and complete healing as well as spontaneous eruption of the involved 34 (FDI) and 35 (FDI) (fig.13 a and b).



Fig. (1) Extra-oral examination revealed facial symmetry.

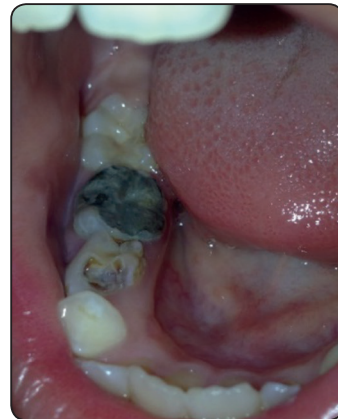

Fig (2) Intra-oral examination revealed 84 (FDI) with extensive proximal carious lesion and 85 (FDI) with large amalgam filling.



Fig. (3) CBCT examination revealed unilocular radiolucency was of oval shaped with well demarcated radiopaque margins, measuring approximately extended from the distal aspect of the root of 83 (FDI) to the mesial root surface of 46 (FDI).

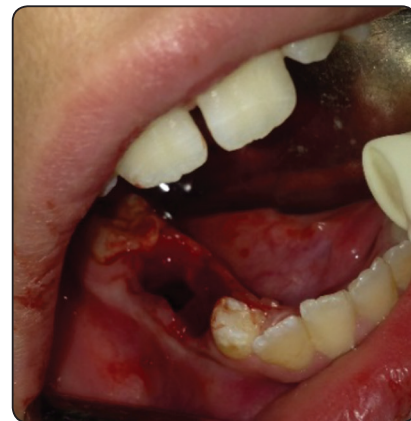

Fig. (4) A window was created through the exposed cyst after extraction of 84 (FDI) and 85(FDI).

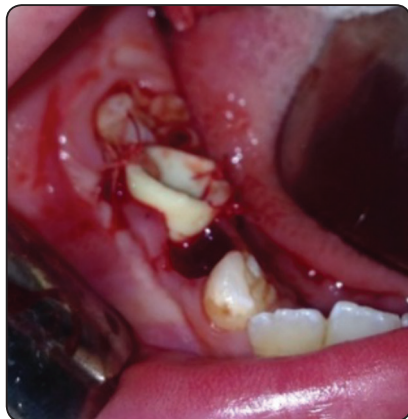

Fig. (5) A plastic device made of intubation tube was inserted through the cystic cavity

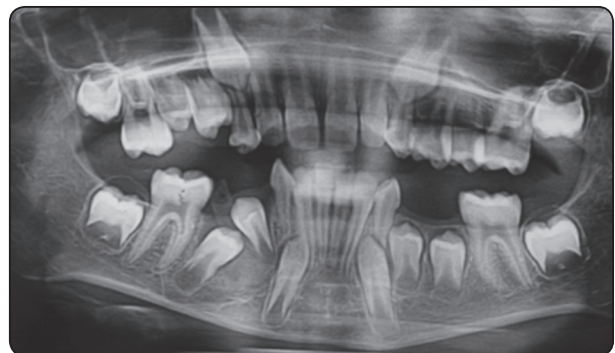

Fig. (6) Six months postoperative OPG showing regression in the size of the cystic lesion and bone regeneration were noticed.



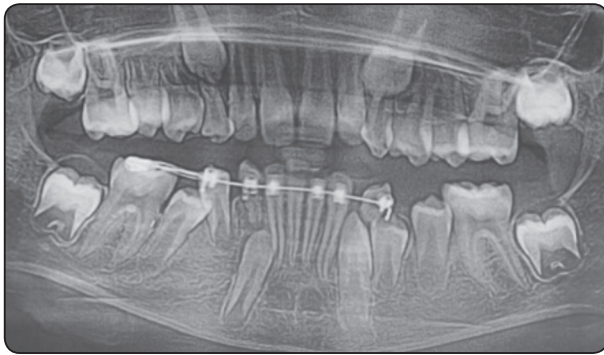


Fig. (7) 11 months follow-up OPG showing no evidence of recurrence, complete healing occurred and 44 (FDI) and 45 (FDI) were erupted spontaneously and guided to the correct position by orthodontic therapy.

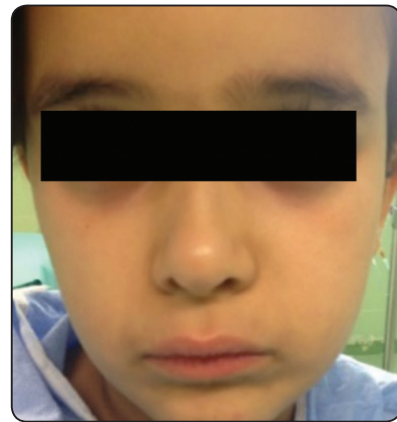

Fig. (8) Extra oral examination, revealed a diffuse non-tender hard bony swelling in the left mandibular body region.

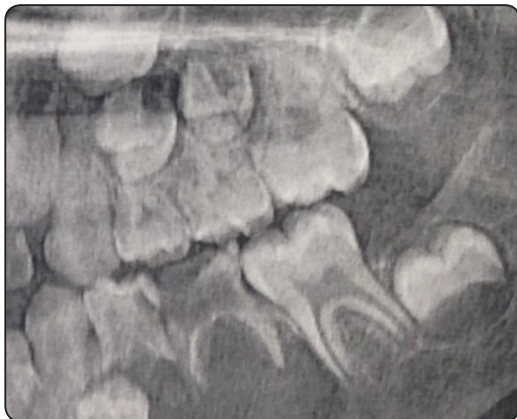

Fig. (9 a) preoperative OPG showing 74 (FDI) with proximal carious lesion and 75 (FDI) with extensive carious lesion.

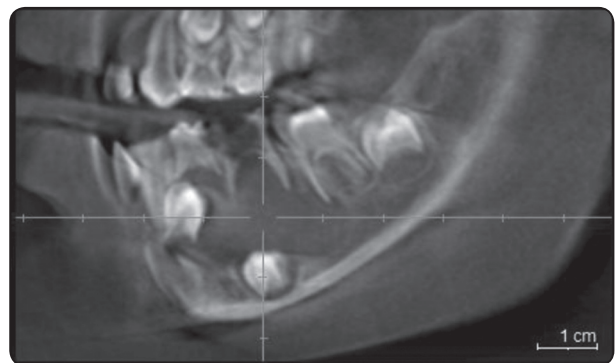
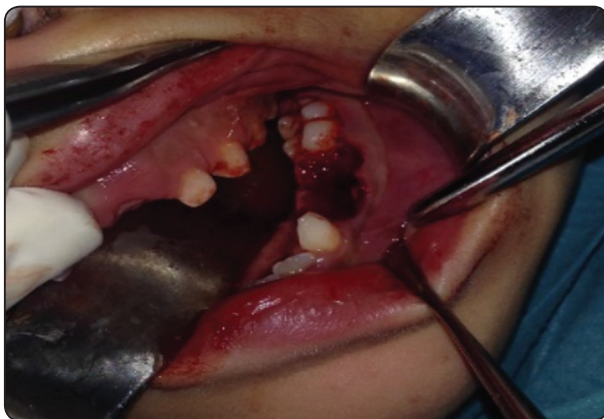

Fig. (9 b) Pre-operative CBCT examination revealed a well-defined radiolucent area, the crown of 34 (FDI) involved in the radiolucent area while 35(FDI) displaced downward. by the cystic lesion.



(10 a) 74 (FDI) and 75 (FDI) were extracted and a window was created.

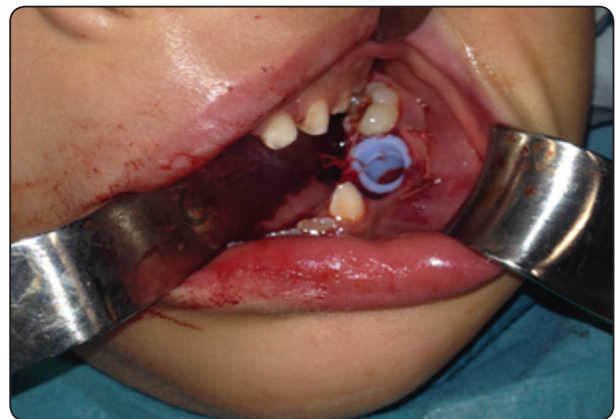

Fig. (10 b) A plastic device made of intubation tube was inserted and fixed

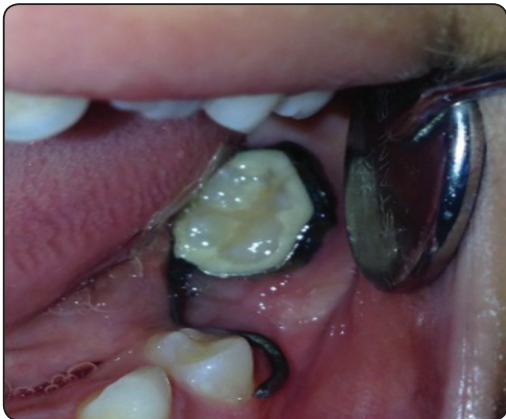

Fig. (11) Band and loop maintainer was given after uneventful healing.

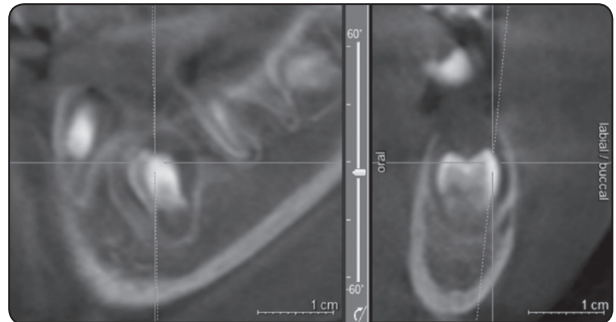


Fig. (12) Six months CBCT follow up showing marked regression in the size of the cystic lesion and new bone formation was evident.

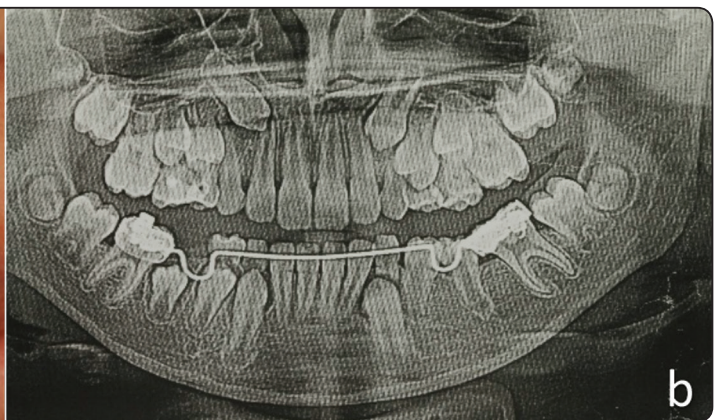
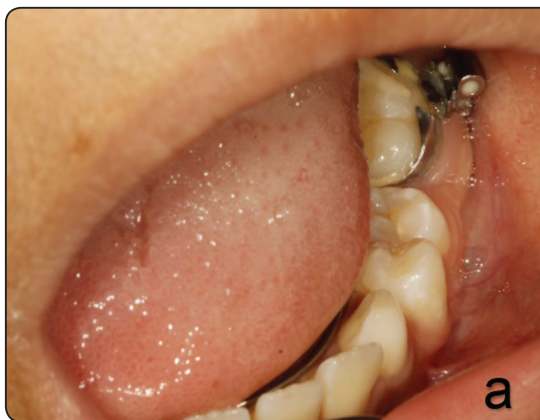

Fig. (13 a&b) After 11 months of clinical and radiographic follow up a well-formed bone formation and complete healing as well as spontaneous eruption of the involved 34 (FDI) and 35 (FDI).

**DISCUSSION**

RCs arise from periapical granulomas formed on devital teeth<sup>(29)</sup>.

RCs are by far the most common cystic lesions of the jaw.<sup>(30)</sup> and comprise about 52% to 68% of all the cysts affecting the human jaws.<sup>(31)</sup> It was coincided to the studies of Jones and Franklin<sup>(32)</sup> and Skiavounou et al<sup>(33)</sup>, in which RCs were the most common lesions in these two studies.<sup>(34)</sup> RCs originating from primary teeth are considered rare. <sup>(28)</sup> It was represented only 1% of cases develop in primary teeth. The reason for the low incidence of a RC in primary teeth compared with permanent

teeth is thought to be due to shorter life span of primary teeth, easy drainage of inflammation due to accessory canals, and neglected radiolucent findings in the apical area of primary teeth. <sup>(35)</sup> Additionally, lesions can resolve on their own after extraction or exfoliation of the tooth and, consequently, are not sent for tissue examination and diagnosis. <sup>(8)</sup> Very few cases of RCs are seen in the first decade.<sup>(36)</sup> Our patients were 8 years old, it was coincided with Shear 1994 and Donath 1985 who reported that about 1% of RCs appear in this life period <sup>(37)</sup>. Girls have higher incidence than boys. <sup>(38)</sup> Our patients were girls, it was in agreement with Sepideh Siadati et al. 2013 <sup>(39)</sup> and Manekar VS, et al, 2014. <sup>(35)</sup>

But it was in disagreement with Nagata T, et al. 2008<sup>(40)</sup> and Lustmann J and Shear M. 1985 who reported male predominance.<sup>(41)</sup> The mandibular primary teeth are affected more frequently than maxillary teeth, in contrast to maxillary predominance in the permanent dentition that may be explained by different etiologic factors.<sup>(42)</sup> It was consistent with many previous studies but inconsistent with Takiguchi M, et al. 2001 who reported that it may occur in the maxillary primary molars too.<sup>(43)</sup> Most RCs in the primary dentition are associated with mandibular molars with extensive dental caries.<sup>(44)</sup> In our presented cases, pulp therapy with huge amalgam filling was done in case 2 and the cystic lesion was associated with grossly decayed deciduous teeth in case 1, denote carious lesion to be the etiological factor.

Most cysts associated with primary molars are located in the inter-radicular area and around the roots, whereas cysts related to permanent molars are usually located adjacent to the apex. This may be explained by the short and sometimes partially resorbed roots and the existence of accessory canals in the roots of primary molars<sup>(40)</sup>. Our findings were similar and in agreement with previous literature reviews. Most of the RCs are symptomless unless associated with concomitant infection and are usually diagnosed by routine radiography.<sup>(45)</sup> Our presented case 1 was absolutely asymptomatic, the cystic lesion was discovered as unilocular radiolucency during routine OPG examination, located in the right mandibular body, while our presented case 2 her chief complaint was a diffuse, non-tender hard bony swelling, in the left mandibular body region. It was coincided with many previous reported cases. The most common clinical and radiographic features of a RC in primary molars are thin reactive cortex,<sup>(34)</sup> mandibular buccal cortical plate expansion, the mucosa may exhibit bluish discoloration,<sup>(46)</sup> displacement of succedaneous teeth, Well-defined unilocular radiolucency associated with a primary tooth<sup>(47)</sup> and misleading preoperative

diagnosis.<sup>(48)</sup> Periapical radiolucencies of primary teeth may be misdiagnosed as a periapical granuloma or a dentigerous cyst of the permanent successor.<sup>(49)</sup> The differential diagnosis of RCs of deciduous molars with carious lesion or endodontically treated can be RC or Inflammatory dentigerous cyst of corresponding premolar. The RCs of intact deciduous molars are developmental dentigerous cysts of corresponding premolars.<sup>(35)</sup>

Our presented cases were diagnosed as a RCs in the primary dentition for following reasons: presence of large and painless radiolucent lesion in relation to roots of a non-vital primary tooth, size larger than 2 cm and involvement with successive permanent teeth in both presented cases, and displacement of the underlying successive tooth in case 2. Clinico-radiological diagnosis coincided with the histopathological diagnosis in 92% cases.<sup>(50)</sup> In our presented cases histopathologic examination was not performed because the cyst lining under the involved teeth could not be removed. The surgical approach to cystic lesions of the jaws is either marsupialization or enucleation.<sup>(51)</sup> The choice of treatment depends on various factors, such as age, location and size of the cyst, tooth position in relation to the cyst, proximity to the vital structures and the degree of root formation.<sup>(52)</sup> In our reported cases, we planned conservative treatment based on the age of the patients, size of the cysts and the strategic value of the associated teeth. The indications of marsupialization are large-sized cyst, to reduce morbidity such as damage of important structures, to avoid major bone loss, to prevent mandibular growth disturbances, and to avoid pathologic fracture.<sup>(53)</sup> The largest disadvantage of the conservative treatment is the preservation of pathological tissue inside the jaws without histological examination,<sup>(54)</sup> but this method has fewer complications than enucleation regarding the preservation of important anatomical structures and developing permanent tooth germs.<sup>(55)</sup> According to Neaverth, marsupialization consists of deroofting the outer wall of a cyst by surgical incision and establishing



permanent opening by suturing the remaining cystic wall to the mucosal surface<sup>(17-56)</sup> to relieve intra-cystic pressure.<sup>(57)</sup> After marsupialization a stent, either a rubber tube or an obturator should be inserted into the cystic cavity opening to prevent spontaneous closure thereby allowing drainage, irrigation of the cystic cavity and keeping it clean.<sup>(58)</sup> In the presented cases the treatment plan included extraction of the primary teeth involved followed by marsupialization and a plastic device of intubation tube was inserted into the cystic cavity to decompress the lesion. The intubation tube has an advantages that it can be altered in length to suit the depth of the cavity and considered a hygienic device. Marsupialization needs considerable patient care and patient cooperation for keeping the surgical site clean.<sup>(59)</sup> The children and their parents were very cooperative as they were regularly followed up visits and regularly used saline as mouthwash.

In our presented cases the RCs were successfully managed because of a complete elimination of the cystic lesions which was achieved only by marsupialization technique. Furthermore, a healing period was less than one year with spontaneous eruption of permanent premolar teeth, which aligned in their correct position by orthodontic therapy.

## CONCLUSION

The diagnosis and early treatment of RCs in children is great of importance, in order for prevention of adverse effects to the underlying permanent successor as well as the need for invasive surgical treatment. Marsupialization is a good adjuvant technique for the management of large cystic lesions involving the jaws. Marsupialization and decompression could easily be conducted by any dentist familiar with basic surgical procedures, in order to treat the pathology and preserve the tooth or teeth involved within the cyst. The successful preservation and eruption of the affected teeth in these case reports supports conservative management of RCs in children. Marsupialization is favored because of lower morbidity and the fact that bony growth occurs as

the lesion regress in size, resulting in more normal bony contour. In children, healing of the postsurgical osseous defects is always good as they have high propensity for bone regeneration thus making postsurgical healing uneventful.

## REFERENCES

1. Luciano Alberto de Castroa and Sergio Ricardo Campos Maiab. Maxillary osteolytic lesion in a 10-year-old girl: A dentigerous or radicular cyst? A case report and discussion. *Rev port stomatol med dent cir maxilofac.* 2012; 53(1):24–28.
2. Afshar H and Baniameri Z.: Conservative Treatment of a Radicular Cyst Associated with a Primary Mandibular Molar. *JIDAI.*2015;27(4):193-197.
3. Sulabha A Narsapur, Sangamesh N Chinnanavar and Sameer A Choudhari. Radicular cyst associated with deciduous molar: A report of a case with an unusual radiographic presentation. *Indian J Dent Res* 2012;23:550-3.
4. Mudjono H, Rahajoe, PS and Hasan CY. Marsupialization of radicular cysts on adolescent patients to reduce treatment morbidity (case report). *Journal of Dentomaxillofacial Science.*2017;2(2):1-5.
5. Tomar D. and Dhingra A. Nonsurgical Root Canal Therapy of Large Cystic Periapical Lesions Using Simple Aspiration and LSTR (Lesion Sterilization and Tissue Repair Technique: Case Reports and Review. *Dentistry, an open access journal.*2015;5(7):1-5.
6. Grover N, et al.: Radicular Cyst of Permanent Incisors and Its Management: A Case Report. *Annals of Dental Specialty.*2014;2(2):79-81.
7. Vijay Chander, et al.: Radicular cyst of maxillary primary tooth: Report of two cases. *Journal of Oral Research and Review.*2014;6(2):61-64.
8. Tiwari S and Reddy S. Management of Radicular Cyst of Primary Molar: Case Report & Literature Review. *BJMMR.*2017;22(2):1-6.
9. Tak O, et al.: Five-year clinical follow-up of a patient with radicular cyst in the maxillary anterior region. *Euro J of Prosthodont.*2016; 4(1):17-21.
10. Kumar ND, et al. Surgical Management of Large Radicular Cyst in Mandible. *Int J Dent Oral Health.*2017;3(2):1-5.
11. Shafer WG, Hine MK, Levy BM. *A text book of oral pathology.* Philadelphia: WB Saunders; 7<sup>th</sup>.2012.



12. Shear M, Speight P. Radicular and residual cysts. In *Cysts of the oral and maxillofacial regions*. 4th ed. John Wiley and sons; 2008:123-43.
13. Toomarian L, et al. Radicular cyst associated with a primary first molar: A case report. *J of Dent Tehr Univ of Med Scie*.2011;8(4):213-217.
14. Das DR, et al.: Management of a Large Periapical Cyst – Report of a Case and Review of Literature. *Saudi J. Oral. Dent. Res*.2017;2(1):1-4.
15. Köse E, et al.: Giant radicular cyst with bilateral maxillary sinus involvement. *J of Oral and Maxillofac Radiol*.2014;2(2):52-55.
16. Aggarwal P, et al.: Dentigerous cyst of the mandible. *Int J Head Neck Surg*.2013;4(2):95-97.
17. Delbem AC, et al.: Conservative treatment of radicular cyst in 5 year old child: A case report. *Int J Paediat Dent*.2003;13(6):447-50.
18. Karthik R and Mohan N. Nonvital Tooth- A Clue for Diagnosis of Radicular Cyst- A Case Report and Review.*Int J Radiol Radiat Ther*.2017;2(4)1-3.
19. Chanchal Singh, Tina Agarwal and Sonal Gupta. Surgical and supportive management of radicular cyst with palatal perforation: A case report. *IJADS*. 2017; 3(2): 224-227.
20. Mahesh BS, et al.: Role of Cone Beam Tomography in Evaluation of Radicular Cyst mimicking Dentigerous Cyst in a 7 years Old child: A case report and literature Review. *Int J Clin Pediatr Dent*. 2017;10(2):213-216.
21. C R A. Valois and E D Costa-Júnior. Periapical Cyst Repair After Nonsurgical Endodontic Therapy - Case Report. *Braz Dent J*.2005;16(3): 254-258.
22. Eversole LR. (2001).Clinical outline of oral pathology: diagnosis and treatment. *PMPH-USA.*, pp. 203–59.
23. Dwivedi S, et al.: Management of a large radicular cyst: A non-surgical endodontic approach. *Saudi Endo J*. 2014;4(3):145-148.
24. Narula H, et al.: Conservative non-surgical management of an infected radicular cyst. *Cont Clin Dent J*.2011;2(4): 368-371.
25. Delilbasi C, Yuzbasioglu E and Aydin K. Complete Healing of Radicular Cysts only by Marsupialization. *J Clin Case Rep*. 2012; 2(14):1-2.
26. Bozdogan E, et al.: Conservative management of a large dentigerous cyst in a 6-year-old girl: a case report. *J Dent Child*.2011;78:163-167.
27. Nanomiya T, et al.: Marsupialisation inhibits interleukin-1 alpha expression and epithelial cell proliferation in odontogenic keratocysts. *J Oral Pathol Med* 2002;31:526–533.
28. Penumatsa NV, et al.: Conservative approach in the management of radicular cyst in a child: Case report. *Case Rep Dent J* .2013; 2013:1-3.
29. Tek M, et al.:The predominant bacteria isolated from radicular cysts. *Head & Face Medicine*.2013;9(25):1-6.
30. Gagandeep Lamba and GR Ravi. Replantation of Displaced Underlying Successor and Marsupialization of Radicular Cyst associated with a Primary Molar. *Int J Clin Pedi Dent*.2015;8(1):70-74.
31. Nainani P and Sidhu KG. Radicular Cyst –An Update with emphasis on Pathogenesis. *Adv Med Dent Scie Res*. 2014;2(3):97-101.
32. Jones AV and Franklin CD. An analysis of oral and maxillofacial pathology found in children over a 30-year period. *Int J Paediatr Dent* 2006;16:19e30.
33. Skiavounou A, et al.: Intra-osseous lesions in Greek children and adolescents. A study based on biopsy material over a 26-year period. *J Clin Pediatr Dent* 2005;30:153e6.
34. F. Lei, et al.: Retrospective study of biopsied oral and maxillofacial lesions in pediatric patients from Southern Taiwan. *J Den Scie*.2014;9:351-358.
35. Shetty S, Angadi PV and Rekha K. Radicular cyst in deciduous maxillary molars: A rarity. *Head Neck Pathol*. 2010;4(1):27-30.
36. Ramakrishna Y and Verma D. Radicular cyst associated with a deciduous molar: A case report with unusual clinical presentation. *J Indian Soc Pedod Prev Dent*.2006;24(3): 158-160.
37. Manekar VS, et al.: Cysts in Periradicular Region of Deciduous Molars in Mixed Dentition: Retrospective Study of Five Cases. *Int J Clin Pediatr Dent* 2014;7(3):229-235.
38. Sharma S, et al.: Radicular Cyst in Association with Primary Molar: A Rarity. *Int J Dent Med Res* 2015;1(6):136-138.
39. Siadati S, et al.: Frequency of different oral lesions in children and adolescents in Babol, Northern Iran. *Caspian J Intern Med*. 2013;4(4):773-776.
40. Nagata T, Nomura J, Matsumura Y, Yanase S, Fujii T, Oka T, Uno S, Tagawa T. Radicular cyst in a deciduous tooth: a case report and review of literature. *J Dent Child*. 2008;75:80–84.

41. Lustmann J, Shear M. Radicular cyst arising from deciduous teeth- review of literature and report of 23 cases. *Int J Oral Surg.* 1985;14:153–161.
42. Naresh Sharma. Aggressive Radicular Cyst: Rare Case Generally Misdiagnosed In Children. *Int J Novel Research in Healthcare and Nursing.*2015;2(2):49-52.
43. Takiguchi M, et al.: Radicular cyst associated with a primary molar following pulp therapy: a case report. *Int J Paediatr Dent.*2001;11(6):452-5.
44. Mass E, Kaplan I and Hirshberg A. A clinical and histopathological study of radicular cysts associated with primary molars. *J Oral Pathol Med.* 1995;24(10):458-461.
45. Revathy V, et al.: An Unusual Case of Radicular Cyst in a Primary Canine. *International Journal of Dental Sciences and Research,* 2014;2(4): 95-98.
46. Dandotikar D, et al.: Nonsurgical Management of a Periapical Cyst: A Case Report. *J Int Oral Health.* 2013; 5(3):79-84.
47. Gandhi S. and Franklin DL. Presentation of a radicular cyst associated with a Primary Molar. *Europ Acad Paediatr Dent J.*2008;9(1):1-5.
48. Savage NW, et al.: A histological study of cystic lesions following pulp therapy in deciduous molars. *J Oral Pathol Med.*1986;15:209-12.
49. Eidelman E, Holan G and Fuks AB. Mineral trioxide aggregate vs. formocresol in pulpotomized primary molars: a preliminary report. *Pediatr Dent.*2001;23(1):15-8.
50. Paul S, et al.: A clinical study of cysts of the maxillofacial region and an assessment of clinico-radiologico-pathological variables affecting the formulation of a comprehensive patient need based treatment plan. *Indian J Dent.*2014; 5(2):69-74.
51. Bodner L. Cystic lesions of the jaws in children. *Int J Pediat Otorhinolaryngol.* 2002;62:25-29.
52. Durmuşlar S, Durmuşlar MC and Nale Conservative Treatment by Marsupialization of Dentigerous Cysts in Children: Report of three Cases. *Austin J Dent.* 2017;4(2):1-3.
53. Riachi F and Tabarani C. Effective management of large radicular cysts using surgical enucleation vs. marsupialization. *IAJD* 2010;1:1-8.
54. Carrera M, et al.: Conservative treatment of the dentigerous cyst: report of two cases. *Braz J Oral Sci.*2013; 12(1):52-56.
55. Hu YH, Chang YL and Tsai A. Conservative treatment of dentigerous cyst associated with primary teeth. *Oral Surg Oral Med Oral Pathol Oral Radiol Endod.*2011;112: 5-7.
56. Fawzi Riachi and Carine Tabarani. Effective Management of Large Radicular Cysts Using Surgical Enucleation vs. Marsupialization: Two Cases Report. *IAJD.*2010;1(1):44-51.
57. Kirtaniya BC, et al. Marsupialization: a conservative approach for treating dentigerous cyst in children in the mixed dentition. *J Indian Soc Pedod Prev Dent.*2010;28:203-208.
58. Sakkas N and Shoen R. Obturator after marsupialization of a recurrence of a radicular cyst of the mandible. *Oral Surg Oral Med Oral Pathol Oral Radiol Endod.* 2007;103:16-8.
59. Zhao Y, et al.: Changes in Bone Density and Cyst Volume After Marsupialization of Mandibular Odontogenic Keratocysts (Keratocystic Odontogenic Tumors). *J Oral Maxillofac Surg.* 2011 69:1361-1366.