

## Case Report

# Disseminated tuberculosis with cavitory lung lesion and tuberculoma in a six-month-old Libyan infant

Monira Ali Dakheel<sup>1</sup>, Abdelrahman Mohamed Najaim<sup>2</sup>, Ahmed Mesbah Moslah<sup>3</sup>, Halima Daw Buni<sup>4</sup>

<sup>1</sup> Pediatric Infectious Disease Department, Tripoli University Hospital, Tripoli, Libya

<sup>2</sup> Libyan National Center of Disease Control, Tripoli, Libya

<sup>3</sup> Radiology Department, Tripoli University Hospital, Tripoli, Libya

<sup>4</sup> Department of Family and Community Medicine, Tripoli University, Libya

### Abstract

The patient of the report is a six-month-old Libyan female, who presented with a history of fever, persistent cough, and an attack of seizure. The patient has been diagnosed with a case of brain Tuberculoma and cavitation in the right lung based on the Brain Magnetic resonance imaging and the Chest Computed tomography scan, respectively. Subsequently, the patient was treated with antituberculous drugs and corticosteroids. After finishing the treatment, the patient has been cured. This case illustrates the possibility of developing early disseminated tuberculosis during infancy and highlights the difficulties of the diagnosis during the early stages of the disease. The case emphasizes the benefits of early diagnosis and treatment to prevent severe consequences in infancy.

**Key words:** Tuberculosis; TB; MRI;BCG; meningitis.

*J Infect Dev Ctries* 2021; 15(12):1929-1932. doi:10.3855/jidc.15154

(Received 10 April 2021 – Accepted 01 July 2021)

Copyright © 2021 Dakheel *et al.* This is an open-access article distributed under the Creative Commons Attribution License, which permits unrestricted use, distribution, and reproduction in any medium, provided the original work is properly cited.

### Introduction

With an estimated Tuberculosis (TB) incidence rate of 40 per 100,000 of the population, Libya has been classified as a middle burden TB country. However, the treatment success rate is 59% [1]. Central nervous system (CNS) infection by *Mycobacterium tuberculosis* is a severe manifestation of disseminated TB in children [2]. The disease starts with the dissemination of bacilli from the lungs via the blood and lymphatic system, resulting in the development of caseation vascular foci (Rich foci) that allows bacilli to enter the subarachnoid space and brain parenchyma. The location of rich foci on the CNS and the infant's immune system determines the outcome as either focal tuberculomas or diffuse CNS meningitis [2,3]. Children are more prone than adults to develop a severe form and life-threatening conditions of extrapulmonary TB such as miliary (disseminated) and CNS TB, which can be attributed to risk factors including age, immunological status, diabetes, nutritional status, and genetic factors [3,4]. The clinical presentation of CNS TB (TB meningitis or Tuberculoma) is usually non-specific, which can lead to a delay in diagnosis and treatment. This may result in severe complications such as neurological damage, deafness, visual disturbances, seizures, hydrocephalus,

and ischemic brain injury, especially in children under 5 years [3,4,5].

### Case report

A six month old Libyan female was presented to us in November 2018 with a two month history of fever and cough that started at the age of three months. Her temperature was intermittently reaching up to 39 °C and did not respond to antibiotics. Two weeks later she developed a dry cough, which was more frequent in the morning but did not interfere with her sleeping. She was hospitalized at a secondary care medical center as a case of aspiration pneumonia. She stayed for two days in the Intensive Care Unit, followed by three days in the pediatrics ward. However, her symptoms of fever and respiratory distress did not improve, despite treatment with intravenous antibiotics (IV). Subsequently, the patient was brought to Tripoli University Hospital. On her way to the hospital she developed an attack of convulsion. Regarding the patient's history, she was the third child of healthy consanguineous Libyan parents. She was a full-term baby born through normal vaginal delivery and she was fully immunized for her age at the time of presentation.

**Clinical findings**

Upon physical examination the patient was found to have mild tachypnea, mild respiratory distress, and mild lower limb edema, the temperature was 38.4 °C, with stable vital signs, and the weight was 5.44 kg (on the third percentile). Other measurements were all in the normal ranges.

Respiratory system examination showed bilateral decreased air entry all over the chest with crepitations.

CNS examination revealed hypotonia, Moro’s reflex was weakly positive, and had a head lag. The rest of the examination was unremarkable.

The Bacille Calmette-Guerin (BCG) scar was visible. The laboratory investigations showed severe anemia hemoglobin (HGB) (6.0 g/dL), elevated liver functions total bilirubin (TBil) (1.4 mg/dL), direct bilirubin (DBil) (0.9 mg/dL), glutamic oxaloacetic transaminase (GOT) (284 u/L), and gamma-glutamyl-transpeptidase (GPT) (303 u/l), hypoalbuminemia (2.3 g/dL, high C reactive protein (CRP 24 mg/L). viral screens for human immunodeficiency virus (HIV), hepatitis B virus (HBV), and hepatitis C virus (HCV) were negative, and other investigations were all within normal ranges. A chest radiograph posteroanterior view showed a well-defined paravertebral opacity in the right upper zone that is suggestive to be originating from the lung parenchyma.

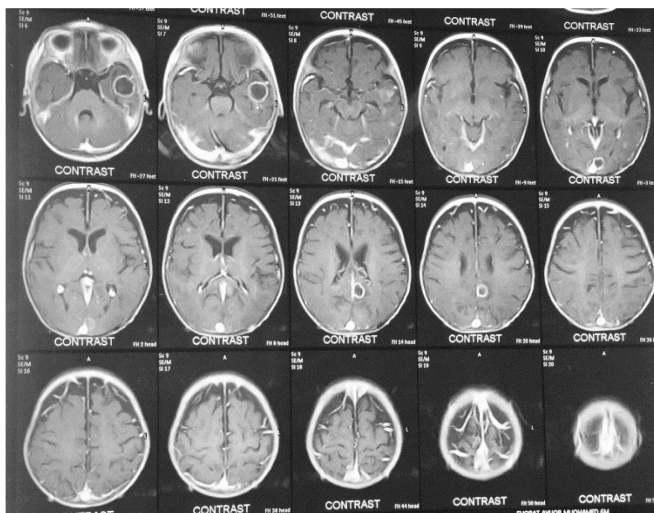
A brain Magnetic Resonance Imaging (MRI) with contrast showed multiple enhancing thin-wall rings, intra-axial different sized lesions with leptomenigeal

enhancement, mild surrounding edema, and mild mass effect; the largest was at the left temporal region and other lesions were located at the left parietal and left occipital lobes (Figure 1). A Chest Computed Tomography scan (CT) with contrast revealed a thick-walled cavitory lesion with an air-fluid level in the posterior segment of the right lung lobe. Also, there was a small patch of consolidation with air bronchogram in the posterior segment of the left lower lung lobe, associated with minimal reactive pleural effusion and scattered small branching opacities (Tree in bud signs) (Figure 2). Based on these findings, the case was diagnosed as disseminated tuberculosis with cavitation of the lung and brain Tuberculomas.

Gastric aspirate for Acid-fast bacilli was negative, and culture and sensitivity were negative. Gene X for TB was negative. The family screening using a tuberculin skin test for TB was negative, except her mother’s aunt was positive for TB. She was treated with anti-tuberculous drugs based on the following regimen: Isoniazid, Rifampicin, Pyrazinamide, and Ethambutol combination therapy for two months, Prednisolone 1 mg/kg for three months, and Isoniazid-Rifampicin combination therapy for ten months with Vitamin B6 supplement.

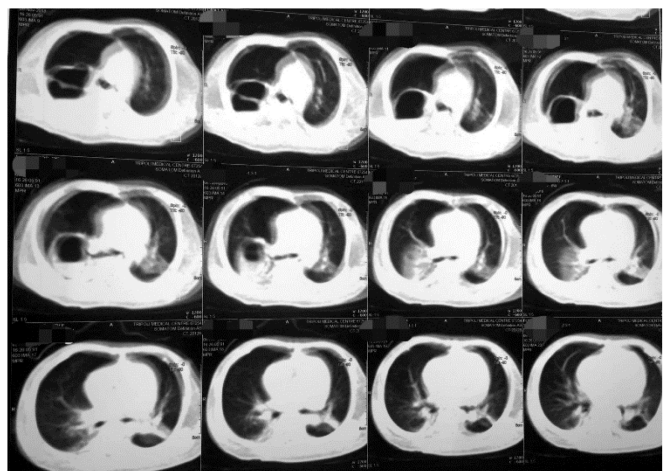
Thereafter, a control brain MRI with contrast was done. This revealed the complete disappearance of previously detected ring-enhanced intra-axial lesions, absence of leptomenigeal enhancement, and normal appearance of brain parenchyma with no significant

**Figure 1.** Brain MRI before treatment.



Brain MRI with contrast showed multiple thin-wall rings, enhanced intra-extra-axial different size lesions with leptomenigeal enhancement, mild surrounding edema and mild mass effect; the largest was at the left temporal region and other lesions were located at the left parietal and left occipital lobes.

**Figure 2.** CT scan of the chest before treatment.



A CT scan of the chest with contrast revealed a thick wall cavitation lesion with an air-fluid level in the posterior segment of the right lung lobe, inside. Also, there was a small consolidating patch with air bronchogram in the posterior segment left lower lung lobe associated with minimal reactive pleural effusion and scattered small branching opacities (Tree in bud signs).

abnormality (Figure 3). After the patient had completed the antituberculosis treatment course, she was found to have normal growth and normal neurological development through one year and a half of follow-up.

#### Declaration of patient consent

The authors certify that they have obtained all appropriate patient consent forms. In the form, the patient's parent has given his consent for his daughter's images and clinical information to be reported in the journal. The patient's parent understands that name and initials will not be published and efforts will be made to conceal identity.

#### Discussion

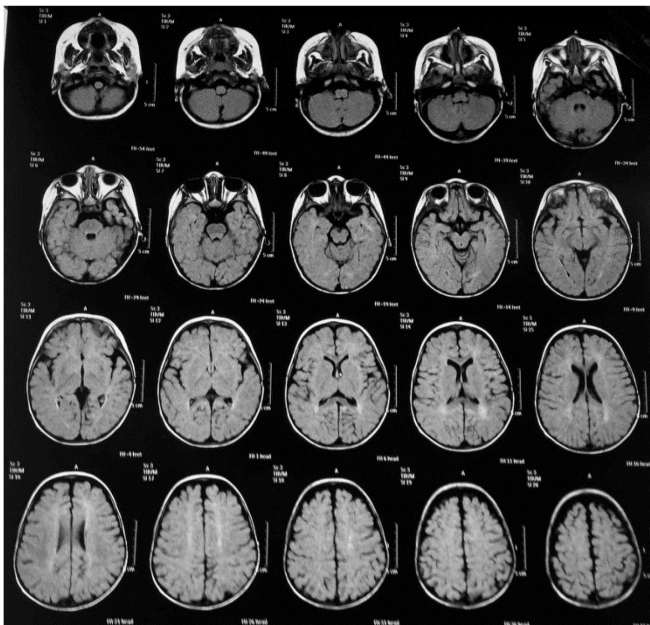
Tuberculoma as a result of disseminated tuberculosis can occur at any age, but it is most common in young children. Approximately 50% of infected infants below one year of age develop radiologically significant lesions within 2 months of initial infection, compared to 24% in children aged 1-10 years [4,5]. However, our patient developed symptoms from the age of three months old. This presentation at a young age can be attributed to the fact that immunity to TB in children is not well understood yet but this could be either due to insufficient production and function of Toll-like (Th1) receptors, dendritic cells, and

macrophages, or the decreasing ability of CD4 cells to express Th1 effector function, which may increase the risk of the disease in neonates and infants [4]. Since the mother's screening for TB was negative, this excludes the possibility of congenital tuberculosis in our case. However, environmental transmission from the mother's aunt elucidates the case. Moreover, because of the civil war in Libya, population displacement has changed the socioeconomic situation and there have been subsequent interruptions in the vaccination systems. It is known that BCG vaccination cannot prevent disseminated tuberculosis, as it happen in our case, who was vaccinated at birth with a BCG vaccine but still developed the disease. Furthermore, disseminated TB is common in malnourished infants and immunosuppressed patients [3,4]. Malnutrition can lead to anemia, weight loss, wasting, and insufficiency in micronutrients such as vitamins A, D, C, iron, and zinc. All these deficiencies can reduce the efficacy of cell-mediated immunity, therefore malnutrition and TB influence and compound the presence of each other [6]. Our patient had unexplained failure to thrive, anemia, and hypoalbuminemia. The diagnosis of extrapulmonary TB requires a high index of suspicion because it is difficult to confirm *M. tuberculosis* in children microbiologically, as the Acid-fast bacilli stains for body fluids are usually negative, culture and sensitivity are positive in less than 50% of cases, and up to 50% of pediatric patients are nonreactive to interferon-gamma release assay (IGRA) and Tuberculin skin test, especially those less than two years of age [2,6,8]. TB should be considered in infants who present with a history of fever and cough for a long duration that does not improve with regular treatment.

Tuberculous meningitis in children can be complicated by cranial nerves and basilar leptomeningeal involvement, hydrocephalus, infarctions, deafness, visual disturbance, and seizures [2,6].

Children with small tuberculomas often do not present with obvious signs of CNS infection, but those with large tuberculomas often present with focal seizures and neurological findings [2,7]. The neurological findings in our case were hypotonia, prolonged Moro reflex, head lag at more than three months of age, and seizure. They disappeared after antituberculous treatment during the routine follow-up of the case, her developmental assessment matched her age. A contact case is identified in only 50-70% of patients with TB meningitis, and the child usually becomes ill before detection of a contact case [2,6]. The literature has shown that the normal outcome of CNS

Figure 3. Brain MRI after treatment.



A control brain MRI with contrast was undertaken. This revealed the complete disappearance of previously detected ring enhanced intra-axial lesions, an absence of leptomeningeal enhancement, and normal appearance of brain parenchyma with no significant abnormality.



TB ranges between 11-61%, sequelae occur in 23-47%, and death in 13-41%. However, the poorest outcome is found in patients who have co-infection with HIV. Hearing loss is found in 7-30% of tubercles meningitis patients. The very high mortality rate is associated with a delay in treatment due to late diagnosis [9].

## Conclusions

Although disseminated TB at a very early age of life with advanced disease in the brain and lungs is rare and difficult to diagnose, early treatment can prevent any neurological complications or severe consequences upon development. Therefore, this case report highlights the importance of early diagnosis of tuberculosis (pulmonary / extrapulmonary) based on the patient's history and the clinical, laboratory, and radiological findings.

## Acknowledgements

We would like to thank the staff of the adult infectious disease department at Tripoli University Hospital for their help.

## References

1. World health Organization (WHO) (2021) Global tuberculosis report .Geneva: World health Organization 57 p.
2. St Cyr G, Starke JR (2019) Multiple cranial tuberculomas without meningitis in two infants with miliary tuberculosis. *Pediatr Infect Dis J* 38: e337-e339.
3. Chaulagain D (2019) Symptoms, diagnosis and surgical procedures of tuberculosis of the brain among infants a systemic review. *IJHSR* 9: 345-357.
4. Lamb G, Starke J (2017) Tuberculosis in infants and children. *Microbiol Spectr* 5: 0037-2016.
5. Dawani A, Gupta AK, Jana M (2019) Imaging in pediatric extra-pulmonary tuberculosis. *Indian J Pediatr* 86: 459-467.
6. Martin SJ, Sabina EP (2019) Malnutrition and associated disorders in tuberculosis and its therapy. *J Diet Suppl* 16: 602-610.
7. Gavigan P, Hysmith ND , Bagga B (2019) Lethargy and ataxia in a 3-year-old girl. *Pediatr Rev* 40: 194-196.
8. Balamohan A, Rubin LG, Assaad P, Hagmann SHF (2019) Case 1: intermittent fevers, persistent vomiting, and lethargy in a 3-year-old boy. *Pediatr Rev* 40: 191-193.
9. Nataprawira HM, Ruslianti V, Solek P, Hawani D, Milanti M, Anggraeni R, Memed FS, Kartika A (2016) Outcome of tuberculous meningitis in children: the first comprehensive retrospective cohort study in Indonesia. *Int J Tuberc Lung Dis* 20: 909-914.

## Corresponding author

Monira A. Dakheel, MD, Consultant Pediatrics  
 Department of Pediatric Infectious disease, Tripoli University  
 Hospital, University road, Ayenzara, 7425 Tripoli, Libya  
 Phone: 00218925817627; 00218214623701  
 Fax: 00218214625615  
 Email: moniradakheel@gmail.com

**Conflict of interests:** No conflict of interests is declared.