

Elevated temperature predisposes to impacted oil gland in sheep

Almahdi A. Jaber, Salem M. Mazeg

Department of pathology and clinical Pathology, Faculty of Veterinary Medicine, University of Tripoli, Libya

Abstract— Impacted oil gland is one of the commonest problems which cause transient lameness in sheep. The inter-digital oil gland is normal structure of sheep feet, sheep farming has an economic importance around the world, therefore it's very important to consider sheep welfare in order to develop sheep husbandry. One of the common issues that faces sheep welfare is lameness, sheep lameness is very common around the world with variety of causes which include foot root, foot injury and impacted oil gland. Foot root is very rare in southern Libya as the climate in sub-Saharan area is dry, however impacted oil gland is one of the major causes of lameness in southern Libya, this study has speculated that the occurrence of impacted oil gland in sheep is correlated with increased climate temperature. Despite impacted oil gland causes lameness in animal, it has not had a bad effect on animal health as foot root and spontaneous recovery was observed within few days. Squeezing and evacuation of the affected gland was enough for recovery of sheep from lameness without administration of antibiotics and anti-inflammatory drugs within 1-3 days. Good management including good sheltering and watering during hot seasons could reduce incidence of impacted oil gland in sheep.

Keywords— sheep, oil gland, temperature, Lameness.

I. INTRODUCTION

Impacted oil gland is a skin disorder of sheep occurs due to accumulation of white greasy material in the inter-digital pouch. The inter-digital pouch is an anatomical structure located in the inter-digital space of the four limbs of both sexes of sheep and the exact role of this gland still unknown (Misk et al 2013). Other study suggested the involvement of these gland in sexual communication, social behaviors and regional determination (Yilmaz et al 2017). The oil gland is a tubular structure consists of blind sac and long narrow neck ended with an opening on skin surface. Histologic examination of the neck and body walls showed presence of 3 layers which are epidermis, dermis and fibrous capsule, the dermis is consist of hair follicles, sebaceous glands, sweat glands and glandular apocrine (Awaad and Abedellaah 2010). Inflammation of the inter-digital pouches was observed (bokko 2003) and its position makes it exposed to frequent injuries (Sivachelvan et al 1992). Lameness is mainly associated with foot injuries, and interferes with animal productivity, other predisposing factors including both genetic and environmental factors are also involved in development of lameness (Gelasakis et al 2017). Studies have suggested that surgical removal of inter-digital pouch in lambs could be beneficial to solve

problems of foot infection in areas of high incidence of foot problems (Misk et al 2013, Sivachelvan et al 1992).

II. METHODOLOGY

This study was performed in region of Al-gatroun in southern Libya. The study has included 20 sheep of different breeds. The study has included both sexes of different ages. There was a variation in fleeces lengths of the animals. The general study was performed in April 2019 in a farm with good feeding and cleaning managements however the sheltering was not enough to be measured as an ideal sheltering to protect animals from high temperature. No changes were introduced to the animal's environment, the only change around the animal environment was elevation of temperature and no systemic diseases were observed in the flock. Animals have undergone to traditional treatment such as squeezing and cleaning of the oil gland without administration of any medication such as anti-inflammatory drugs.

III. RESULTS AND DISCUSSION

Impacted oil gland was observed in 30% of sheep (6/20) within 2 day when climate temperature suddenly changed

from 28°C to 38°C, among the affected group 83% were local breed which characterized with long fleece. 5/6 of the affected animals showed lameness on the first day of climate change and the other sheep showed lameness in the second day, the animal was very wet and sweating does not stop until the animal be shaved. The disease is mainly seen during hot season, incidence of the impacted oil gland is associated with elevation of temperature either in spring or summer, in this study impacted oil gland was observed during sudden elevation of temperature from 28°C to 38°C in April. Despite impacted oil gland cause lameness in animal (Bulgin), it has not had a bad effect on animal health as foot root and spontaneous recovery was observed within few days. All of the animals have shown fore limb impacted oil gland except one ram showed impacted oil problem in the hind limb, despite this condition is not very severe as foot root the ram showed poor performance with

inability to serve, this and other kind of foot problem may interfere with farm productivity (Gelasakis et al 2017). The problem was detected in adult sheep of both sexes, however lambs in the farm did not show any foot problem. Grossly, the lesion appears as extruded bead in the interdigital space containing a bundle of hair (figure A), and squeezing of lesion shows accumulation of white greasy material (Bulgin), pressing and evacuation of the gland lead to appearance of narrow pipe line structure (Mohamed and Adogwa 2016) tinged with blood without any signs of inflammatory reactions. Squeezing and evacuation of the affected gland and cleaning the area with water was enough for recovery of sheep from lameness within 1-3 days without administration of antibiotics and anti-inflammatory drugs. Post squeezing complication was not observed.

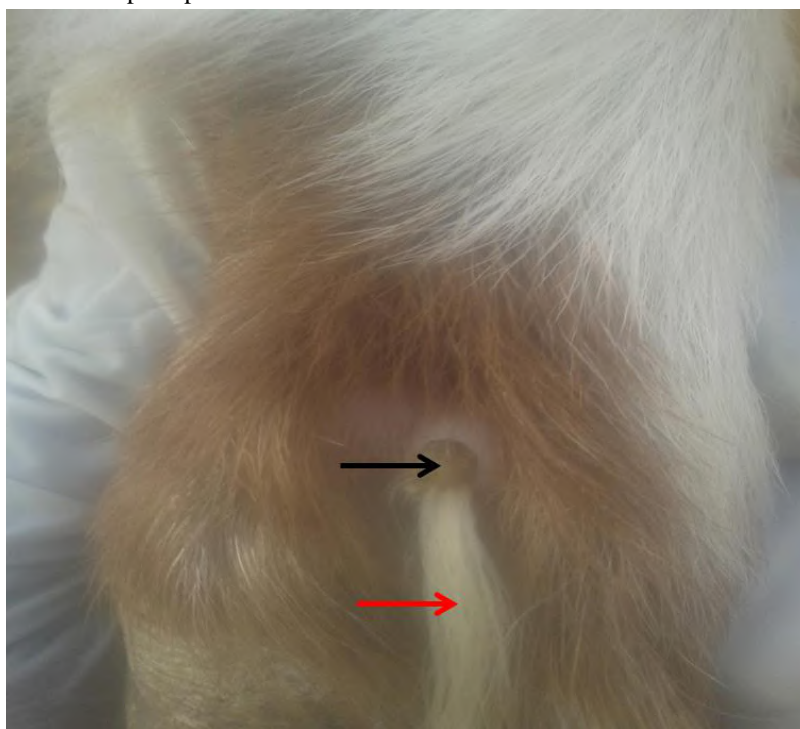


Fig.A: Impacted oil gland in sheep. Grossly, the lesion appears as extruded bead (Black arrow) in the interdigital space containing a bundle of hair (Red arrow).

IV. CONCLUSION

This study has demonstrated that elevated or sudden elevation of temperature predisposes sheep to impacted oil gland, particularly in long wool breeds. It looks a non-inflammatory condition associated with disturbance in secretory function of the gland. Good management through avoiding of exposure of animals to high temperature may reduce incidence of impacted oil gland. The problem can be solved without administration of antibiotics and anti-inflammatory drugs.

REFERENCES

- [1] Awaad AS, Tawfik MG, Moawad UK, Abdel Razek AH, Abedellaah BA. Morphohistological and surgical anatomy of the sinus interdigitalis in Egyptian native breeds of sheep. Beni-Suef Univ J Appl Sci 2015; 4: 157-166.
- [2] Bokko, B. P., Adamu, S. S. & Mohammed, A. 2003. "Limb Conditions That Predispose Sheep to Lameness in the Arid Zone of Nigeria," Small Ruminant Research, 47, 165-169.
- [3] Bulgin M, S. Impacted or infected oil gland in sheep. MSD MANUAL, veterinary Manual, University of Idaho.

- [4] GelasakisAI .2017.predisposing factors in sheep lameness (in Greek).journal of thehelleenic veterinary medical society.60,1,63-74.
- [5] MiskTN,Misk NA.2013.Surgical Excision of Interdigital Pouch and Cyst in Sheep. International journal of Veterinary Medicine: Research and Report.2013,187394,8.
- [6] Mohamed A., Adogwa A.2016..Gross and Microscopic feature of the interdigital Sinus in the Barbados Black Belly Sheep in Trinidad. International Journal of Current Research in Medical Science.2,7,22-27.
- [7] SivachelvanM. N., Yahaya, A. &Chibuzo, G.A. 1992. "Developmental Changes in theInterdigital Pouch of Yankasa Sheep," SmallRuminant Research, 9, 303-312.
- [8] YilmazB, YilmazR, DemirciogluI, Arican I.2017.Morphological and Histological Structure of the interdigital gland in Awassi sheep(Ovisaries).Turkish journal of Veterinary and animal science.41,380-386.