

# Maxillary Partial Immediate Overdenture Opposing Mandibular Fixed Prosthesis

Safa Elhadery<sup>@</sup> and Sireen Meheshi

Department of Prosthodontics, Faculty of Dentistry and Oral Surgery, University of Tripoli, Libya

Received 15 January 2021/Accepted 10 March 2021

## ABSTRACT

The treatment of a complex, partially edentulous patient using a combination of fixed and removable partial dentures has long been considered as among the most sophisticated forms of care. In addition to that the use of removable over denture prosthesis can achieve better aesthetic, enhance bone preservation and play an important role in the correction of malocclusion like in case of open and cross bite. This report describes the management of edentulous patient with combined fixed and removable over denture prosthesis. The removable partial denture (RPD) was designed such that it would take advantage of the benefits from milled surfaces of the fixed partial denture (FPD) to enhance stability and retention and allow maintenance of optimum oral hygiene. This achieved high patient satisfaction and oral health-related quality of life.

**Keywords-** Denture stomatitis; Opposing Mandibular : Fixed Prosthesis.

## Case Report

A 23-year-old man was referred to a prosthodontic department from a private clinic. His dental history revealed that he had a congenitally repaired bilateral cleft lip and palate. He had undergone an orthodontic treatment for the last 4 years. At the time of examination, the patient was wearing a maxillary and mandibular removable partial denture which acted as retention appliance after the orthodontic treatment. The patient's main complaint was "inability to chew" and he was dissatisfied with the aesthetic of his teeth. Intra oral examination revealed an anterior cross-bite and several missing teeth. Denture stomatitis related to the maxillary partial denture was also detected. The decision was made to provide the patient with fixed partial dentures in the mandibular arch and a maxillary partial immediate overdenture in the maxillary arch in order to improve the aesthetic of his anterior cross bite.

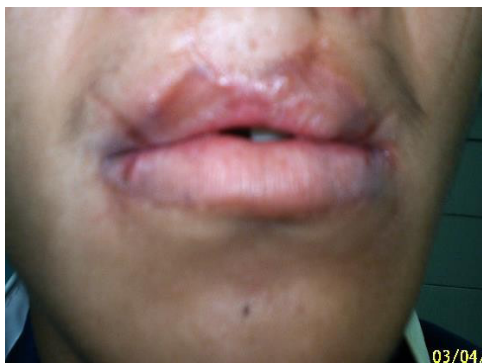

Figure 1: Extra oral anterior view

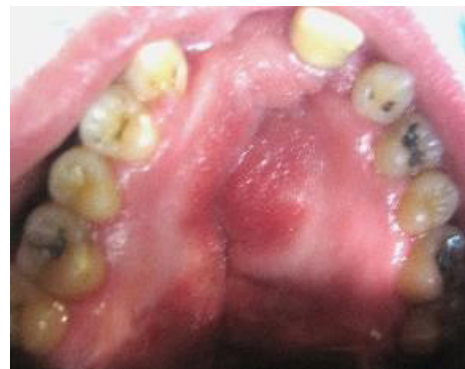

Figure 2: Occlusal view of the maxillary arch showing irregular palatal scar and localized gingival stomatitis

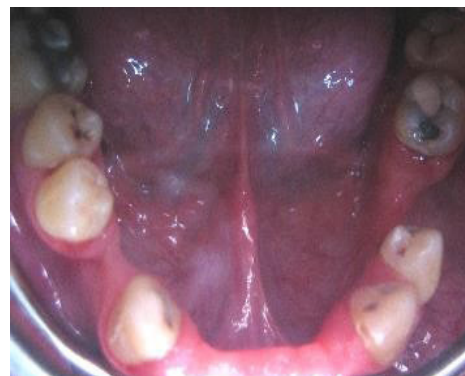
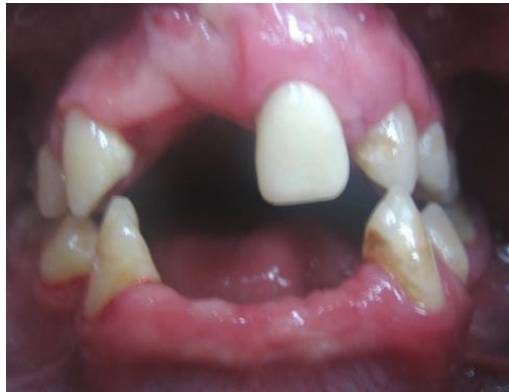
Figure 3: Occlusal view for the mandibular arch





**Figure 4:** Anterior view showing the discoloration of 23,24,33 and 43.

The patient chief complaint was inability to chew with the present partial denture and poor aesthetic. He has no specific medical illness. He had surgically repaired bilateral cleft lip and palate and reconstruction of the hard palate with bone graft. An orthodontic was done. The maxillary and mandibular arches have been partially edentulous more than 5 years ago. Patient had one pair of maxillary and mandibular partial denture since few months ago, which was given by the orthodontist to act as retention appliance. Patient claimed to brush his teeth once a day.

Extra oral examination showed that patient has symmetrical face, Incompetent lip seal and the contour and appearance of the upper lip revealed the scare tissue of the repaired bilateral cleft lip (Figure 1). Intra oral examination revealed localized denture stomatitis under the palatal site of the maxillary denture (Figure 2). Irregular thick mucosa on the site of repaired cleft palate with no remaining fistula. Palatal vault was deep (V- shape palate).

#### *Dental and Periodontal status:*

The 18, 12, 11, 22, 28, 38, 35, 32, 31, 41, 42 and 48 were missing (Figure 3). Amalgam restorations were noted on 16, 24, 26, 46 (class I) and 36 (class II), recurrent caries was detected on 36. large spacing between 43 and 44 was noted. Tooth discoloration was detected on 23, 24, 33 and 43 (Figure 4). The pocket depth was in the normal range for all the teeth except on the mesiobuccal, distobuccal and midbucall of 21 (4mm) and mesial and distal of 33 and 34 (3- 4mm). Grade I mobility was detected on 21.

#### *Radiographic examination:*

The panoramic view (Figure 5) showed generalized mild

to moderate bone loss around the mandibular teeth, root canal treated (21), scattered ill-defined radio-opaque masses between 43 and 44 and under the area of the missing (35), periapical views were taken to (21) to evaluate the root canal treatment (Figure 6) and for (43) to evaluate the apical area around this tooth and its relation to the radio opaque mass which has been noted between 43 and 44 (Figure 8).

#### *Diagnosis*

- Recurrent caries distal to 36.
- Initial stage of chronic periodontitis related to 33, 43 and 21.
- Localized marginal gingivitis in the area of 13, 23, 24, 34, 33, 43 and 44.
- Class III, modification 1 partially edentulous Kennedy classification in the maxilla and class III, modification 2 in the mandible.
- Localized denture stomatitis in the palate.
- Differential diagnosis for the radio opacity in the mandible were: osteoma, calcifying odontogenic cyst, fibro-cementosseous lesions or odontomes.

#### *Objectives of the treatment:*

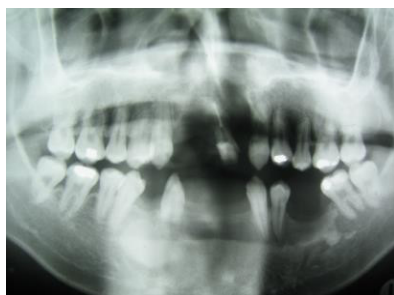- To improve the masticatory function, aesthetic.
- Preservation of the remaining healthy oral tissues.

#### *Treatment options:*

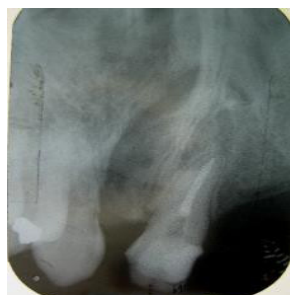- Fixed partial denture from 13 to 23 after the extraction of 21 and crowning of 24 and 25 opposed by fixed partial dentures from 36 to 34 and 33 to 43 and from 44 to 43 (to restore the large diastema).
- Fixed partial denture from 13 to 23 after the extraction of 21 and crowning of 24 and 25 with the construction of implant supported prosthesis to restore the anterior mandibular missing teeth and single implant prosthesis posteriorly with a bone graft between 34 and 36
- Removable partial over denture on 21 opposed by mandibular removable partial denture with overlay on 36, 35, 34 and 44.
- Removable partial over denture on 21 with overlay extension on 25 and crowning of 23 and 24 (to correct the cross bite and re-establish a proper occlusal plane) with the construction of fixed partial dentures in the mandible from 36 to 34 and 33 to 44.

#### *Treatment plan:*

##### *Pre prosthetic treatment:*



**Figure 5:** Dental panoramic radiograph



**Figure 6:** Peri-apical view of 21



**Figure 7:** Peri-apical view for 43



Oral hygiene instruction, scaling, prophylaxis and polishing, periodontal management for the detected localized gingivitis and periodontitis.

Treatment of the denture stomatitis.

Amalgam refilling on 36.

Orthodontic consultation regarding the occlusion of the posterior teeth and the anterior cross bite.

Consultation with the oral medicine or oral surgeon regarding the radio opacity on the mandibular arch.

**Prosthetic treatment:**

Because of financial status implant treatment was no possible. The treatment of choice was construction of fixed partial dentures on the mandibular arch 34 -36 and 44 - 33 and construction of a maxillary partial overdenture on 21 with overlay extension on 25 and milled crowns on 23 and 24.

**Clinical treatment program:**

**Periodontal treatment:** Full mouth scaling with deep scaling in the areas of 21, 33 and 43. Chlorohexidine mouth wash was described for 5 days (twice daily) and follow up after 2 weeks. The patient was under this program for 8 weeks before the actual prosthetic treatment started.

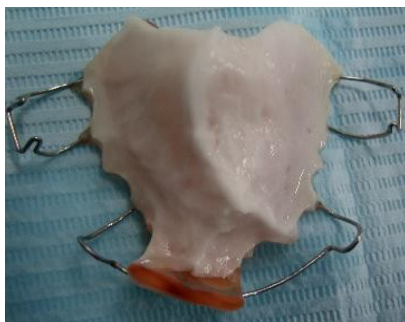
**Orthodontic and surgical consultation:**

According to the orthodontist no more orthodontic treatment can be given to the patient to improve his occlusion and aesthetic. However, the orthodontist advised to provide the patient with a final prosthesis which can prevent the collapse of the upper posterior teeth. No definitive diagnosis was given to the mandibular radio opacity because the patient refused to do a biopsy. So regular follow up was advised.

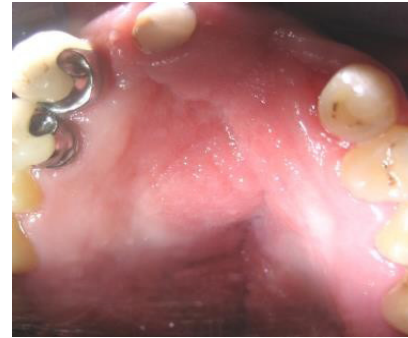**Treatment of the upper denture stomatitis:**

Denture hygiene instruction was given to the patient with an emphasis on denture removal at night to improve the palatal tissue statuses.

- Tissue conditioner (COE-COMFORT™) was added to the fitting surface of the denture on the palatal site and changed every 5 days until the stomatitis was subsided (Figures 8 and 9).
- Patient was requested to perform a finger massage on the infected area.
- Chlorohexidine mouth wash was described to be used 2-3 times daily for less than 10 days.



**Figure 8:** Tissue conditioner applied to the Existing maxillary appliance

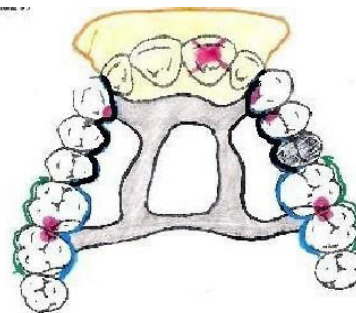


**Figure 9:** Complete recovery of the palatal mucosa

**Prosthetic treatment overview:**

Primary impression with alginate (Hygedent®) for both maxillary and mandibular arch. At the same visit, the arbitrary hinge axis was recorded and transferred to a semi adjustable articulator (KAVO 7 PROTAR®) and jaws relation recorded in centric occlusion.


Diagnostic mounting and waxing up for the final mandibular fixed partial dentures and the maxillary crowns were made. At the same time surveying of the maxillary cast and designing of the cobalt chromium (Co-Cr) frame work was done (Figure 10).



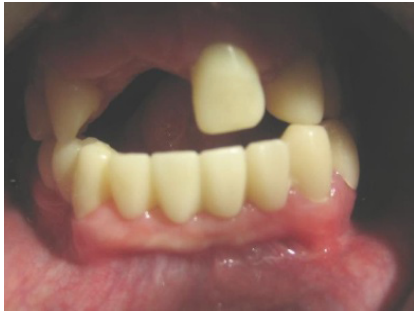**Figure 10:** Designing of the maxillary Co-Cr frame work

Construction of the provisional fixed partial dentures was made according to the diagnostic waxing up. Care was taken to provide the patient with a unilateral group functional lateral excursion of mandibular teeth (36, 34, 33, 43 and 44) were made and secondary impression was taken with a special tray and poly-ether rubber base material (Impergum™). Provisional prostheses were cemented on the prepared teeth until the final prosthesis will be ready (Figure 11). Preparation of the maxillary teeth (23, 24) was made in the next visit and provisional crowns were cemented after taking the secondary impression. Face bow transfer was made and transferred to a semi adjustable articulator (KAVO 7 PROTAR® evo) and jaws relation recorded in centric occlusion. During the issue of the final mandibular prosthesis and maxillary crowns (Figures 12-15) minor occlusal adjustments were needed to create the planned unilateral group functional occlusion. Secondary impression was taken with a special tray and alginate (Hygedent®) for the fabrication of the maxillary metal frame work (Figure 16). The alginate impression was made for mandibular arch with the final prosthesis and a new jaw relation record was made for the fabrication of the metal frame work with the metal overlay on 25.

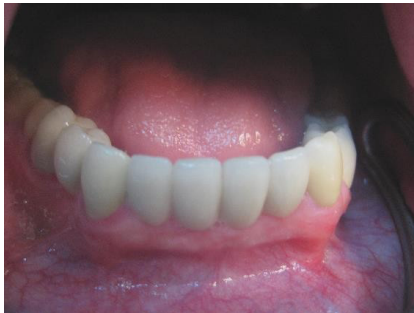Try in of the frame work was carried and the fitting was evaluated with a silicon disclosing material (Fit-checker III) Set-up the



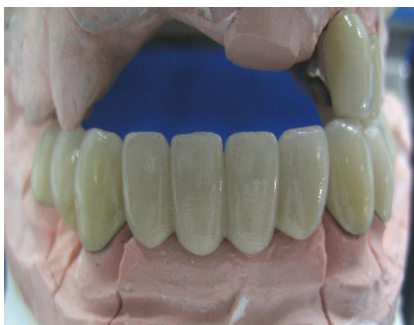teeth and processing of the final denture was made (Figure 17). At the issue stage, the 12 was decoronated to dome shaped about 3mm above the gingival margins. The complete seating of the denture was detected by the use of pressure indicating paste. Assessment of the occlusion was done in both centric and lateral excursion. Instruction was given to the patient for the proper denture hygiene. Reviewing the patient after 24 hours and one week was done and a high satisfaction was recorded (Figures 18,19).



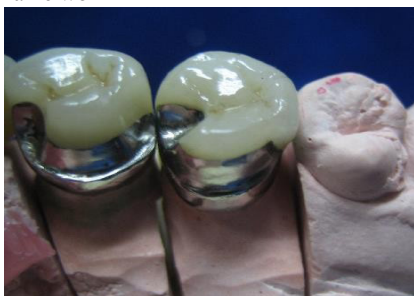**Figure 11:** Provisional mandibular bridges and crowns on 23 and 24



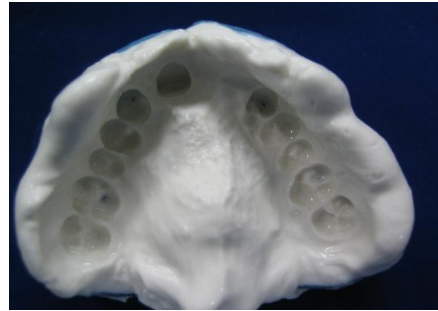
**Figure 12:** The final prostheses on the cast



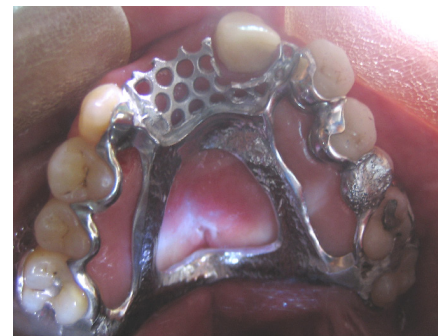**Figure 17:** Anterior view of the Intra oral occlusal view of the metal frame work



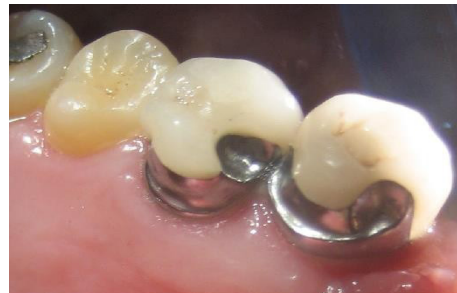**Figure 13:** Anterior view of the mandibular fixed partial dentures.



**Figure 14:** Anterior view of the The maxillary milled crowns on the cast



**Figure 15:** Anterior view of the Palatal view of the milled crown on 23 and 24



**Figure 16:** Anterior view of the Secondary alginate impression for the fabrication of the co.cr frame work

**Maintenance phase:**

The patient was advised to have a periodic periodontal maintenance with recommendations of removal of the prosthesis at night, regular topical fluoride application and soaking of the prosthesis in a cleansing agent for at least 20 minutes per day. Regular follow-up and routine radiographic examination were advised to detect any changes in the mandibular radio opacity.

**DISCUSSION**

Oral rehabilitation of complex, partially edentulous arches is one of the most challenging situations that a dentist could come across. Among the various treatments available implant supported prosthesis serves to be the optimum treatment because it saves the embarrassment of ill-fitting prosthesis.<sup>1,2</sup> However, there is a large population who do not opt for this treatment due to financial constraints.

A combination of fixed and removable partial denture prostheses with milled surfaces serves to be an acceptable option in these situations.<sup>3,4</sup> Yada et al.<sup>5</sup> stated that the



philosophy of combined prosthesis is: to minimize the area of soft tissues that should be covered by major and minor connector and to enhance the stability of removable prosthesis by frictional contact with the will designed and fabricated milled surfaces of fixed prosthesis.<sup>5</sup> The framework must have maximal possible contact with the milled surfaces so that they function as precision attachments.<sup>6</sup> In the present case the milled crowns offer the potential for good support, stability and prevent extra coverage of the gingivae by the major connector.

There are several advantages of the over denture prostheses such as preservation of the alveolar bone and correction of occlusion and aesthetic like in case of open bite or severe tooth wear.<sup>7,8</sup> In the present case construction of over denture on 21 resulted in a very good aesthetic and allowed a preservation of the alveolar bone around the tooth, so better masticatory performance can be achieved.

Several disadvantages are associated with partial overlaid overdenture. Aesthetic may be compromised when the prosthesis is removed.<sup>9</sup> Additionally, over denture treatment may be related to caries and periodontal disease as a result of poor oral hygiene.<sup>9</sup> However, in this case, proper denture hygiene instruction and fluoride application in the fitting surface of the denture during follow up visits could minimize this complication.<sup>10</sup>

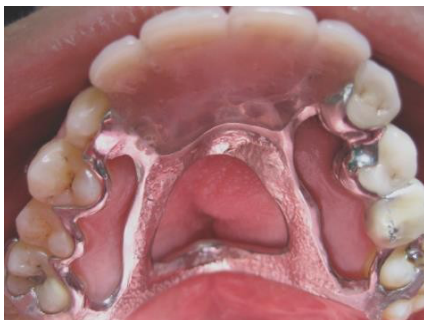When cross arch stabilization is needed, the removable partial denture is preferred over the fixed prosthesis.<sup>11</sup> In this case stabilization of the posterior maxillary teeth was achieved by the cingulum palatal bar.

In the present case, to avoid the effect of mandibular porcelain teeth on the acrylic artificial denture teeth and to provide good color matching between the maxillary and mandibular prosthesis, porcelain artificial teeth were used in the maxillary partial denture.

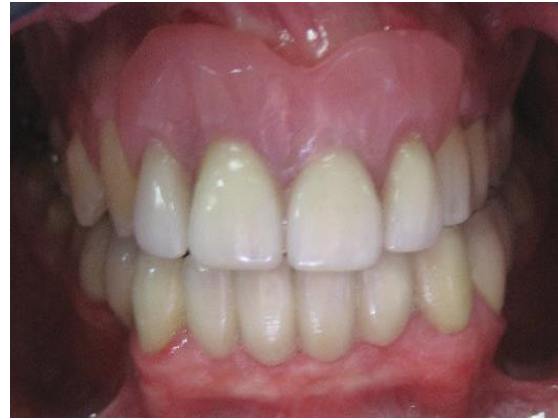## CONCLUSION

Within the limitations of this clinical report, combination of milled fixed prosthesis and removable partial over denture prosthesis successfully improves the esthetic, retention and function of the restoration. Subsequently, a high positive oral health-related quality of life and patient satisfaction were achieved.

More over the implication of a unilateral group functional lateral excursion in this case showed an affective result in maintaining and preservation of the remaining bone support and prevent more bone resorption.



**Figures 18:** Intra oral occlusal view of the definitive maxillary denture



**Figures 19:** Post-operative anterior view in centric occlusion

## REFERENCES

- Zarb GA, Bolender CL. Overdentures. In: Zarb GA, Jacob RF, Zarb J, editors. (2004) *Prosthodontic treatment for edentulous patients*. 12th ed. St. Louis: Mosby, p 160-176.
- Shillingburg et al. (2012) *Fundamentals of fixed prosthodontics*, fourth edition.
- Poštić SD, Šaulić S, and Biocanin V (2017) The effect of double-milled crown in indirect retention of removable denture, DOI: 10.13140/RG.2.2.28480.43520
- Brudvik JS, Shor A. (2004) The milled surface as a precision attachment, *Dent Clin North Am.* **48**, 685-708.
- Yada Chalyabutr and James.S. Brudvik (2008) Removable partial denture design using milled abutment surfaces and minimal soft tissue coverage for periodontally compromised teeth, *A clinical report*. Volume **99**(4), 263-266.
- Crum RJ and Rooney GE (1978) Alveolar bone loss in overdentures; a 5- year study, *J Prosthet Dent.* **40**(6), 610-613.
- Song MY, Park JM, Park EJ. (2010). Full mouth rehabilitation of the patient with severely worn dentition: a case report, *J Adv Prosthodont.* **2**(3):106-10.
- Ettinger RL (2004) Abutment tooth loss in patient with overdentures, *J Am Dent Assoc.* **135**(6), 739.
- Becker C and Kaldahl W (1984) An over denture technique designed to protect the remaining periodontium, *Int J Periodontics Restorative Dent.* **4**(4), 28-41.
- Jorgensen EB (1996) Restoration of the partially edentulous mouth-a comparison of over denture, removable partial denture fixed partial denture and implant treatment, *J Dent.* **24**(4), 244.

