



ISSN Print: 2394-7489
ISSN Online: 2394-7497
IJADS 2021; 7(1): 317-322
© 2021 IJADS
www.oraljournal.com
Received: 09-10-2020
Accepted: 02-12-2020

Abdurahman Musbah Elmezwghi
Oral Pathology, Department
Faculty of Dentistry, University
of Tripoli, Tripoli-Libya

Abeer Hussein Elsagali
Oral and Maxillofacial,
Department Faculty of
Dentistry, University of Tripoli,
Tripoli-Libya

Salma S Mo
Oral and Maxillofacial Surgery,
Department Faculty of
Dentistry, University of Tripoli,
Tripoli-Libya

Nesrin Hassan Musa
Oral maxillofacial Surgery,
Department Faculty of
Dentistry, University of Tripoli,
Tripoli-Libya

Nuri Mustafa Alarabi
Oral and Maxillofacial,
Department Faculty of
Dentistry, University of Tripoli,
Tripoli-Libya

Corresponding Author:
Abdurahman Musbah Elmezwghi
Oral Pathology, Department
Faculty of Dentistry, University
of Tripoli, Tripoli-Libya

Importance of preprosthetic routine panoramic radiography to detect asymptomatic pathologies in completely edentulous Libyan patients: A retrospective study

Abdurahman Musbah Elmezwghi, Abeer Hussein Elsagali, Salma S Mo, Nesrin Hassan Musa and Nuri Mustafa Alarabi

DOI: <https://doi.org/10.22271/oral.2021.v7.i1e.1148>

Abstract

Background: Panoramic radiography (PR) is a diagnostic modality value for providing a view of the entire maxillofacial region in a single film with a relatively low dose of radiation. It is used as an initial screening tool to examine completely edentulous jaws for preprosthetic evaluation, to detect asymptomatic conditions as root fragments, impacted teeth, radiopaque or radiolucent lesions, and foreign bodies.

Aim: The purpose of this study was to report the importance of PR survey of a partially and completely edentulous jaw, for detection of asymptomatic conditions prior to conventional or implant supported prosthetic rehabilitation.

Material and Methods: The present study was conducted on 263 panoramic radiographs (PRs), collected retrospectively for Libyan completely edentulous patients. The sampled PRs were evaluated and the collected data were tabulated and analyzed using Microsoft Excel (Microsoft Office 2013).

Results: The entire PR study subjects with pathological conditions were 73 cases (27.8%), while those with no pathologic conditions were 190 patients (72.2%). The most frequent pathological findings seen were residual cysts 33 (12.5%) followed by impacted third molars 16 (6.1%).

Conclusion: The PR preprosthetic routine examination, is very useful and important diagnostic tool to detect asymptomatic conditions of the jaws and surrounding structures.

Keywords: Routine panoramic radiography, asymptomatic pathological findings, completely edentulous jaws, preprosthetic evaluation, prosthodontic diagnostic value

Introduction

PR also known as orthopantomography, orthopantomogram (OPG), panoramic tomography or rotational radiography [1] that provides a unique image of both upper and lower dental arches [2]. PR has been used in the routine screening of patients at various institutions and private clinics for allowing examination of the entire dentition, alveolar bone, temporo-mandibular joints and adjacent structures at ease [3]. PR is a simple method for obtaining images by synchronous rotation of the x-ray source and image receptor around the stationary patient [4]. When PR is performed properly, it can provide valuable information from the edentulous jaws as retained root tips, impacted teeth, size of the residual alveolar ridge, radiolucent and radio-opaque lesions, the position of mental foramen, maxillary sinus, soft tissue calcifications, foreign bodies and other vital structures on the alveolar ridge [5]. Furthermore, it can be helpful in the implant placement, as well [6]. However, a significant amount of these radiographic findings, in edentulous patients, require treatment before prosthesis construction [7]. In many phases of prosthetic dentistry, healthy alveolar bone with normal regenerative capacity is essential for a successful treatment outcome [8]. Therefore, PR is of special effective value in diagnosis and treatment planning [9]. Despite few inherent limitations, PR still remains the diagnostic tool of choice [10]. PR is a widely used technique due to its advantage of providing, in a single film, the image of both jaws, with a relatively low radiation dose, in a short period

of time, and at lower cost, compared to more sophisticated techniques [11]. Furthermore, it can be used for patient with limited mouth opening as well as condylar evaluation [12]. However, the PR bears some disadvantages. It provides less sharp images, less accurate information about dental / oral diseases than regular intraoral periapical or bite-wing radiographs [13]. Routine panoramic examination of edentulous patients is a controversial subject and there is no agreement between the authors [14]. Nevertheless, The use of panoramic radiographs is considered, by some authors, as an important routine diagnostic tool for different conditions [15]. However, recent studies have shown that the pre-treatment radiographic examination of edentulous patients is critical in the treatment planning, as it has revealed significant findings, which are not visible clinically [16].

Material and Methods

The present study was investigated on 263 panoramic radiographs (PRs), collected retrospectively for Libyan completely edentulous patients (in one or both jaws). PRs were requested according to preprosthetic purpose. These cases were collected from outpatient Alferdos Dental Clinic, Tripoli, Libya. Cases were collected in the period from July 2019 to June 2020.

Personal history: age, sex and site were registered. Clinically, all patients were asymptomatic. A panoramic machine (Kodak 8000 Digital Panoramic Machine, Cares team Health, Inc. Rochester, NY, USA) with 60 - 85 kVp and 10 mA, with total filtration of 2.5 mm aluminum has been used for all PRs. The sampled PRs were examined on x-ray viewer and evaluated by three oral and maxillofacial radiologists and one oral and maxillofacial surgeon, for detection of any pathologic conditions such as radiopaque areas that could be retained roots, impacted teeth, or foreign body. While radiolucent areas that could be cystic lesions, tumors or any bony defect.

Biopsy and laboratory investigation was performed when necessary. The collected data were tabulated and analyzed using Microsoft Excel (Microsoft Office 2013). The collected data were analyzed using SPSS® 21 (IBM, USA) to describe the quantitative data, mean and standard deviation were used, and to describe the qualitative data, the cross tabulation tables, bar and pie charts were used. To analyze the collected data, Chi-Square analysis test was applied. A *p*-value less than 0.05 was considered significant.

Results

A total sample of 263 patients visited Alferdos Dental Clinic, Tripoli, Libya, within the study period, were surveyed. The entire PR study subjects with pathologic conditions were 73 (27.8%), while with no pathologic conditions were 190 patients (72.2%). The age range of patients was 34-90 years with a mean age of 62.5 (\pm 10.3) (Table 1).

The effect of age on presence or absence of pathologic conditions was not statistically significant among different age groups (*p* = 0.8). Nevertheless, there was a higher frequency of pathologic conditions in the age group 60-69 years (Table 2).

The most frequent pathologic findings seen in the total study sample were residual cysts 33 (12.5%), impacted third molars 16 (6.1%), remaining roots 15 (5.7%), impacted canines 6 (2.3%), osteoporosis 2 (0.8%) and odontome 1 (0.4%) (Fig.1 and Fig. 2 a - f) (Table 3). With statistical difference (*p* <0.001).

Pathological radiographic findings were more among females 47 (31.3%).

Residual cysts in 28 cases (18.7%) were in females, and 5 cases (4.4%) were males, with nearly, male to female ratio of 1:5.6. Impacted third molars in 8 cases (5.3%) were in females, and 8 cases (7.1%) in males, with nearly male to female ratio is 1:1. Remaining roots in 6 cases (4%) were in females, and 9 cases (8%) were in males, with nearly male to female ratio is 1.5:1. Impacted canines in 4 cases (2.7%) were in females and 2 cases (1.8%) were in males, with nearly male to female ratio is 1:2. Regarding osteoporosis no cases were seen in females (0.0%) while 2 cases (1.8%) were in males. Odontome in only one case (0.7%) was in a female and no cases were found in males (0.0%), (Fig.3) Table 4. There was statistical difference between female and male patients (*p* =0.003).

Regarding to the site, the pathologic conditions in the maxilla and mandible was 31 (23%) and 40 (41%), respectively with statistical significant difference (*p* < 0.001) (Table 5).

The most pathologic conditions found in the mandible, were residual cysts 21 (63.6%), remaining roots 14 (93.3%), impacted third molars 3 (18.8%), osteoporosis 2 (100%), while impacted canines and / or odontomes no cases were seen in the mandible (0.0%) (Fig.4) (Table 6). The pathologic conditions were significantly associated with the mandible (*p*< 0.001).

Statistical result

A chi-square goodness of fit test was calculated comparing the occurrence of pathologic conditions (absence or presence) in Libyan edentulous patients with the hypothesized occurrence of 10%. Significant deviation from the hypothesized values was found (χ^2 (1) = 92.1, *p* < .0001). The observed percentage for the presence of pathologic conditions in a Libyan population (28%) was significantly higher than the assumed percentage of occurrence (10%) in total study sample.

Discussion

This study aimed to explain and confirm the necessary need for pre-prosthetic panoramic radiography screening of completely edentulous patients.

PRs play an important role in the diagnosis and treatment planning of a wide range of dental and maxillofacial diseases and conditions [17].

In this study, a total sample of 263 patients, significant PR findings were 37 (27.8 %) condition, where the most significant findings were similar to other studies, as follows.

Regarding the age group, the mean age of all patients was 62.5 (\pm 10.3) with a range of 34-90 years. It was observed that there was no significant differences between males' and females' age *p*=0.8. The age groups among the patients with a higher frequency of pathologic conditions seen in the age group between 60-69 years.

This finding was similar to the study reported by Jindal, *et al.*, (2011) [18] who did a work on Indian population sample of 525, and reported that the mean age of the patients was 85.4 years (with standard deviation of \pm 10.4 and a range of 30-90 years. Whereas, it was inconsistent with Numan, *et al.*, (2015), [19] who reported that the most pathologic findings were in the 45-60 years, mean of 63.8.

This was in a sample of 200 patients, where 96 positive findings were found.

Retained root fragments followed by impacted teeth and residual cysts are the most frequent significant radiographic findings in edentulous patients. (3) In the present study, residual cysts presented the most frequent pathology followed

by impacted third molars and remaining roots, that was consistent with Tsvetanov, (2016) [20]. The author stated that the residual cysts were the most common cysts of the jaw. Fadi and Jean, (2020) [21], reported that residual cysts are the most expected presentation of cystic lesions in edentulous jaws of elderly patients. This was in disagreement to Jindal, *et al.*, (2011) [18] and Taha, *et al.*, (2015) [7].

The presence of residual cyst with active growth patterns can become destructive and affect the prosthetic rehabilitation thus surgical intervention is indicated.

In the present study, the number of radiographic pathologic conditions in females was higher than that in males with statistically significant difference, 47 (31.3%) in females and 26 (23%) were in males. This finding was in agreement with a study conducted by Edgerton and Clark, (1991) [22], where the findings were more common among females.

Also consistent with study done by Numan, *et al.*, (2015) [19], who reported that radiological findings in edentulous patients were found in 48% (where 56.03% in females, and 39, 28% in males). On the other hand, this was inconsistent with data by Taha, *et al.*, (2015) [7] where significant radiographic findings 125 (49%) were in females and 131 (51%) in males (the total sample was 256 patents). In general, the mandible is known to develop a wide spectrum of pathologies [23] where radiolucent and radiopaque lesions were more common in the mandible [24].

This fact was confirmed in the present study, as the mandible was more commonly involved than the maxilla. Various pathologic conditions were 31 (23%) in the maxilla, and 40 (41%) in the mandible.

This was consistent with Edgerton and Clark, (1991) [22] who stated that radiopaque and radiolucent lesions were more frequently found in the mandible.

Also coincided with Araujo, *et al.*, (2016) [25] who reported that the mandible was affected more frequently (71.43%) than the maxilla (28.57%) in a sample of 450 patients detected in 131 positive findings. Whereas, this was inconsistent with Tronje, *et al.*, (1980) [26] who recorded 84 positive findings in 178 patients with a total of 272 edentulous jaws. There were 0.38 findings in maxilla and 0.17 in mandible.

Table 1: Frequency and distribution of different age groups in the study sample:

Age groups	Frequency	Percent
<40	4	1.5
40-49	21	8.0
50-59	82	31.2
60-69	84	31.9
70-79	56	21.3
>79	16	6.1
Total	263	100.0

Table 2: Presence or absence of pathologic conditions in different age groups:

Age groups	Number & Percentage	Pathological condition		Total
		absence	presence	
< 40	n	4	0	4
	%	100.0%	0.0%	100.0%
40-49	n	17	4	21
	(%)	81.0%	19.0%	100.0%
50-59	n	60	22	82
	(%)	73.2%	26.8%	100.0%
60-69	n	57	27	84
	(%)	67.9%	32.1%	100.0%
70-79	n	40	16	56
	(%)	71.4%	28.6%	100.0%
> 79	n	12	4	16
	(%)	75.0%	25.0%	100.0%
Total	n	190	73	263
	(%)	72.2%	27.8%	100.0%

Table 3: Frequency of the most common radiographic pathologic conditions in the study population:

Pathological conditions	Frequency	Percentage
Absence	190	72.2
Residual Cyst	33	12.5
Impacted third molar	16	6.1
Remaining roots	15	5.7
Impacted canine	6	2.3
Osteoporosis	2	0.8
Odontome	1	0.4
Total	263	100.0

Table 4: Frequency and distribution of radiographic pathologic conditions in accordance to gender:

Gender	Number & percentage	Pathologic conditions							Total
		No pathological conditions	Residual cysts	Impacted third molars	Remaining roots	Impacted canines	Osteoporosis	Odontome	
Female	n	103	28	8	6	4	0	1	150
	(%)	68.7%	18.7%	5.3%	4.0%	2.7%	0.0%	0.7%	100.0%
Male	n	87	5	8	9	2	2	0	113
	(%)	77.0%	4.4%	7.1%	8.0%	1.8%	1.8%	0.0%	100.0%
Total	n	190	33	16	15	6	2	1	263
	(%)	72.2%	12.5%	6.1%	5.7%	2.3%	0.8%	0.4%	100.0%

Table 5: Distribution of evaluated radiographic pathologic conditions according to either jaw

site	Number & percentage	Pathologic conditions		Total
		No	Yes	
Both	n	28	2	30
	(%)	93.3%	6.7%	100.0%
Maxilla	n	104	31	135
	(%)	77.0%	23.0%	100.0%
Mandible	n	58	40	98
	(%)	59.2%	40.8%	100.0%
Total	n	190	73	263
	(%)	72.2%	27.8%	100.0%

Table 1: Association of the type of pathologic conditions with their site in either mandibular or maxillary jaws

Pathological conditions	Number & percentage	Jaw			Total
		Both	Maxilla	Mandible	
Absence	<i>n</i>	28	104	58	190
	(%)	14.7%	54.7%	30.5%	100.0%
Residual cysts	<i>n</i>	1	11	21	33
	(%)	3.0%	33.3%	63.6%	100.0%
Impacted third molars	<i>n</i>	1	12	3	16
	(%)	6.3%	75.0%	18.8%	100.0%
Remaining roots	<i>n</i>	0	1	14	15
	(%)	0.0%	6.7%	93.3%	100.0%
Impacted canines	<i>n</i>	0	6	0	6
	(%)	0.0%	100.0%	0.0%	100.0%
Osteoporosis	<i>n</i>	0	0	2	2
	(%)	0.0%	0.0%	100.0%	100.0%
Odontome	<i>n</i>	0	1	0	1
	(%)	0.0%	100.0%	0.0%	100.0%
Total	<i>n</i>	30	135	98	263
	(%)	11.4%	51.3%	37.3%	100.0%

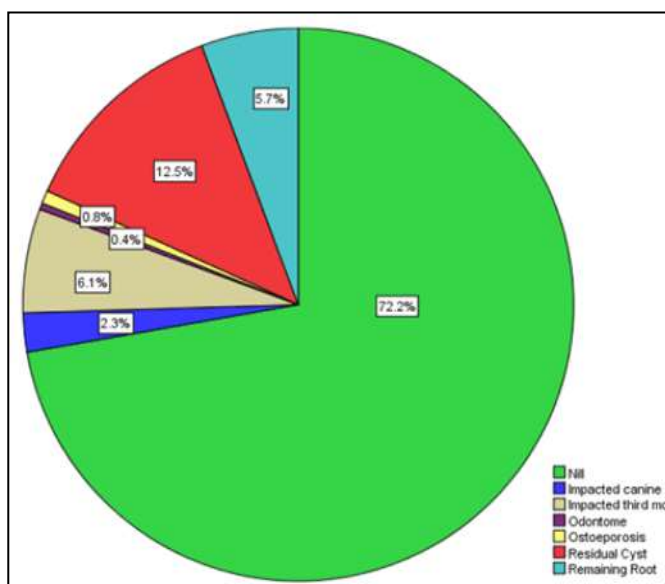


Fig.1 Pie chart representing the percentage of presence and absence of radiographic pathologic conditions in the study sample.

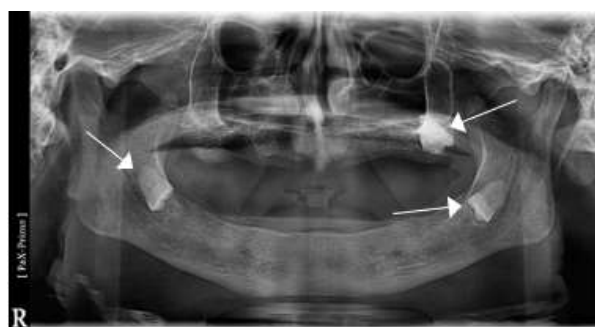


Fig. 2a Multiple impacted third molars

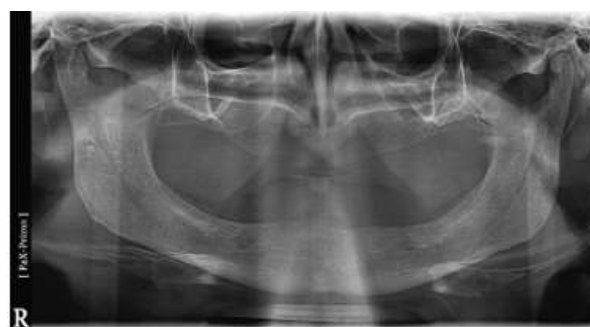

Fig. 2b Osteoporosis

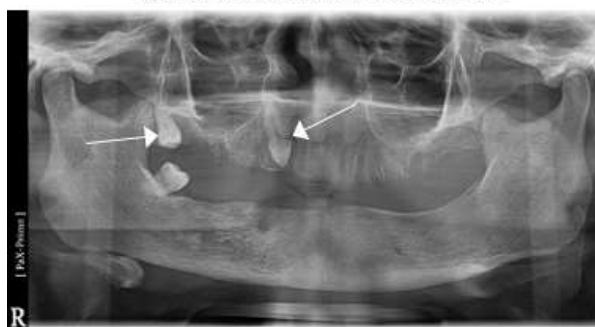

Fig. 2c: Impacted right upper canine and third molar

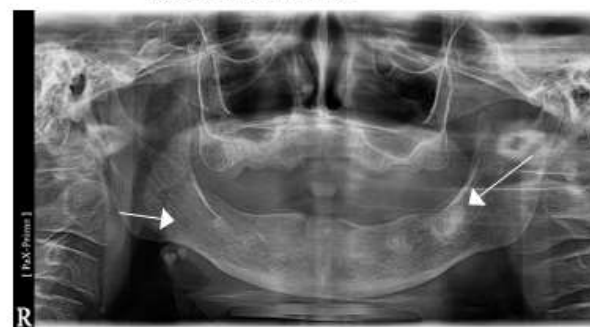


Fig. 2d Complex odontome of the left side of mandible

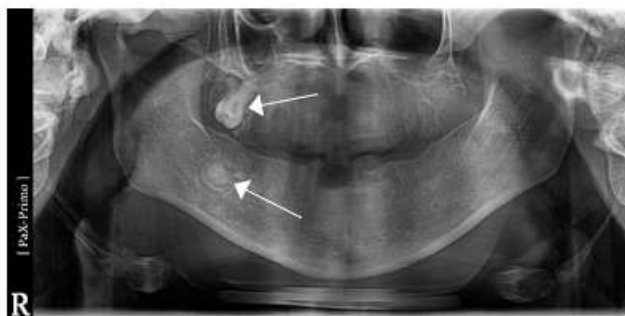


Fig. 2e: Upper right impacted third molar and complex odontome in the posterior right side of the mandible.

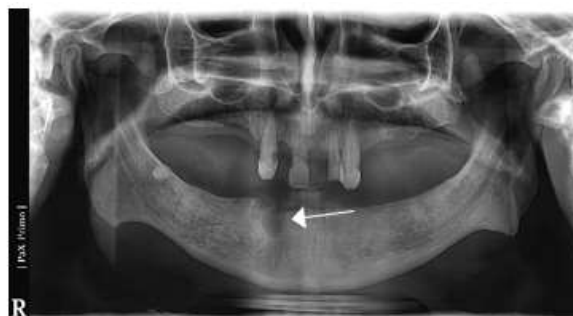

Fig. 2f: Anterior residual cyst on the right side of the mandible and posterior remaining root in the same side.

Fig 2: (a - f) PR shows the most common pathologic conditions in the study sample.

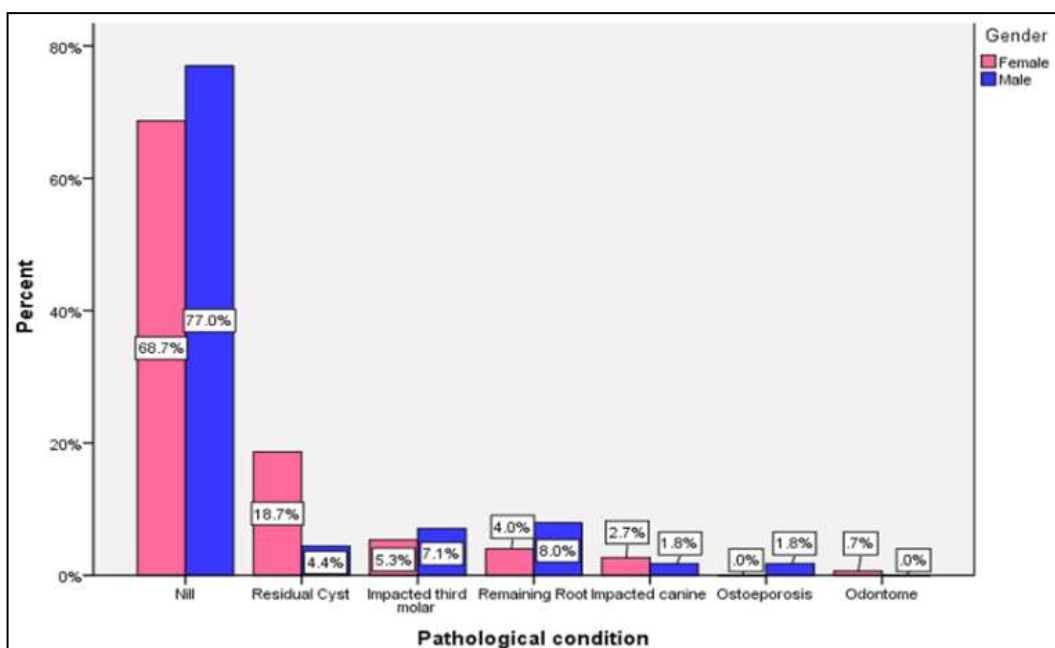


Fig 3: Bar graph showing distribution of radiographic pathologic conditions according to gender.

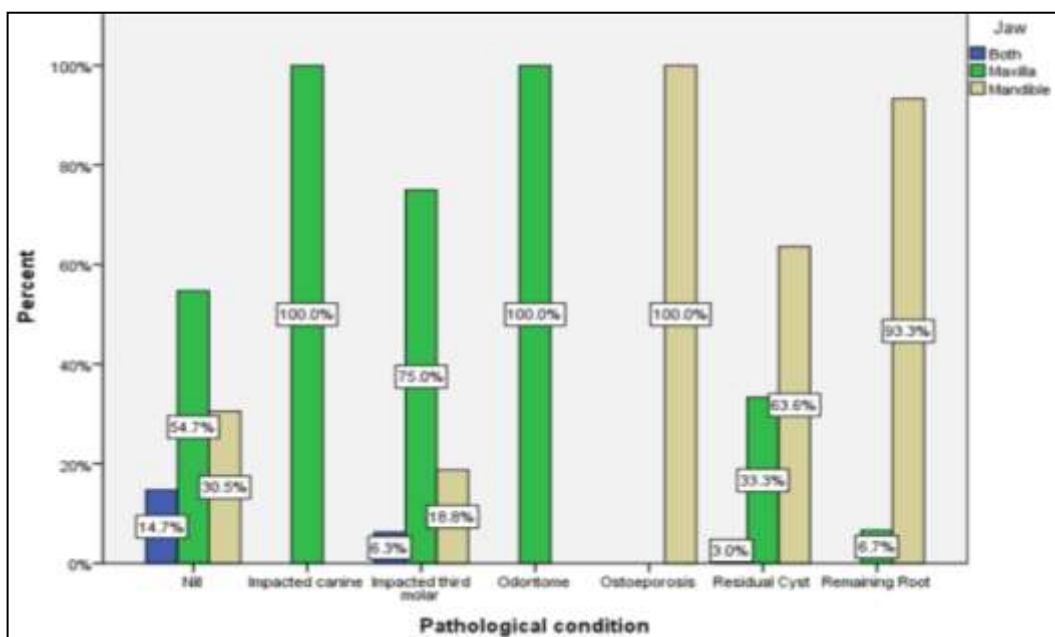


Fig 4: Bar graph demonstrating the percentage distribution of radiographic pathologic conditions according to the site in maxillary and mandibular jaws.

Conclusion

PRs are a useful accurate diagnostic tool during radiographic scanning before prosthetic denture therapy. Recently, PR has become highly recommended by many studies as a routine in many clinical dental procedures. By this study the presence of high pathological conditions in asymptomatic completely edentulous patients was revealed, following PR screening. We suggest that routine PR should be used for edentulous patients prior to prosthodontic therapy to identify asymptomatic dental conditions that requires surgical intervention. This results in successful prosthodontic rehabilitation over a long period of time.

References

1. Cek Dara Manja and Mahsa Abolmaesoomi.: Panoramic radiography assessment about difference of morphometric and position of mandibular canal in relation to gender at the age of 17-20 years. *IJADS* 2017;3(2):144-147.
2. Hoseini Zarch, *et al.* Evaluation of the accuracy of panoramic radiography in linear measurements of the jaws. *Iran J Radiol* 2011;8(2):97-102.
3. Jin-Woo Choi. Assessment of panoramic radiography as a national oral examination tool: Review of the literature. *Imaging Sci Dent* 2011;41:1-6.
4. Ladeira BDS, *et al.*: Evaluation of the panoramic image formation in different anatomic positions. *Braz Dent J* 2010;21(5):458-462.
5. Ouma DO, Ogada CN, Mutave RJ. Pathological findings on dental panoramic tomograms of edentulous patients seen at a university hospital. *J Oral Health Craniofac Sci* 2018;3:025-028.
6. Tiwari P. Use of panoramic radiographs for evaluation of maxillary and mandibular residual ridge resorption: in vitro study. *J of Evolution of Med and Dent Sci* 201;43(60):13380-13392.
7. Taha EK, *et al.* Evaluation of dental panoramic radiographic findings in edentulous jaws: A retrospective study of 743 patients "radiographic features in edentulous jaws". *J Adv Prosthodont* 2015;7:380-5.
8. Vaidya N. Radiomorphometric indices and their relation to alveolar bone loss in completely edentulous patients: A prospective study. M R Ambedkar Dental College and Hospital. MDS – Prosthodontics thesis 2009. Bangalore-India.
9. Charantimath S. *et al.*: Evaluation of edentulous patients on panoramic radiographic: a radiographic survey study. *Int J Dent Health Sci* 2017;4(1):40-48.
10. Valai-Kasim SA, *et al.* Rotational panoramic radiographs-unusual triple images. *J Clin Exp Dent* 2015; 7(1):e183-e186.
11. Al-Jabrah O. Association of type 2 diabetes mellitus with the reduction of mandibular residual ridge among edentulous patients using panoramic radiographs. *OJSt* 2011;1:61-68.
12. Nidhin J Valappila and Beena Varma.: Panoramic radiography: A review. *J Oral Medi, Surg, Pathol, Biol* 2016;1(1):21-31.
13. Benjamin Peretz, Maya Gotler, Israel Kaffe. Common errors in digital panoramic radiographs of patients with mixed dentition and patients with permanent dentition. *Inter J Dent* 2012;1:1-7.
14. Peker Alkurt, Yildirim Biçer.: Evaluation of total and partial edentulous jaws using panoramic radiography. *J Dent Fac* 2014;24(2):241-245.
15. Carla Cabral dos Santos Accioly Lins, Renan Macêdo Cutrim Tavares, Camila Caroline da Silva. Use of digital panoramic radiographs in the study of styloid process elongation. *Anat Rese Inter J* 2015;1:1-7.
16. Sachdeva SK, *et al.* Importance of radiographs in edentulous patients. *J Oral Med, Oral Surg, Oral Path and Oral Radi* 2018;4(2):64-65.
17. Bekiroglu N, *et al.* Evaluation of panoramic radiographs taken from 1. 056 Turkish children. *Niger J Clin Pract* 2015;18:8-12.
18. Jindal SK, *et al.* Significance of pre-treatment panoramic radiographic assessment of edentulous patients: A survey. *Med Oral Patol Oral Cir Bucal* 2011;16:600-606.
19. Numan D, Mustafa HA, Bekir E. Different radiological findings in turkish edentulous patients. *Oral Surg, Oral Medi, Oral Radi J* 2015;3(1):1-5.
20. Tsvetanov TS, *et al.* Residual cysts: A brief literature review. *Int J Med and Dent Sci* 2016;5(2):1341-1346.
21. Titinchi F, Morkel J. Residual cyst of the jaws: A clinico-pathologic study of this seemingly inconspicuous lesion. *PLoS ONE*. 2020;15(12):e0244250.
22. Edgerton M, Clark P. Location of abnormalities in panoramic radiographs of edentulous patients. *Oral Surg Oral Med Oral Pathol* 1991;71:106-109.
23. Vyas RR *et al.*: Malignant lesions of mandible on orthopantomogram: our experience. *J Evid Based Med.Health* 2017;4(24):1407-1413.
24. Sezgi CS, Melih O. Analysis of digital panoramic imaging findings of completely edentulous patients applying for prosthetic treatment. *Ann Med Res* 2020;27(9):2285-2291.
25. Araujo JP, *et al.* The relevance of clinical and radiographic features of jaw lesions: A prospective study. *Braz. Oral Res* 2016;30(1):1-9.
26. Tronje G, *et al.* Panoramic radiography of edentulous jaws. *Dentomaxillofac Radial J* 1980;9:21-25.