



REVIEW ARTICLE

The use of Bioceramics as root-end filling materials in periradicular surgery: A literature review



Sumaya M. Abusrewil*, William McLean, J. Alun Scott

Glasgow Dental School, School of Medicine, Dentistry and Nursing, College of Medical, Veterinary and Life Sciences, University of Glasgow, 378 Sauchiehall Street, Glasgow G2 3JZ, United Kingdom

Received 17 March 2018; revised 15 July 2018; accepted 16 July 2018
Available online 24 July 2018

KEYWORDS

Calcium silicate cement;
Root-end filling;
Mineral trioxide aggregate;
Microsurgical endodontics;
Periradicular surgery

Abstract *Introduction:* Periradicular surgery involves the placement of a root-end filling following root-end resection, to provide an apical seal to the root canal system. Historically several materials have been used in order to achieve this seal. Recently a class of materials known as Bioceramics have been adopted. The aim of this article is to provide a review of the outcomes of periradicular surgery when Bioceramic root-end filling materials are used on human permanent teeth in comparison to “traditional” materials.

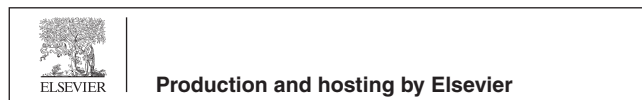
Methods & results: An electronic literature search was performed in the databases of Web of Science, PubMed and Google Scholar, between 2006 and 2017, to collect clinical studies where Bioceramic materials were utilised as retrograde filling materials, and to compare such materials with traditional materials. In this search, 1 systematic review and 14 clinical studies were identified. Of these, 8 reported the success rates of retrograde Bioceramics, and 6 compared treatment outcomes of mineral trioxide aggregate (MTA) and traditional cements when used as root-end filling materials.

Conclusion: Bioceramic root-end filling materials are shown to have success rates of 86.4–95.6% (over 1–5 years). Bioceramics has significantly higher success rates than amalgam, but they were statistically similar to intermediate restorative material (IRM) and Super ethoxybenzoic acid (Super EBA) when used as retrograde filling materials in apical surgery. However, it seems that the high success rates were not solely attributable to the type of the root-end filling materials. The surgical/microsurgical techniques and tooth prognostic factors may significantly affect treatment outcome.

© 2018 The Authors. Production and hosting by Elsevier B.V. on behalf of King Saud University. This is an open access article under the CC BY-NC-ND license (<http://creativecommons.org/licenses/by-nc-nd/4.0/>).

* Corresponding author.

Peer review under responsibility of King Saud University.



Contents

1. Introduction	274
1.1. Historical perspective	274
1.2. Bioceramic materials; classification, physical and biological properties.	275
1.3. Literature search.	277
1.3.1. Databases	277
1.3.2. Inclusion and exclusion.	277
1.4. Overview of the literature	277
1.4.1. Criteria for success and failure	277
1.4.2. Microsurgical endodontics.	277
1.4.3. Overview of the literature	277
1.5. Conclusion	280
Prisma diagram	280
Conflict of interest	280
References.	280

1. Introduction

Chemomechanical disinfection of the root canal system remains the main purpose of endodontic treatment, thereby eliminating necrotic tissues and decreasing the bacterial load (Rhodes, 2006). Although conventional treatment must always be considered first, a surgical approach, on specific occasions, can be indispensable (Carrotte, 2011). Endodontic surgery usually involves resection of the root apex, followed by preparation and filling the root end canal. The aim of the retrograde filling is to provide an apical seal to the canal, preventing egress of microorganisms and their toxins from the canal space into periradicular tissues (Gatewood, 2007). Simply cutting off the root apex and filling the canals does not accomplish this treatment goal. The real goal of endodontic surgery is to provide an impervious seal to the root canal system, eliminating bacterial contamination of the periradicular tissues and encouraging their regeneration (Torabinejad & Walton, 2009).

1.1. Historical perspective

The advancement of surgical endodontics as a treatment modality and improvement in its principles has had a long and interesting history. It has over the past 150 years emerged as a significant method of retention of sound teeth. Over time, clinical and biological directives have emerged (Gutmann, 2014). In the first half of the 20th century, the surgical principles and characteristics of surgical endodontics expanded greatly both in Europe and in America. Since that time, surgical endodontic procedures have developed continuously. Nonetheless, the most relevant of what we see related to surgical endodontics has been recorded in textbooks and publications over the last 45 years. These publications, as described by Gutmann (2014), have provided insights into amelioration of materials, techniques, hard and soft tissue management, and treatment outcomes.

Since retrograde filling materials intimately contact periradicular tissues, knowledge of the effect of such materials on the surrounding tissues is crucial. Theoretically, the root-end filling material should possess three main properties: (1) Materials that assure biocompatibility with the host tissue.

Thus, materials should be non-toxic, non-irritant, non-corrosive, not cause tissue discoloration and can stimulate regeneration of the periodontium, but at the same time, should have antimicrobial properties. (2) Materials that have the ability, to provide an impervious seal to the root canal system, and should seal all portals of communication between pulpal and periradicular tissues (Priyanka & Veronica, 2013). Accordingly, such materials should be dimensionally stable during setting, and not be soluble in the tissue fluid after placement or affected by moisture during placement. (3) Materials that help to create a less stressful clinical environment and smooth treatment procedures and make the assessment of treatment outcomes easier. Such materials should have good handling characteristics and short setting time to reduce the risk of the washing out before they set. In addition, radiopacity is an important criterion for assessing treatment outcomes.

Almost every available restorative material has been advocated as a root-end filling material at some time in dental history (Saxena et al., 2013). These include gold foil, gutta-percha (GP), amalgam, resin composite, glass ionomer, Super-ethoxy benzoic acid (Super EBA), and intermediate restorative material (IRM).

In 1846, Jackson was the first to introduce sponge (crystal or crystalline) gold as a filling material, because it was easier to condense than gold foils. In the mid-1850s, Robert Arthur introduced the adhesive gold foil by welding the pieces of sponge gold together (Glennner & Willey, 1998). In 1913, gold foil was introduced as a root-end filling material by Schuster (Vasudev et al., 2003). However, it was not practical to use gold foil routinely as a root-end filling material due to its cost, and the difficulties involved in its placement and finishing.

Around that time of introducing gold as a restorative material, in 1819, the English chemist Bell invented a mercury-based dental amalgam (*A Brief History of Amalgams*). In 1884, Farrar was the first to place amalgam as a retrograde filling, followed by Rhein in 1897 (Vasudev et al., 2003). In the past, amalgam was the root-end filling material of choice (Friedman, 1991), and a number of studies reported high success rates of amalgam used as a retrograde filling material (Marti-Bowen et al., 2004; Crosher et al., 1989). However, its potential disadvantages include: moisture sensitivity and leakage, corrosion, staining of soft/hard tissues, tendency to

scatter, the need for an undercut in the retrograde cavity preparation and mercury and tin contamination (Gartner & Dorn, 1992). So, it has become obvious that there are many biological problems associated with amalgam (Chong et al., 1997 a&b). Thus, amalgam is not anymore, the material of choice as a retrograde filling, and its use as a root-end filling can be confined to history (Chong & Pitt Ford, 2005).

In 1867, Bowman was the first to introduce Gutta-percha (GP) for obturating root canals. GP is an extract of the *Isobandra Gutta* tree; a natural inhabitant of the Malayan Archipelago (Felter & Lloyd, 2001). In 1953, Fisher found that the polymer could exist in three different crystalline structures that could be convertible to each other. These forms are termed 'alpha', 'beta' and 'gamma'. However, most commercial GP exists as 'β' form (Fisher, 1953). The use of GP as a root-end filling has received little attention in the literature. This probably is due to its porous nature resulting in microleakage. However, Amagasa et al. (1989) reported a high success rate when GP was used as a root-end filling.

Eugenol liquid is combined with zinc oxide powder to produce Zinc oxide eugenol (ZOE) cement, which is relatively weak cement that has a high solubility and poor mechanical properties. Therefore, ZOE material has been modified to Super ethoxybenzoic acid (Super EBA) and intermediate restorative material (IRM) to improve its mechanical properties. Subsequently, Hendra (1970) advocated Super-EBA as a root-end filling material because of its good sealing ability. Similarly, Bondra et al. (1989) suggested that IRM could be considered in the clinical use as a retrograde filling when IRM exhibited significantly less leakage than amalgam. Clinically, Dorn & Gartner (1990) showed that amalgam demonstrated a statistically significant reduction in success rates when compared with Super EBA and IRM. Nonetheless, these cements have also potential disadvantages such as: moisture sensitivity and solubility, tissue irritation and, difficult handling properties (Gartner & Dorn, 1992).

Composite was developed by Bowen (1962), by combining dimethacrylates (epoxy resin and methacrylic acid) with silanised quartz powder. The hydrophobic nature of composite resin prevents bonding to a wet substrate like dentine. A dentine bonding agent is required and a dry field is necessary. Although dentine bonding agent technology has improved immeasurably over the past decades (Strassler & Mann, 2011), the necessity for moisture control, to allow predictable sealing, remains. As a root-end filling, the presence of moisture during placement is almost inevitable. This may have limited the use of composite resin as a root-end filling in periapical surgery.

In 1968, polycarboxylate cement was described by Smith (Smith, 1968). This cement was developed as an improvement over the existing zinc phosphate cement; where the phosphoric acid was replaced by polyacrylic acid. One of the main advantages of this material was its ability to bond chemically to tooth substance, through the reaction of the polyacrylic acid with calcium ions in tooth structure (Negm et al., 1982). The use of polycarboxylate cement as a root-end filling has received little attention. One available leakage study showed its significant poorer sealing quality when compared to amalgam (Barry et al., 1976). In turn, replacement of zinc oxide powder with the alumina silicate glass found in silicate cement resulted in glass ionomer cement (GIC). This material was first reported by Wilson and Kent in 1971 (Wilson and Kent, 1971). The

main perceived advantages of glass ionomer cement as a filling material are; it bonds chemically to tooth substance with no need for an intermediate bonding agent, it does not contract or expand on setting and it releases fluoride. The fluoride release may or may not be important in preventing caries around the restoration. As a root-end filling, this property is probably irrelevant in any case. The main disadvantage of GIC as a root-end restoration is its solubility (Van Noort, 2013). This solubility has probably limited the use of GIC as a root-end restoration.

1.2. Bioceramic materials; classification, physical and biological properties

The introduction of Bioceramic-based materials, as a new group of dental materials, in the early 1990s may be considered as one of the most important advances in reparative dentistry. Koch and Brave (2012) define Bioceramics as "ceramic products or components employed in medical and dental applications, mainly as implants and replacements that have osteoinductive properties". A proportion of the commercial versions of this generic type of material are based on the chemistry of Portland cement. Mineral trioxide aggregate (MTA) was the first member of the calcium silicate family to be introduced (Dutta and Saunders, 2014). The initial patents for MTA were lodged in 1993 and 1995 by Torabinejad and White and were based on Portland cement. The powder of MTA consists of hydrophilic fine particles that set in the presence of water. The original patent lists the constituents as tricalcium silicate, dicalcium silicate, tricalcium aluminate and tetracalcium aluminoferrite with bismuth oxide powder added as a radiopacifying agent (Torabinejad and White 1993, 1995). Essentially the material is Portland cement and Bismuth oxide in a proportion of 4:1 (Torabinejad and White 1993). X-ray diffraction analysis revealed that MTA is not mainly composed of oxides (Torabinejad et al., 1995a). Accordingly, the term 'trioxide aggregate' is inaccurate (Camilleri, 2015). The first commercially available MTA product was 'ProRoot MTA'. It became available in the U.S. in 1999. The first formulation of the MTA was dark grey in colour and was marketed by Dentsply. The grey colour was imparted by the aluminoferrate phase of the MTA powder. This phase was, considered to be important in controlling the setting characteristics of the material (Storm et al., 2008). However, the grey colour was detrimental to the aesthetic properties of the material, and a white version followed in 2002. The many proposed uses of these materials have required the development of new formulations to facilitate improvements in the physical and chemical properties. Additionally, perceived risks associated with the presence of aluminium, arsenic and heavy metals in Portland cement necessitated the development of new family of purer calcium silicate-based cements (Camilleri, 2015). These are not based upon natural minerals or industrial processes. Thus, tricalcium silicate replaced the original formulation of the Portland cement eliminating aluminium and trace elements. These new materials were developed and are based on radiopacifier and tricalcium silicate chemistry (Camilleri, 2015), which are recognised by their bioactivity and biocompatibility (Dutta and Saunders, 2014). BioAggregate, Biodentine, Calcium enriched mixture cement (CEM), EndoSequence Root Repair Material Putty and Paste

(ERRM), and iRoot BP Plus Root Repair Material (BP-RRM) are examples of the new calcium silicate cements. Whether Bioceramic is an all-encompassing term for all Portland cement-based materials or refers only to the more modern, and purer, trisilicate materials is not agreed at present. However, it is worth mentioning that this term 'Bioceramics' is a misnomer, since Bioceramic includes a wide range of materials with different chemical compositions (Camilleri, 2015). Portland cement based materials and the new calcium silicate-based cements, used as root-end filling materials, are shown in Table 1.

MTA has been extensively studied in many in vivo and in vitro studies over the past 20 years. It has been shown that MTA, when compared to traditional retrograde filling materials has superior properties in terms of sealing ability, biocompatibility and periradicular tissue regeneration. Cell culture and cytotoxicity studies have shown its superiority to silver amalgam (Osorio et al., 1998; Zhu et al., 2000), IRM (Zhu et al., 2000), Super EBA cement (Osorio et al., 1998; Souza et al., 2006), Glass Ionomer Cement (Osorio et al., 1998; Souza et al., 2006) and gutta percha (Souza et al., 2006). In addition, many dye leakage and bacterial leakage studies have shown that MTA exhibited less leakage than amalgam, Super EBA and IRM (Torabinejad et al., 1993, 1995b; Fischer et al., 1998). Nonetheless, the reported long setting time of the original MTA formulation (2 h 45 min) (Torabinejad et al., 1995a) is a clinical concern because it may wash out before it sets (Kogan et al., 2006). Compared with other materials which have been suggested as root-end fillings, such as IRM and Super EBA cements, MTA has a significantly longer setting time (Torabinejad et al., 1995a). Another main concern, regarding MTA, is its handling properties. Mixing MTA with sterile water, results in a grainy, sandy mixture that is difficult

to deliver to the operative site, and difficult to condense adequately (Kogan et al., 2006). Of the newer Bioceramics, Biodentine is a novel Bioceramic material claimed by the manufacture (Biodentine®) to have similar mechanical properties and mechanical behaviour to human dentine, and possesses excellent sealing properties without tooth preparation. Although this material encapsulated and has a consistent mix, Biodentine is still a difficult material to use. Biodentine has a setting time of 9 min (manufacturer's value) which although favourable compared with MTA is still lengthy when compared with other restorative materials. Other calcium silicate materials have been developed to try and overcome some of the handling problems observed with Bioceramic materials. A group of putty and paste materials have become available recently. ERMM is available as a paste or putty. It has similar physical properties to MTA once set (Walsh et al., 2014) but has greatly better handling properties. Additionally, in vitro studies show comparable sealing ability of MTA and Biodentine (Bolhari et al., 2015; Saraswathi et al., 2015), ERRM (Antunes et al., 2016; Nair et al., 2011), BioAggregate (Bolhari et al., 2015), CEM (Moradi et al., 2015), and iRoot BP Plus (Leal et al., 2013). Furthermore, all Bioceramic materials are biocompatible and induce periradicular tissue regeneration in animals (Asgary et al., 2010; Chen et al., 2015; Kohout et al., 2015) and human cell differentiation (De-Deus et al., 2012; Escobar-García et al., 2016; Küçükkaya et al., 2016; Perinpanayagam and Al-Rabeah, 2009). None of these materials exhibits a critical cytotoxic profile.

However, it is well established that the validity of applying in vitro studies directly to the clinical environment is fraught with difficulties. In vitro studies cannot reflect the influences of the real clinical conditions, and cannot provide definitive determination of the clinical results, as they were performed

Table 1 The most commonly available calcium silicate-based cements for root-end filling materials.

Product/Manufacturer	Composition	Setting time
Grey ProRoot Mineral Trioxide Aggregate (G-MTA) Dentsply Tulsa Dental Specialties, Johnson City, USA	Powder: tricalcium silicate, dicalcium silicate, bismuth oxide, tricalcium aluminate, calcium sulfate dihydrate or gypsum, calcium aluminoferrite Liquid: water	165 min (Torabinejad et al., 1995a)
White ProRoot Mineral Trioxide Aggregate (W-MTA) Dentsply Tulsa Dental Specialties, Johnson City, USA	Powder: tricalcium silicate, dicalcium silicate, bismuth oxide, tricalcium aluminate, calcium sulfate dihydrate or gypsum Liquid: water	170 min (Gandolfi et al., 2009)
Calcium enriched mixture cement (CEM) Bionique Dent, Tehran, Iran	Powder: different compounds of calcium, including oxide, sulphate, phosphate, carbonate, silicate, hydroxide, and chloride compounds Liquid: water-based solution	50 min (Bhatia et al., 2015)
Biodentine Septodont, Saint-Maur-des-fossés, Cedex, France	Powder: tricalcium silicate, dicalcium silicate, calcium carbonate, zirconium oxide, calcium oxide, iron oxide Liquid: calcium chloride, a hydrosoluble (water-soluble) polymer, water.	45 min (Grech et al., 2013)
BioAggregate Innovative Bioceramic, Vancouver, Canada	Powder: tricalcium silicate, dicalcium silicate, tantalum pentoxide, calcium phosphate monobasic, amorphous silicon oxide Liquid: deionized water	1260 min (Grech et al., 2013)
EndoSequence Root Repair Material Putty and Paste (ERRM) Brasseler USA, Savannah, GA, USA	Calcium silicates, zirconium oxide, tantalum oxide, calcium phosphate monobasic and filler agents	4 h (Ma et al., 2011)
iRoot BP Plus Root Repair Material (BP-RRM) Innovative Bioceramic, Vancouver, Canada	Calcium silicates, zirconium oxide, tantalum oxide/pentoxide, calcium phosphate monobasic	2 h (The manufacturer)

under conditions that differ from those present in the actual surgical environment. In addition, the human host responses have the ability to tolerate mild inflammation. So, if mild toxicity can be neutralised by the body, there is no impact on treatment outcomes (Küçükaya et al., 2016). In addition, histocompatibility and animal studies also have limited clinical weight and present results that must be interpreted with great caution (Tang et al., 2010). Therefore, the aim of this critical review is to ascertain from the literature regarding the evidence base for whether these contemporary root-end filling materials perform better or worse than traditional retrograde materials.

1.3. Literature search

1.3.1. Databases

The electronic search was undertaken using the aforementioned keywords in the following databases: Web of Science (Core Collection), PubMed and Advanced Search (Basic Search) catalogue. The databases have been searched from 2006 up to December 2017. A Google Scholar search has also been carried out to identify any publications missed in the initial search.

1.3.2. Inclusion and exclusion

The inclusion criteria were as follow: (1) human permanent teeth indicated for root-end resection (2) randomised controlled trials (RCTs) and non-randomised trials (NRTs) that reported the success rates of Bioceramic root-end filling materials (3) RCTs and NRTs that conducted comparison between Bioceramic and traditional root-end filling materials. The exclusion criteria were as follow: (1) studies that conducted no comparison between Bioceramic and traditional retrograde materials (2) publications that reported on other indications of calcium silicate-based cements, such as perforation and resorption repairs and regenerative procedures (3) in vitro and animal clinical studies (4) case reports and case series (5) experimental calcium silicate-based materials.

1.4. Overview of the literature

1.4.1. Criteria for success and failure

The use of different outcomes criteria and the inconsistent use of the terms “success” and “failure” is one of the main causes for the variability of outcomes following endodontic treatment. These terms are ambiguous (Friedman, 2002a, 2002b). According to Friedman (2002a, 2002b), the outcomes of endodontic treatment should be classified in terms that are directly related to treatment goals such as ‘healing-disease’. For instance, when no clinical signs, symptoms or radiographic evidence of pathology are evident on follow-up examination, this is an expression of ‘healed’. The term ‘disease’ is used when the radiolucency has persisted or enlarged even when combined with clinical normalcy. ‘Healing’ which is more lenient term, can be used in cases shown to have a reduced radiolucency with clinically acceptable outcome.

There are no universal guidelines to identify which cases need to be retreated and which cases need no further intervention. Thus, teeth with persistent periapical pathosis can be evaluated by clinicians with different perspectives. This issue remains unresolved (Bergenholtz, 2016).

1.4.2. Microsurgical endodontics

Endodontic microsurgery is defined as “a surgical procedure on exceptionally small and complex structures with an operating microscope” (Kim and Kratchman, 2006; Kim et al., 2001). In the past, a carbide round bur was used for root-end resection with a 45-degree bevel. Traditionally, the aim of a steep bevel was merely to observe the root end during the surgery (Gutmann and Ford, 1993). However, this diagonal resection of the root caused significant damage, and a large osteotomy was required (Kim and Kratchman, 2006). Contemporary techniques incorporate ultrasonic devices that cut with minimum or no bevel (Tsesis et al., 2006), showed significantly better clinical results over the traditional surgical burs (de Lange et al., 2007). Alongside the use of the ultrasonic devices, the dental operating microscope is used as an aid in performing this type of surgery. This improves the precision and predictability greatly and has allowed ‘endodontic microsurgery’ to be used as a substitutional term (Kim, 1997; Kim et al., 2001).

1.4.3. Overview of the literature

Fourteen studies were included: five studies reported the outcomes of MTA (Çalışkan et al., 2016; Jing et al., 2012; Saunders, 2008; Shen et al., 2016; Wang et al., 2017), one study comparing the outcomes of MTA with BP-RRM (Zhou et al., 2017), one study reported the outcome of ERRM (Shinbori et al., 2015) and one study reported the outcome of CEM (Asgary and Ehsani, 2013). Two publications comparing the outcomes of MTA and adhesive resin composite (Retroplast) (Von Arx et al., 2010, 2014). Two studies comparing the outcomes of MTA and Super EBA (Kim et al., 2016; Song and Kim, 2012). Two publications comparing the outcomes of MTA, SuperEBA and Retroplast (Von Arx et al., 2007, 2012). In addition, one systematic review comparing the clinical outcomes of MTA with GP, amalgam and IRM. Comparison of these publications is shown in Table 2.

In the following studies a standardised surgical protocol was used to perform surgical endodontics; 2–3 mm of the root-apex was resected and, then, retro-preparation performed using ultrasonics to a depth of 3 mm, followed by placement of the root-end filling material. A prospective study by Shen et al. (2016) determined clinically and radiographically the periapical healing in 97 cases with persistent apical periodontitis that received microsurgical endodontics and a retrograde root-end filling material (white ProRoot MTA). At one year follow-up, treatment outcomes were categorised into success, failure and improvement. The surgical treatment was considered a success when bone regeneration was 90% or more combined with clinically acceptable outcome. When bone regeneration was between 50% and 90% with absence of clinical signs/symptoms, the treatment was considered as an improvement. The surgery was considered a failure when bone regeneration was less than 50% with the presence of clinical symptoms. In this study, success was apparent in 57.7% of the patients, improvement in 35.1% of the cases, whereas failures presented in only 7.2% of the patients. The outcomes of the second group were considered successful. Thus, the overall success was achieved in 92.8% of the patients (90 cases). In contrast, only 7 cases were classified as failures (7.2%). These results were consistent with the success rates reported by Jing et al. (2012), who included only 54 cases. However, both studies reported no

Table 2 Study reported treatment outcomes of periradicular surgery with various retrograde filling materials.

Authors	Year	Study design	Number of teeth	Root-end filling material	Follow-up observation	Overall success rate
Asgary and Ehsani	2013	Prospective study	13	Calcium enriched mixture (CEM)	1.5 years	93%
Çalışkan et al.	2016	Clinical study	90	ProRoot MTA	2–6 years	80%
Jing et al.	2012	Clinical study	54	MTA	1 year	92.6%
Kim et al.	2016	Randomised controlled study	182	MTA and Super EBA	4 years	91.6% and 89.9% respectively
Saunders	2008	Prospective study	276	ProRoot White MTA	3 years	88.8%
Shen et al.	2016	Prospective study	97	MTA	1 year	92.8%
Shinbori et al.	2015	Retrospective study	113	EndoSequence BC Root Repair (ERRM)	1 year	92%
Song and Kim	2012	Prospective randomised controlled study	192	MTA and Super EBA	1 year	95.6% and 93.1% respectively
Von Arx et al.	2010	Prospective study	353	ProRoot MTA and Retroplast	1 year	91.3% and 79.5% respectively
	2014		271		5 years	92.5% and 76.6% respectively
Von Arx et al.	2007	Cohort study	191	ProRoot MTA, SuperEBA or Retroplast	1 year	90.2%, 76.4% and 84.7% respectively
	2012		170		5 years	(86.4%), 67.3% and 75.3% respectively
Wang et al.	2017	Prospective cohort study	74	ProRoot MTA	1–2.5 years	90.5%
Zhou et al.	2017	Prospective randomised controlled study	158	MTA and iRoot BP Plus Root Repair Material (BP-RRM).	1 year	93.1% and 94.4%, respectively

statistically significant differences in treatment outcomes according to sex and age of the patients, but a significant relationship was found in [Shen's et al. \(2016\)](#) study between the size and type of lesion and prognosis. The worst prognoses were present with larger lesions and cysts. In contrast, [Jing et al. \(2012\)](#) found no significant differences between the size/type of the lesion and prognosis. However, it should be noted that the statistical analysis performed by [Shen et al. \(2016\)](#), regarding the significant prognostic factors, might be inappropriate because of the small sample size of cases with cysts being identified histologically. Granulomas and cysts were identified histologically in 71 (73.2%) and only 12 (12.4%) teeth respectively, and to compound this, the pathological status of 14 (14.4%) cases were not specified.

Another clinical study ([Çalışkan et al., 2016](#)) evaluated the success rates in 90 teeth that received a retrograde filling material (ProRoot MTA). Over a two and six year follow-up period, the outcomes were judged as healed (complete healing of the former radiographic rarefaction or incomplete healing 'scar tissue' and absence of clinical signs/symptoms) which accounted for 80% of cases, non-healed presented in 14.4% (no reduction or even enlargement of the former rarefaction, or the presence of clinical signs or symptoms), and uncertain in 5.6% (clinical normalcy with some reduction of the former radiolucency). In this study, the presence of either a granuloma or a cyst did not significantly influence the outcomes of treatment. In addition, the 'uncertain' group was not included in the overall success. The outcomes were also evaluated in [Saunders's \(2008\)](#) prospective study, performed in 276 teeth, into complete healing (59%) of teeth, uncertain healing (29.7%) and non-healing (11.2%). 1% of cases (3 teeth) of non-healing group showed persistent pain despite evidence of complete radiographic healing. This study demonstrated an

overall success rate of 88.8% when ProRoot White MTA was used as a retrograde filling, including all teeth with no clinical symptoms (complete healing and uncertain healing). [Wang et al. \(2017\)](#) performed microsurgical endodontics on 98 teeth in their prospective cohort study, using retrograde ProRoot MTA. Only 74 of 98 were followed up. 3/74 had been extracted, two for root fracture and one for periodontal reasons. 71 teeth were analysed clinically and radiographically. [Wang et al. \(2017\)](#) classified treatment outcomes according to radiographic findings into complete healing (complete bone repair), incomplete healing (scar tissue), uncertain healing and unsatisfactory healing (non-healed). Of the 74 teeth, 55 (74.3%) demonstrated complete healing, 12 (16.2%) showed incomplete healing. Together, 67 (90.5%) were clinically normal. Three (4.1%) were observed with uncertain healing, one of which was symptomatic with swelling and sinus tract and it was considered an uncertain, not a failure. Unsatisfactory healing was observed in the remaining one tooth (1.4%). This study demonstrated that the use of the treated tooth as an abutment may have a negative impact on treatment outcome.

Another retrospective study performed by [Shinbori et al. \(2015\)](#) also evaluated the clinical and radiographic healing outcomes, at one year observation, when EndoSequence Root Repair (ERRM) was used as the root-end filling material, in 113 teeth of 94 patients. The outcomes were classified on, the basis of, clinical and radiographic findings, into success (healed and healing), and failure (non-healing). In this retrospective study, 92.0% of teeth classified as having a successful outcome. Additionally, none of the prognostic factors had any significant effects on treatment outcomes. These included age, sex, tooth position, lesion size, presence of a sinus tract, preoperative symptoms, and orthograde retreatment previous to the surgery. Calcium-enriched mixture (CEM) was used by

Asgary and Ehsani (2013) in their prospective study as a root-end filling in 14 teeth. Complete healing of periradicular lesions were observed clinically and radiographically in 13 teeth (93% success) during a mean time of 1.5 years. A prospective randomised controlled study was performed by Zhou et al. (2017) to evaluate the outcomes of endodontic microsurgery when using iRoot BP Plus Root Repair Material (BP-RRM) or MTA as root-end filling materials of a total of 158 teeth. In this study, 87 teeth received retrograde MTA, whilst 71 teeth were root-end filled with BP-RRM. At the 12-month follow-up, the outcomes were categorised, according to clinical and radiographic findings, as complete healing, incomplete healing and unsatisfactory healing. The success rates of endodontic microsurgery for MTA and BP-RRM groups (complete and incomplete healing) were 93.1% and 94.4%, respectively with no significant differences. In addition, tooth type, quality of root filling and size of the lesion had significant effects on the outcomes. Whereas none of predictors, including sex, age, presence or absence of crown or alveolar dehiscence had significant influences on the clinical outcomes.

A non-randomised prospective study by Von Arx et al. (2010) reported results of two different root-end fillings; ProRoot MTA, and adhesive resin composite (Retroplast). In this study, 353 cases were included. 178 of which received root-end preparation, and filled with ProRoot MTA, whilst 175 cases received a shallow retrograde cavity and filled with Retroplast (Retroplast; Retroplast Trading, Rorvig, Denmark). Patients were recalled after 1 year. The results demonstrated that MTA-treated teeth had a significantly higher rate of success (91.3%) than those treated with adhesive resin composite (Retroplast) (79.5%). According to the authors, the significant differences in outcomes might also be associated with the root-end preparation techniques where a shallow concavity of about 1-mm depth was prepared for Retroplast, and therefore not solely associated with the type of the retrograde filling. This shallow preparation brings with it the risk of missing accessory canals, isthmuses or ramifications. In addition, because an adhesive system was used for Retroplast, inadequate control of haemorrhage during the surgery, or insufficient dentine at the cut root surface, might result in compromised bonding and sealing of the materials and, ultimately, healing. Subsequently, Von Arx et al. (2014) followed up 271 cases of the previous study up to 5 years. After 5-year follow up, the overall of healed cases was 92.5% for MTA and 76.6% for Retroplast, with a significant difference (Von Arx et al., 2014), which is in line with previously published 1-year outcomes. However, the results of Von Arx's et al., 2014 study should be interpreted carefully due to the loss to follow-up (82 cases).

Two randomised controlled studies evaluated the clinical outcomes of endodontic microsurgery when MTA and Super EBA were used as root-end fillings. The statistical analysis of the results showed no significant difference of retrograde MTA and Super EBA. The success rates for MTA and Super EBA were 91.6% and 89.9% respectively in the four-year success rates (Kim et al., 2016), and 95.6% for MTA and 93.1% for Super EBA in the one-year success rates (Song and Kim, 2012). In contrast, Von Arx et al. (2007) assessed the outcomes of microsurgical endodontics at 1-year follow-up, in 191 teeth, after root-end fillings with three different materials; ProRoot MTA, SuperEBA or Retroplast. The success rates for the three materials were 90.2%, 76.4% and 84.7% respectively. In this

study, two other predictors reached statistical significance in affecting prognosis. These were larger lesion size, and postoperative complications. After five years, Von Arx et al. (2012) performed a 5-year longitudinal cohort assessment of the healing rate in 170 teeth of which, after root-end fillings. The success rate for ProRoot MTA was also significantly higher (86.4%) than with SuperEBA (67.3%). Retroplast showed 75.3% success rate. This study also suggested that the prognosis was significantly affected by the mesial-distal bone levels at the treated tooth. In addition, this study showed that the 5-year outcome of endodontic microsurgery was 8% poorer than the 1-year prognosis.

Most importantly, a systematic review and meta-analysis by Tang et al. (2010) also concluded; MTA as a root-end filling is similar to IRM (RR 0.62; 95% CI 0.34–1.16), but is significantly superior to amalgam (RR 0.35; 95% CI 0.13–0.94) and gutta percha (96% Vs 52%, RR 0.08; 95% CI 0.01–0.57). In this systematic review, the authors included only one study (Christiansen et al., 2009) comparing healing after root-end resection with retrorade MTA or with orthograde gutta-percha root filling. In Christiansen's et al. (2009) randomised clinical trial, a root-end cavity was not prepared after root-end resection in teeth allocated to orthograde gutta percha root filling. This trial could better be interpreted as teeth treated with MTA root-end fillings had a significantly higher healing rate (96%) than teeth without retrograde fillings (52%).

The majority of the clinical studies, described within this review, were prospective with the lack of control groups. The lack of control groups is not ideal in these circumstances. Only one systematic review was identified and no study was identified comparing the outcomes of retrograde calcium silicate-based cements, other than MTA, and the traditional root-end filling materials. The studies showed high success rates when Bioceramic materials were used as root-end fillings. In the systematic review, MTA showed significantly higher success rates than amalgam and gutta-percha, but no significant difference was found when compared to IRM. In addition, MTA demonstrated a significantly higher success rate, when compared with dentine-bonded resin composite (Retroplast) in non-randomised studies. In contrast, randomised controlled studies showed no significant difference between MTA and Super EBA. Consequently, no significant differences were found in treatment outcomes, when Super EBA and IRM were used in conjunction with microsurgical protocol.

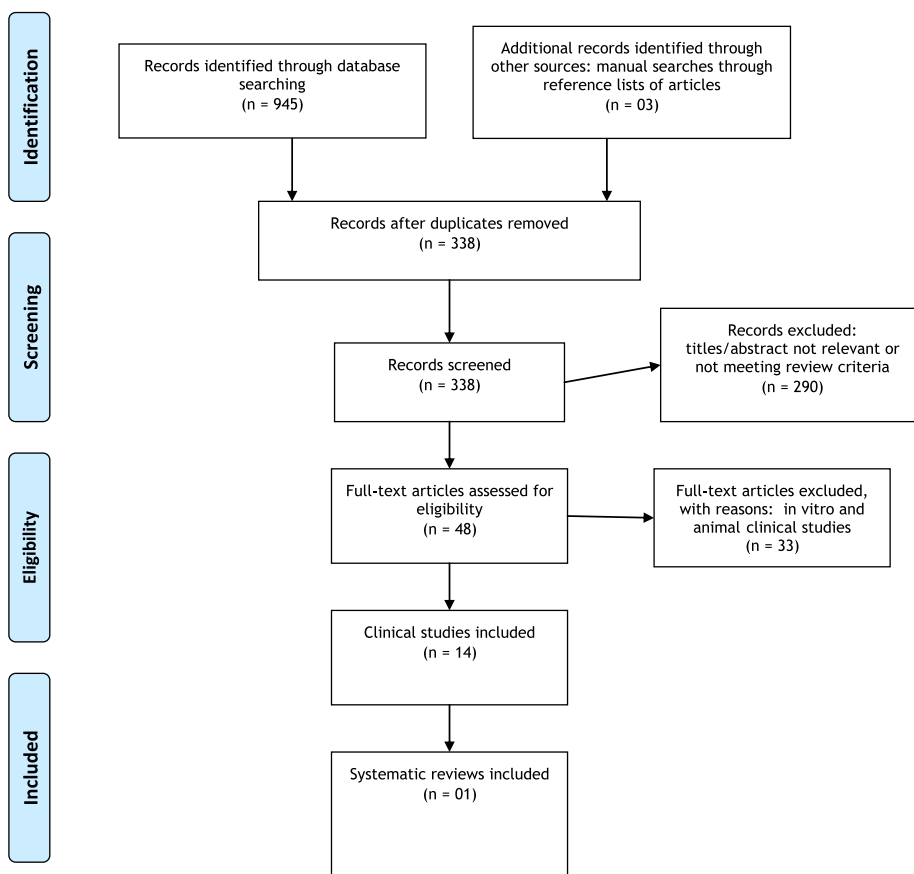
The development of surgical endodontics into endodontic microsurgery has led to improved precision and has significantly improved treatment outcomes, since endodontic surgical procedures are performed on exceptionally small and complex structures. These high success rates of endodontic microsurgery, combined with the use of high-power magnification, have been reported in meta-analyses (Setzer et al., 2010, 2012). Thus, it is obvious that the cause of surgical failures or successes is not solely associated with the type of root-end filling materials. In fact, three main factors may contribute greatly to treatment outcomes. First, the ability to eliminate lateral canals and apical ramifications, which cannot be debrided and cleaned, by orthograde means. This can be achieved by not only the dexterity and skill of the clinicians, but also by the contemporary tools and equipment that help to inspect the surgical field, and enable thorough cleaning and preparation of retrograde cavities. Second, the various tooth prognostic

factors, since it has been shown that the larger lesions and cysts were significantly influential in determining poorer prognoses. However, other clinical studies found that lesion size/type or tooth type had no significant effects on treatment outcomes. Lastly, placing a retrograde filling that fulfils all or most of the properties of an ideal root-end filling material can contribute to treatment outcomes. An opportunity exists, therefore, for well-controlled randomised clinical studies to confirm or refute these results.

1.5. Conclusion

Bioceramics, Super ethoxybenzoic acid (Super EBA) and intermediate restorative material (IRM) are shown to be successful root-end filling materials. Nevertheless, adequately powered randomised controlled clinical trials that provide a high level of evidence need to be undertaken to confirm their efficacy.

Prisma diagram



Conflict of interest

The authors declare that there is NO conflict of interest in the subject matter or materials discussed in this manuscript.

References

A Brief History of Amalgams - Tooth by The Lake. <http://www.toothbythelake.net/.../amalgam-fillings/a-brief-history-of-amalgam>.

Biodentine® - Dentin Restoration category - Septodont. <http://www.septodontusa.com/products/biodentine>.

Amagasa, T., Nagase, M., Sato, T., Shioda, S., 1989. Apicoectomy with retrograde gutta-percha root filling. *Oral Surg., Oral Med., Oral Pathol.* 68 (3), 339–342.

Antunes, H., Gominho, L., Andrade-Junior, C., Dessaune-Neto, N., Alves, F., Rôças, I., Siqueira, J., 2016. Sealing ability of two root-end filling materials in a bacterial nutrient leakage model. *Int. Endod. J.* 49 (10), 960–965.

- Asgary, S., Eghbal, M.J., Ehsani, S., 2010. Periradicular regeneration after endodontic surgery with calcium-enriched mixture cement in dogs. *J. Endod.* 36 (5), 837–841.
- Asgary, S., Ehsani, S., 2013. Periradicular surgery of human permanent teeth with calcium-enriched mixture cement. *Iranian Endod. J.* 8 (3), 140–144.
- Barry, G.N., Selbst, A.G., D'Anton, E.W., Madden, R.M., 1976. Sealing quality of polycarboxylate cements when compared to amalgam as retrofilling material. *Oral Surg., Oral Med., Oral Pathol.* 42 (1), 109–116.
- Bergenholtz, G., 2016. Assessment of treatment failure in endodontic therapy. *J. Oral Rehabil.* 43 (10), 753–758.
- Bhatia, C., Chandak, M., Adwani, D., Chandak, R., Rahul, A., 2015. Calcium enriched mixture cement. *Dent. Health Sci.* 2 (4), 905–910.
- Bolhari, B., Yazdi, K.A., Sharifi, F., Pirmoazen, S., 2015. Comparative scanning electron microscopic study of the marginal adaptation of four root-end filling materials in presence and absence of blood. *J. Dentistry (Tehran, Iran)* 12 (3), 226.
- Bondra, D.L., Hartwell, G.R., MacPherson, M.G., Portell, F.R., 1989. Leakage in vitro with IRM, high copper amalgam, and EBA cement as retrofilling materials. *J. Endod.* 15 (4), 157–160.
- Bowen, R.L., 1962. Dental filling material comprising vinyl silane treated fused silica and a binder consisting of the reaction product of bis phenol and glycidyl acrylate. Google Patents.
- Çalışkan, M., Tekin, U., Kaval, M., Solmaz, M., 2016. The outcome of apical microsurgery using MTA as the root-end filling material: 2-to 6-year follow-up study. *Int. Endod. J.* 49 (3), 245–254.
- Camilleri, J., 2015. Mineral trioxide aggregate: present and future developments. *Endod. Top.* 32 (1), 31–46.
- Carrotte, P., 2011. A clinical guide to endodontics. *British Dent. Assoc.*, 80–84
- Chen, I., Karabucak, B., Wang, C., Wang, H.-G., Koyama, E., Kohli, M.R., Nah, H.-D., Kim, S., 2015. Healing after root-end microsurgery by using mineral trioxide aggregate and a new calcium silicate-based bioceramic material as root-end filling materials in dogs. *J. Endod.* 41 (3), 389–399.
- Chong, B., Pitt Ford, T., Kariyawasam, S., 1997a. Short-term tissue response to potential root-end filling materials in infected root canals. *Int. Endod. J.* 30 (4), 240–249.
- Chong, B., Pitt Ford, T., Kariyawasam, S., 1997b. Tissue response to potential root-end filling materials in infected root canals. *Int. Endod. J.* 30 (2), 102–114.
- Chong, B.S., Pitt Ford, T.R., 2005. Root-end filling materials: rationale and tissue response. *Endod. Top.* 11 (1), 114–130.
- Christiansen, R., Kirkevang, L.L., Hørsted-Bindslev, P., Wenzel, A., 2009. Randomized clinical trial of root-end resection followed by root-end filling with mineral trioxide aggregate or smoothing of the orthograde gutta-percha root filling—1-year follow-up. *Int. Endod. J.* 42 (2), 105–114.
- Crosher, R., Dinsdale, R., Holmes, A., 1989. A one visit apicectomy technique using calcium hydroxide cement as the canal filling material combined with retrograde amalgam. *Int. Endod. J.* 22 (6), 283–289.
- de Lange, J., Putters, T., Baas, E.M., van Ingen, J.M., 2007. Ultrasonic root-end preparation in apical surgery: a prospective randomized study. *Oral Surg., Oral Med., Oral Pathol., Oral Radiol., Endodontol.* 104 (6), 841–845.
- De-Deus, G., Canabarro, A., Alves, G., Marins, J., Linhares, A., Granjeiro, J., 2012. Cytocompatibility of the ready-to-use bio-ceramic putty repair cement iRoot BP Plus with primary human osteoblasts. *Int. Endod. J.* 45 (6), 508–513.
- Dorn, S.O., Gartner, A.H., 1990. Retrograde filling materials: a retrospective success-failure study of amalgam, EBA, and IRM. *J. Endod.* 16 (8), 391–393.
- Dutta, A., Saunders, W.P., 2014. Calcium silicate materials in endodontics. *Dent Update* 41, 708–722.
- Escobar-García, D.M., Aguirre-López, E., Méndez-González, V., Pozos-Guillén, A., 2016. Cytotoxicity and Initial Biocompatibility of Endodontic Biomaterials (MTA and Biodentine™) Used as Root-End Filling Materials. *BioMed Res. Int.*, 1–7
- Felter, H., Lloyd, J., 2001. Historical Uses of Gutta-Percha. *King's Am. Dispensatory* <http://www.endodontiamauventuri.it/Gutta-perca/Historical%20Uses%20of%20Gutta.pdf>.
- Fischer, E.J., Arens, D.E., Miller, C.H., 1998. Bacterial leakage of mineral trioxide aggregate as compared with zinc-free amalgam, intermediate restorative material, and Super-EBA as a root-end filling material. *J. Endod.* 24 (3), 176–179.
- Fisher, D., 1953. Crystal structures of gutta percha. *Proc. Phys. Soc. Section B* 66 (1), 7.
- Friedman, S., 1991. Retrograde approaches in endodontic therapy. *Dent. Traumatol.* 7 (3), 97–107.
- Friedman, S., 2002a. Considerations and concepts of case selection in the management of post-treatment endodontic disease (treatment failure). *Endod. Top.* 1 (1), 54–78.
- Friedman, S., 2002b. Prognosis of initial endodontic therapy. *Endod. Top.* 2 (1), 59–88.
- Gandolfi, M.G., Iacono, F., Agee, K., Siboni, F., Tay, F., Pashley, D. H., Prati, C., 2009. Setting time and expansion in different soaking media of experimental accelerated calcium-silicate cements and ProRoot MTA. *Oral Surg. Oral Med. Oral Pathol. Oral Radiol. Endod.* 108 (6), e39–e45.
- Gartner, A., Dorn, S., 1992. Advances in endodontic surgery. *Dent. Clin. North Am.* 36 (2), 357–378.
- Gatewood, R.S., 2007. Endodontic materials. *Dent. Clin. North Am.* 51 (3), 695–712.
- Glenner, R.A., Willey, P., 1998. Dental filling materials in the Confederacy. *J. History Dentistry* 46 (2), 71–75.
- Grech, L., Mallia, B., Camilleri, J., 2013. Investigation of the physical properties of tricalcium silicate cement-based root-end filling materials. *Dent. Mater.* 29 (2), e20–e28.
- Gutmann, J., Ford, T.P., 1993. Management of the resected root end: a clinical review. *Int. Endod. J.* 26 (5), 273–383.
- Gutmann, J.L., 2014. Surgical endodontics: past, present, and future. *Endod. Top.* 30 (1), 29–43.
- Hendra, L.P., 1970. EBA cement. A practical system for all cementation. *Int. Endod. J.* 4 (2), 28–31.
- Jing, S., Haifeng, Z., Shufeng, J., Ningning, L., Jianrong, F., 2012. One year evaluation of endodontic microsurgery in 54 cases with persistent apical periodontitis. *West China J. Stomatol.* 30 (4), 388–392.
- Kim, S., 1997. Principles of endodontic microsurgery. *Dent. Clin. North Am.* 41 (3), 481–497.
- Kim, S.G., Pecora, G., Rubinstein, R., 2001. Color atlas of microsurgery in endodontics. *WB Saunders Company*, 13. pp. 3–5.
- Kim, S., Kratchman, S., 2006. Modern endodontic surgery concepts and practice: a review. *J. Endod.* 32 (7), 601–623.
- Kim, S., Song, M., Shin, S.-J., Kim, E., 2016. A randomized controlled study of mineral trioxide aggregate and super ethoxybenzoic acid as root-end filling materials in endodontic microsurgery: long-term outcomes. *J. Endod.* 42 (7), 997–1002.
- Koch, K.A., Brave, D.G., 2012. Bioceramics, part 1: the clinician's viewpoint. *Dent Today* 31 (1), 130–135.
- Kogan, P., He, J., Glickman, G.N., Watanabe, I., 2006. The effects of various additives on setting properties of MTA. *J. Endod.* 32 (6), 569–572.
- Kohout, G.D., He, J., Primus, C.M., Opperman, L.A., Woodmansey, K.F., 2015. Comparison of Quick-Set and Mineral Trioxide Aggregate root-end fillings for the regeneration of apical tissues in dogs. *J. Endod.* 41 (2), 248–252.
- Küçükkaya, S., Görduysus, M.Ö., Zeybek, N.D., Müftüoğlu, S.F., 2016. In vitro cytotoxicity of calcium silicate-based endodontic cement as root-end filling materials. *Scientifica* 2016, 1–5.
- Leal, F., De-Deus, G., Brandao, C., Luna, A., Souza, E., Fidel, S., 2013. Similar sealability between bioceramic putty ready-to-use repair cement and white MTA. *Brazilian Dent. J.* 24 (4), 362–366.

- Ma, J., Shen, Y., Stojcic, S., Haapasalo, M., 2011. Biocompatibility of two novel root repair materials. *J. Endod.* 37 (6), 793–798.
- Marti-Bowen, E., Penarrocha-Diago, M., García-Mira, B., 2004. Periapical surgery using the ultrasound technique and silver amalgam retrograde filling. A study of 71 teeth with 100 canals. *Medicina oral, patología oral y cirugía bucal* 10, E67–E73.
- Moradi, S., Lomee, M., Gharechahi, M., 2015. Comparison of fluid filtration and bacterial leakage techniques for evaluation of microleakage in endodontics. *Dent. Res. J.* 12 (2), 109–114.
- Nair, U., Ghattas, S., Saber, M., Natera, M., Walker, C., Pileggi, R., 2011. A comparative evaluation of the sealing ability of 2 root-end filling materials: an in vitro leakage study using *Enterococcus faecalis*. *Oral Surg., Oral Med., Oral Pathol., Oral Radiol., Endodontol.* 112 (2), e74–e77.
- Negm, M., Beech, D., Grant, A., 1982. An evaluation of mechanical and adhesive properties of polycarboxylate and glass ionomer cements. *J. Oral Rehabil.* 9 (2), 161–167.
- Osorio, R.M., Hefti, A., Vertucci, F.J., Shawley, A.L., 1998. Cytotoxicity of endodontic materials. *J. Endod.* 24 (2), 91–96.
- Perinpanayagam, H., Al-Rabeah, E., 2009. Osteoblasts interact with MTA surfaces and express Runx2. *Oral Surg., Oral Med., Oral Pathol., Oral Radiol., Endodontol.* 107 (4), 590–596.
- Priyanka, S., Veronica, A., 2013. A literature review of root-end filling materials. *IOSR J. Dent. Med. Sci.* 9 (4), 20–25.
- Rhodes, J.S., 2006. *Advanced endodontics: clinical retreatment and surgery*. CRC Press, 147–148.
- Saraswathi, D.D., Tejavath, S.K., Babu, M.R., Swetha, B., Gandhi, B., 2015. A comparative evaluation of sealing ability of three recent root-end filling materials: an in vitro study. *J. Adv. Oral Res.* 6 (2), 33–39.
- Saunders, W.P., 2008. A prospective clinical study of periradicular surgery using mineral trioxide aggregate as a root-end filling. *J. Endod.* 34 (6), 660–665.
- Saxena, P., Gupta, S.K., Newaskar, V., 2013. Biocompatibility of root-end filling materials: recent update. *Restorative Dentistry Endod.* 38 (3), 119–127.
- Setzer, F.C., Kohli, M.R., Shah, S.B., Karabucak, B., Kim, S., 2012. Outcome of endodontic surgery: a meta-analysis of the literature—part 2: comparison of endodontic microsurgical techniques with and without the use of higher magnification. *J. Endod.* 38 (1), 1–10.
- Setzer, F.C., Shah, S.B., Kohli, M.R., Karabucak, B., Kim, S., 2010. Outcome of endodontic surgery: a meta-analysis of the literature—part 1: comparison of traditional root-end surgery and endodontic microsurgery. *J. Endod.* 36 (11), 1757–1765.
- Shen, J., Zhang, H., Gao, J., Du, X., Chen, Y., Han, L., 2016. Short-term observation of clinical and radiographic results of periapical microsurgery: a prospective study. *Biomed. Res.* 27 (3), 923–928.
- Shinbori, N., Grama, A.M., Patel, Y., Woodmansey, K., He, J., 2015. Clinical outcome of endodontic microsurgery that uses EndoSequence BC root repair material as the root-end filling material. *J. Endod.* 41 (5), 607–612.
- Smith, D., 1968. A new dental cement. *Br. Dent. J.* 124 (9), 381–384.
- Song, M., Kim, E., 2012. A prospective randomized controlled study of mineral trioxide aggregate and super ethoxy-benzoic acid as root-end filling materials in endodontic microsurgery. *J. Endod.* 38 (7), 875–879.
- Souza, N.J., Justo, G.Z., Oliveira, C.R., Haun, M., Bincioletto, C., 2006. Cytotoxicity of materials used in perforation repair tested using the V79 fibroblast cell line and the granulocyte-macrophage progenitor cells. *Int. Endod. J.* 39 (1), 40–47.
- Storm, B., Eichmiller, F.C., Tordil, P.A., Goodell, G.G., 2008. Setting expansion of Grey and white mineral trioxide aggregate and Portland cement. *J. Endod.* 34 (1), 80–82.
- Strassler, H.E., Mann, M., 2011. Dental adhesives for direct placement composite restorations: an update. *Dent. Econom.* 15, 1–16.
- Tang, Y., Li, X., Yin, S., 2010. Outcomes of MTA as root-end filling in endodontic surgery: A systematic review. *Quintessence Int.* 41 (7), 557–566.
- Torabinejad, M., Hong, C., McDonald, F., Pitt-Ford, T.P., 1995a. Physical and chemical properties of a new root-end filling material. *J. Endod.* 21 (7), 349–353.
- Torabinejad, M., Rastegar, A.F., Kettering, J.D., Pitt-Ford, T.R.P., 1995b. Bacterial leakage of mineral trioxide aggregate as a root-end filling material. *J. Endod.* 21 (3), 109–112.
- Torabinejad, M., Walton, R.E., 2009. *Endodontics: Principles and Practice*. Saunders.
- Torabinejad, M., Watson, T., Ford, T.P., 1993. Sealing ability of a mineral trioxide aggregate when used as a root end filling material. *J. Endod.* 19 (12), 591–595.
- Torabinejad, M., White, D.J., 1993. Tooth filling material and method of use, US Patent: 5415547.
- Torabinejad, M., White D.J., 1995. Tooth filling material and method of use, US Patent: 5769638.
- Tsesis, I., Rosen, E., Schwartz-Arad, D., Fuss, Z., 2006. Retrospective evaluation of surgical endodontic treatment: traditional versus modern technique. *J. Endod.* 32 (5), 412–416.
- Van Noort R., 2013. *Introduction to dental Materials*. fourth ed., Elsevier Health Sciences, pp. 61–72, 73–93, 95–106, 107–111.
- Vasudev, S., Goel, B., Tyagi, S., 2003. Root end filling materials-A review. *Endodontology* 15, 12–18.
- Von Arx, T., Hänni, S., Jensen, S.S., 2010. Clinical results with two different methods of root-end preparation and filling in apical surgery: mineral trioxide aggregate and adhesive resin composite. *J. Endod.* 36 (7), 1122–1129.
- Von Arx, T., Hänni, S., Jensen, S.S., 2014. 5-year results comparing mineral trioxide aggregate and adhesive resin composite for root-end sealing in apical surgery. *J. Endod.* 40 (8), 1077–1081.
- Von Arx, T., Jensen, S.S., Hänni, S., 2007. Clinical and radiographic assessment of various predictors for healing outcome 1 year after periapical surgery. *J. Endod.* 33 (2), 123–128.
- Von Arx, T., Jensen, S.S., Hänni, S., Friedman, S., 2012. Five-year longitudinal assessment of the prognosis of apical microsurgery. *J. Endod.* 38 (5), 570–579.
- Walsh, R.M., Woodmansey, K.F., Glickman, G.N., He, J., 2014. Evaluation of compressive strength of hydraulic silicate-based root-end filling materials. *J. Endod.* 40 (7), 969–972.
- Wang, Z.-H., Zhang, M.-M., Wang, J., Jiang, L., Liang, Y.-H., 2017. Outcomes of endodontic microsurgery using a microscope and mineral trioxide aggregate: a prospective cohort study. *J. Endod.* 43 (5), 694–698.
- Wilson, A.D., Kent, B., 1971. The glass ionomer cement, a new translucent dental filling material. *J. Appl. Chem. Biotechnol.* 21 (11), 313.
- Zhou, W., Zheng, Q., Tan, X., Song, D., Zhang, L., Huang, D., 2017. Comparison of mineral trioxide aggregate and iRoot BP plus root repair material as root-end filling materials in endodontic microsurgery: a prospective randomized controlled study. *J. Endod.* 43 (1), 1–6.
- Zhu, Q., Haglund, R., Safvi, K.E., Spangberg, L.S., 2000. Adhesion of human osteoblasts on root-end filling materials. *J. Endod.* 26 (7), 404–406.