

*Original article***The effect of Indoxacarb on blood parameters and liver tissues in Mice****Zainab EL Mabrouk^{1*}, Salma Abuser¹, Naema Shibani², and Habiba El Jaafari¹**¹Developmental Biology Division, Zoology Department, Faculty of Science, University of Tripoli, Tripoli, Libya²Entomology Division, Zoology Department, Faculty of Science, University of Tripoli, Tripoli, Libya*Received 6 October 2016/ Accepted 7 November 2016***Abstract**

This study was conducted to evaluate the effect of Indoxacarb (Avant), an oxidiazine compound on hematological, some biochemical parameters of liver functions and histological changes in the liver. Sixteen albino adult mice were divided into two groups (n=8). Group 1 (control group). Group 2 injected intraperitoneally with 90 mg/kg indoxacarb for a period of two weeks. Hematological investigations revealed a significant decrease in red blood cells count (RBC), haematocrit, mean corpuscular volume (MCV) and hemoglobin content (Hb) compared to the control group, whereas, white blood cells (WBC) and platelets counts a highly significant increase. Biochemical analysis illustrated that indoxacarb caused a marked elevation of alanine amino transferase (ALT) and considerable decrease in the total protein and albumin. Microscopic examination of liver sections illustrated that treatment with 90 mg/kg indoxacarb led to histoarchitectural changes of the liver including focal aggregations of lymphocytes, necrosis, degeneration of hepatocytes, inflammatory cells infiltration in portal tracts, pyknosis, karyolysis and sinusoidal dilatation. These results concluded that short period of exposure to indoxacarb may have toxic effects on public safety.

Keywords: Indoxacarb, Hematology, Histopathology, Liver, Mice**Introduction**

Large numbers of pesticides with novel modes of action have been developed to substitute several old pesticides that had been used. Recent pesticides have been particularly planned for fast assassination of pests and relative safety to non-target organisms and environment. The efficiency and safety of new pesticides are a consequence of using special physiologic differences between mammals and specific pests (McCann *et al.*, 2001; Poppengal and Oehme 2010).

Indoxacarb an oxadiazine compound is a new synthetic insecticide produced by DuPont (EPA, 2000; Dinter and Wiles, 2000; Arahashi, 2001), and marketed in the U.S. as Steward and Avaunt (EPA, 2000). Indoxacarb has a broad spectrum insecticide that is considered a safe substitute for organophosphate insecticides (Rathnayaka *et al.*, 2016) effective against the insects of the Lepidoptera, Coleoptera, Hemiptera, Diptera and Hymenoptera (Nassar, 2016). Indoxacarb (DPX-MP062) is a 75:25 mixture of active and inactive enantiomers displays potent insecticidal activity and low toxicity on non-target organisms (Dinter and Wiles, 2000; Arahashi, 2001; Litchfield *et al.*, 2015, Nassar, 2016). Moreover, it was reported that indoxacarb metabolized inside the insects by esterases and amidases to an insecticidal metabolite, Decarbomethoxylated JW062 (DCJW) (Tsurubuchi and Kono, 2003, von Stein *et al.*, 2012, Nassar, 2016). Also, it is bioactivated in mammals, but decarbomethoxylation to DCJW is less efficient than in insects and detoxication is accomplished through different biochemical pathways (Silver *et al.*, 2010; von Stein *et al.*, 2012).

Indoxacarb blocks the flow of sodium ions through the inhibition of its voltage channels (Tsurubuchi *et al.*, 2001; Chemical fact sheet, 2012, Litchfield *et al.*, 2015, Rathnayaka *et al.*, 2016; Sandeep *et al.*, 2016). This causes an impaired nerve function, cessation of feeding, paralysis and death in insects (Dinter and Wiles, 2000; Laped *et al.*, 2001; Nassar, 2016; Sandeep *et al.*, 2016).

Earlier study reported that levels of alanine amino transferase (ALT) and aspartate amino transferase (AST) enzymes are increased in the blood of buffalo calves after exposure to indoxacarb for 90 days (Goval and Sandhu, 2009). Previous studies on indoxacarb acute toxicity following suicidal ingestion have led to clinical effects such as cyanosis, dyspnea, lethargy, coma and acute kidney injure (Chhabra *et al.*, 2010; Wu *et al.*, 2010; Park *et al.*, 2011; Jin 2012; Rathnayaka *et al.*, 2016) and Rhabdmyolysis (Jin 2012; Rathnayaka *et al.*, 2016). However, indoxacarb is a relatively new pesticide, so there are few studies on its side effects on mammals. Blood parameters are considered a potential biomarker of exposure to chemical agents, as they can increase and decrease parameters (Van der Oost *et al.*, 2003). Therefore, the present investigation was performed to evaluate the effects of indoxacarb on blood parameters and histoarchitectural of liver of albino mice.

Materials and Methods

Indoxacarb 200 g/L (75:25) was purchased from a local pesticide store, supplied by Libyan Agrochemicals & Agriculture Supplies Specialized Co. it was

suspension concentrate diluted in water before use and administrated to animal's intraperitoneally (i.p) at a dose of 90 mg/kg.

Sixteen laboratory adult male mice had been used. These mice bred and housed in the animal house of the Zoology department / Faculty of Science / Tripoli University. Animals were housed in plastic cages containing wooden flakes under husbandry, and maintained at room temperature 22 ± 3 C under natural light/dark photoperiod. The mice were fed with a standard commercial pelleted and drinking water ad-libitum through the study. The experiments were performed on 10-12 weeks old albino mice with weight of 25 to 30 gram (g). The initial and final body weights of mice were recorded.

The mice were divided into two groups of eight animals each. Group 1 served as a control and injected with distilled water in the intraperitoneal. Group 2 was treated with 90 mg/kg body weight of indoxacarb for two weeks. At the end of the experimental period the blood from the control and treated mice were collected for the following parameters; Hb content, hematocrit, MCV, RBC, WBC and platelets counts. The second part of blood was used for serum preparation and assay some biochemical parameters of liver functions such as ALT, total protein and albumin.

Histopathology

Liver tissues were fixed in a 10% neutral buffered formalin solution. The tissues were passed through increasing gradient of ethanol then through xylene, embedded in paraffin and cut a 5- μ m thick using rotatory microtome. The sections were stained with Hematoxylin and Eosin (H and E), microscopically examined and photographed. The histopathological examination was conducted in Faculty of Science, Tripoli University.

Statistical analysis

The results obtained in this study are represented as means \pm standard deviation (SD) (n=8). Statistical

analysis was performed using one-way analysis of variance (ANOVA) to evaluate significant difference between control and treated group for body weight and blood parameters. *P*-values less than 0.05 were considered statistically significant. All statistical analysis were performed using SPSS statistical version 16 software package.

Results

Morbidity and mortality

Male mice intraperitoneally injected with indoxacarb (90 mg/kg bw/day) for two weeks have shown signs of toxicity such as salivation, diarrhea, tremor, vigorous rolling, head tilt. No death was recorded throughout the experimental period.

Body weight

The body weight of the control group was increased by 1.5 g, while the treated group was decreased by 4.7 g when compared with the initial body weight (Table 1) these results showed high significant decrease in the body weight ($P < 0.001$) compared with the control group.

Hematological and biochemical parameters

The effect of indoxacarb on blood parameters in the mice are presented in (Table 2). There were significant changes observed in treated group compared to the control group. RBC count, hematocrit and MCV significantly reduced ($P < 0.001$). Hb content also decreased considerably ($P < 0.01$). On the other hand, platelets and WBC counts significantly increased ($P < 0.001$) in treated group compared to the control group. The effect of indoxacarb on some biochemical parameters of liver functions are presented in (Table 3). The findings of the present study revealed that treatment with 90 mg/kg indoxacarb showed significant increase in the level of ALT ($P < 0.05$) as compared with that of the control group. However, a marked decrease in total protein ($P < 0.05$) and albumin ($P < 0.01$) was recorded.

Table 1. Effect of indoxacarb treatment on body weight (g) of mice

Group	Initial weight (g)	Final weight (g)	Weight change (g)
Control	28 \pm 0.894	30.5 \pm 1.643	1.5
Treatment (90mg/kg)	27.5 \pm 2.422	22.83 \pm 1.941***	- 4.7

Values are presented as means \pm SD. the mean difference is significant at the $P < 0.05$ level. *** Indicates highly significant difference $P < 0.001$ compared with the control group.

Table 2. Effect of indoxacarb on Hematological parameters in mice

Hematological parameters	Control	Treatment
RBC ($\times 10^6/\mu\text{L}$)	10.54 \pm 0.114	9.68 \pm 0.228 ***
WBC ($\times 10^3/\mu\text{L}$)	6.84 \pm 0.586	15.2 \pm 2.775 ***
Hb (g/dl)	14.46 \pm 0.114	12.74 \pm 0.865 **
Hct (%)	53.62 \pm 0.303	42.02 \pm 2.855 ***
Plt ($\times 10^3/\mu\text{L}$)	442.4 \pm 8.562	1534 \pm 277.189 ***
MCV (fl)	50 \pm 0.791	43.3 \pm 2.661 ***

RBC, red blood cells; Hb, hemoglobin; HCT, hematocrit; MCV, mean corpuscular volume; MCH, mean corpuscular hemoglobin; MCHC, mean corpuscular hemoglobin concentration; PLT, platelet; and WBC, white blood cells. Values are presented as means \pm SD. ** Indicates very significant difference $P < 0.01$ compared with the control group. *** Indicates highly significant difference $P < 0.001$ compared with the control group.

Table 3. Effect of high dose of indoxacarb on some biochemical parameters of liver functions in mice

Biochemical parameters	Control	Treatment
Total protein (mg/dl)	7.5 \pm 0.678	5.78 \pm 1.205*
Albumin (mg/dl)	3.1 \pm 0.122	2.1 \pm 0.381 **
ALT (IU/L)	34.6 \pm 8.532	95 \pm 26.457*

ALT, alanine aminotransferase. Values are presented as means \pm SD. * Indicates very significant difference $P < 0.05$ compared with the control group. ** Indicates significant difference $P < 0.01$ compared with the control group.

Histopathological

Light microscopy of the liver sections that stained with H and E, from albino mice of the control group (Figure 1. A and B) revealed normal histological architecture of the hepatic tissues with intact cells, that have normal nuclei and the lobules contain central and portal triad space with normal bill duct. However, in the treated mice, histological observations revealed some moderate or mild changes in the architecture of the hepatic tissues (Figure 2). Biliary inflammation within the triads of the liver, intense mononuclear

inflammatory infiltrates in portal tracts with loss of bile ductless (A and B). Additionally, focal aggregations of lymphocytes and heterophils were seen in the hepatic tissues of the indoxacarb group (C and D). Moreover, (E and F) showed the cytoplasm was disintegrated, area of necrosis and hepatic architecture with mild hydropic degeneration of hepatocytes. Besides, atrophy, hemorrhage, apoptosis, pyknosis, karyolysis and hyperplasia are seen and hepatic sinusoidal dilatation with blood was observed as well (G). Also, presence of hemosedrin could be seen (H).

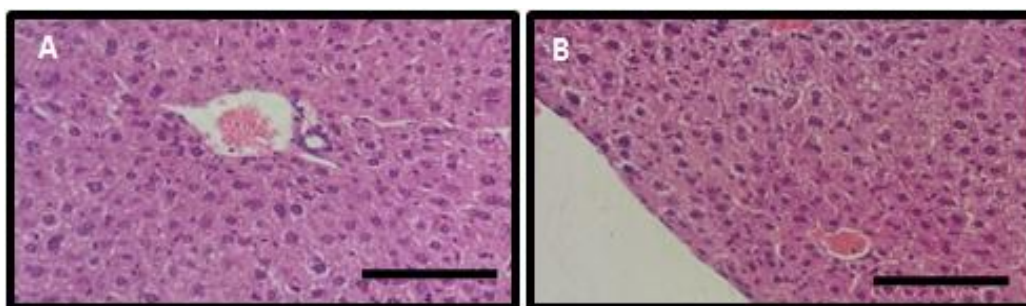


Fig 1: Light microscopy of liver sections (Stain: H and E) from albino mice of the control group 1 (A and B), showing normal histological architecture of the hepatic tissues with intact cells, nuclei and central and portal triad space with normal bill duct (Bar=100 μm).

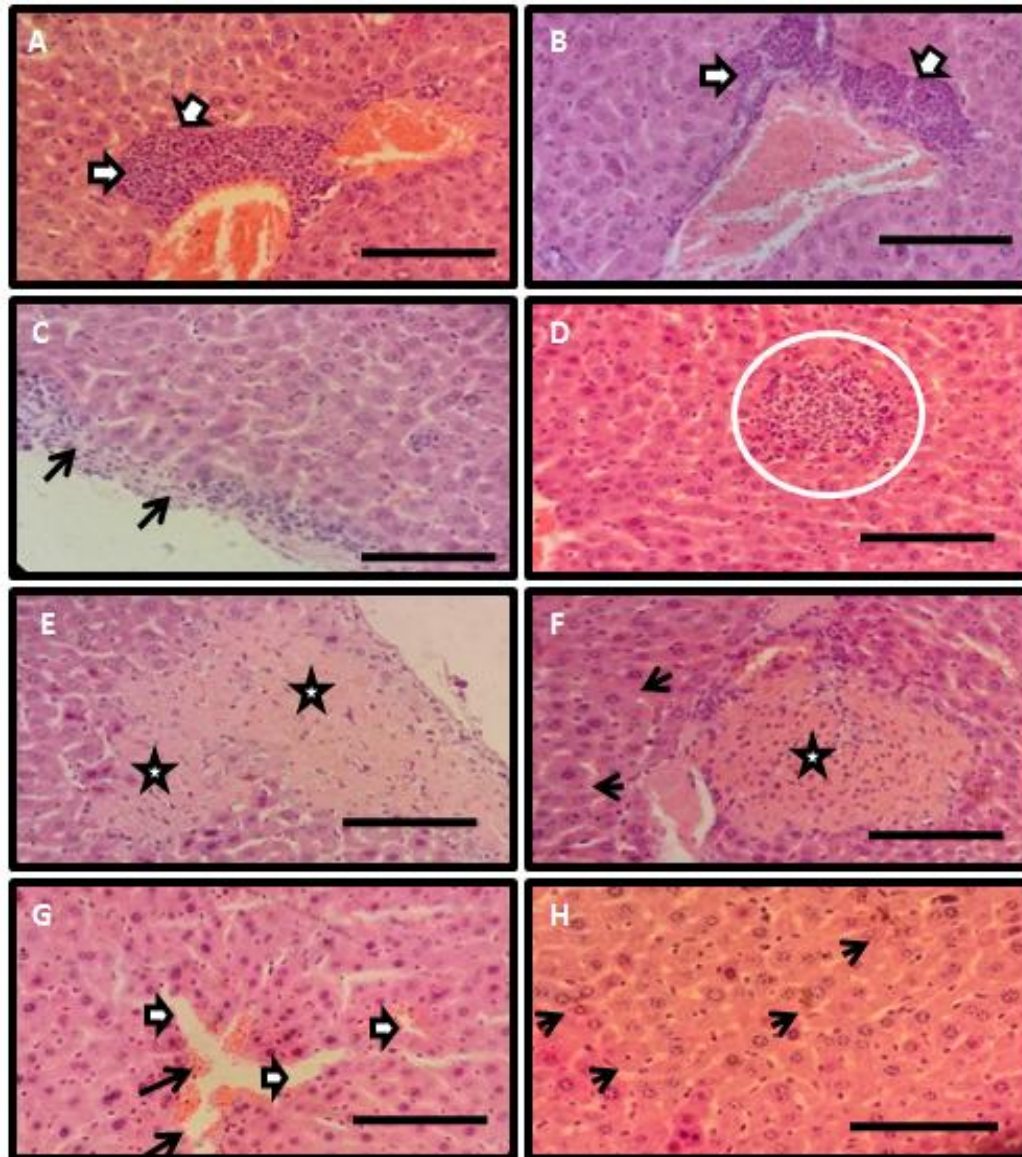


Fig 2: examined sections from Group 2 which was exposed to accumulated dose of indoxacarb of 90 mg/kg/day for two weeks showed some moderate and mild changes in the histological architecture of the hepatic tissues. Mild inflammation within the triads of the liver, intense mononuclear inflammatory infiltrates in portal tracts with loss of bile ductules (A and B) marked by arrows. The inflammatory infiltrate can have granulomatous features as well (C) marked by arrows and (D) by circle. (E) and (F) showed the disintegrated cytoplasm, area of necroses as showed by the (stars) and the head arrows showed the hydropic hepatocytes. Atrophy, hemorrhage, apoptosis, pyknosis, karyolysis and hyperplasia are seen and siunsodial dilatation were observed (G). The presence of hemosedrin could be seen (H).

Discussion

Human may be exposed to indoxacarb from residues on vegetables and fruits or during exposure in the occupational environment. There is no report on the effects of indoxacarb on the histopathology of the mammals organs and limited data about its effect on the blood parameters in mammals (EPA, 2004; California Environmental Protection Agency, 2004; EPA, 2007). Thus, the effect of indoxacarb on the hematological, biochemical parameters and histology of liver was performed.

Investigated study illustrates that administered 90 mg/kg/day of indoxacarb i.p to mice for two weeks has produced significant toxic effects. There was highly significant decrease in the body weight of treated mice. The decrease in body weight is in agreement with the previous studies (Arfat *et al.*, 2014; Badgujar *et al.*, 2013) who reported that high dose of the insecticide imidacloprid resulted in reduction of the body weight of mice. The animals were less susceptible to food intake



due to the toxic effect of pesticides that led to body weight reduction (Li *et al.*, 2007).

The results obtained on the hematological parameters of the treated mice showed a significant variation from that of control group. Hematological index are sensitive to various chemicals and environmental factors (Vosyliene, 1999) and reflect the health condition of an organism (Ojutiku *et al.*, 2013). This study illustrated that indoxacarb reduced the RBCs count, hematocrit, MCV and Hb in mice. This effect is likely due to the adverse effect of indoxacarb on bone marrow or enhanced destruction of RBC (Shit *et al.*, 2008). The reduction of the level of the Hb, RBCs count and hematocrit was consistent with *in vitro* studies conducted on rat and dog exposed to indoxacarb (EPA, 2004; California Environmental Protection Agency, 2004; EPA, 2007). In addition, these results are in agreement with the previous report by Shit *et al.*, (2008) who reported that RBCs in mice were decreased after exposure to a single dose of 500 mg/kg indoxacarb. Similar reduction of RBC and Hb were reported by Eissa and Zidan (2009) in albino rats exposed to the pesticide abamectin. Furthermore, other investigators following treatment with different pesticides reported reductions in Hb, RBC counts and hematocrit (Adedeji *et al.*, 2009; Kim *et al.*, 2009; Magar and Dube, 2012). It was suggested that reduction in RBC and Hb due to disruption of hematopoiesis (Ali, 1990; Anubama *et al.*, 2001; El-Deeb *et al.*, 2007; Adedeji *et al.*, 2009; Magar and Dube, 2012; Selmanoglu *et al.*, 2001; Choudhari and Deshmukh, 2007).

The current study also showed a significant increase in platelets and WBC counts. Increased WBC count can assist in the removal of cellular debris of necrotic tissue rapidly and aids in survival and recovery of animal exposed to insecticide (Magar and Dube, 2012). These results are quite similar with those found by others who showed that the pesticide cypermethrin and malathion increased WBC in fishes (Magar and Dube, 2012; Ojutiku *et al.*, 2013). Similar results was reported that ivermectin increase WBC in donkeys (Ismail *et al.*, 2013). Considerable increase in platelets count in the treated group recorded in this study are in the accordance with the study of Adedeji *et al.*, (2009) who reported that platelets enhanced following treatment of African catfish with diazinon. Platelets play critical function in blood clotting, which prevent blood loss from hemorrhage and therefore high number of platelets reduces clotting time (Adedeji *et al.*, 2009). However, this result is contradictory with other results suggested that abamectin (Eissa and Zidan, 2009) and chlopyrifos (El-Deeb *et al.*, 2007) caused reduction in platelets and WBC in albino rats. The difference in the results could be due to many factors such as species, pesticides, duration of exposure and route of administration.

Liver play significant role in the detoxification of various chemicals and drugs, therefore, it is adversely affected by different chemicals that enter into animal body regardless the way of administration (Guyton and

Hall, 2006). Significant increase in ALT ($P < 0.05$) was observed in the current study. Elevation ALT in the blood may be associated with degeneration and necrosis of hepatocytes which confirmed in this study through microscopic examination of the liver of treated mice. These findings are consistent with those reported by (Arfat *et al.*, 2014) who pointed out that ALT and AST were increased following imidacloprid exposure in rats. Other studies illustrated that a considerable increase in the level of ALT and AST in pesticide exposed agricultural workers. (Ibrahim *et al.*, 2011; Awad *et al.*, 2014). Rise of transaminases in blood may be related to tissue damage which increased synthesis of these enzymes as an adaptive mechanism to the chemical stress (Rahman and Siddiqui, 2003). In addition, it was hypothesized that increase ALT in blood may be due to alterations in permeability of the cell membrane of hepatocytes after hepatotoxic damage (Choudhary *et al.*, 2003; Gaskill *et al.*, 2005; Mansour and Mossa, 2010). These results are in accordance with other studies (Eissa and Zidan, 2010; Ambali *et al.*, 2011) who revealed a marked decrease of total protein in rats exposed to insecticides. Similarly, diminished total protein has also been reported by other researchers (Awad *et al.*, 2014) in agricultural workers and (Adedeje, 2010) in African cat fish. It might attribute to increase catabolism of the biomolecules to meet energy demand under stress or as a result of impaired liver function (Ivanova-Chemishanska 1982).

Regarding to histopathological examination, various pathological changes observed in the liver of mice following exposed to indoxacarb included focal inflammation, karyolysis, pyknosis, monocular cell infiltration and sinusoids dilatation. In this study the histological changes in the liver were similar to the result of Selmanoglu *et al.*, (2001) who confirmed that carbendazim caused mononuclear cell infiltration, dilation of sinusoids and increase number of kupffer cells in the liver of rats. In addition, Abd-Elhady and Abu-Elghar (2013) reported that carbendazim caused degenerative and atrophy of hepatocytes and congestion of blood vessels of rats. Furthermore, these findings are in accordance with other studies who reported that mild focal necrosis of the liver and hepatocellular damage following imidacloprid exposure in mice (Arfat *et al.*, 2014) and chickens (Kammon *et al.*, 2010). Moreover, it was reported that treatment of rats with endosulfan (Choudhury *et al.*, 2003) and mice with carbosulfan (Ksheerasagar and Kaliwal 2006) caused liver damage such as dilation of sinusoids, hypertrophy of hepatocytes and lymphocytic infiltration in central vein. Additionally, histopathologic study of rats' liver treated with DDT and permethrin individually revealed hepatocytes with pyknotic, and cell with nuclear destruction stimulated by permethrin, while DDT caused cytoplasmic vacuolization and hepatocyte necrosis (Kostka *et al.*, 2000).

Conclusion

According to our findings in this study, indoxacarb caused significant changes in hematological and

biochemical indices and mild to moderate damage in the liver in mice, therefore use of the pesticides extensively without regulation could lead to dangerous effects in non-target animals and human.

References

- Abd-Elhady H K and Abou-Elghar G E (2013). Abamectin induced biochemical and histopathological changes in the albino rat, *Rattus norvegicus*. *J Plant Prot Res*. 53: 263-270.
- Adedeji O B, Adeyemo O K and Agbede S A (2009). Effects of diazinon on blood parameters in the African catfish (*Clarias gariepinus*). *African J Biotechnol*. 8 (16): 3940-3946
- Adedeji O B (2010). Acute effect of diazinon on blood plasma biochemistry in the African cat fish *Clarias gariepinus*. *J Clin Med Res*. 2(1): 1-6.
- Ali B H (1990). The effect of ivermectin on some hematological indices in rabbits: influence of vitamin K treatment. *Clin Exp Pharmacol Physiol*. 17: 735-738.
- Ambali S F, Akanbi D O, Oladipo O O, Yaqub L S (2011). Subchronic chlorpyrifos induced clinical, hematology and biochemical changes in swiss albino mice: protective effect of vitamin E. *Int J Biochem Res*. 2(2): 497-503.
- Anubama V P, Honnegowda H, Jayakumar K, Krishnappa G, Narayana K, Rajeshwari Y B (2001). Effect of doramectin on immune response of rats to SRBC antigen. *Indian Vet J*. 78: 779-782.
- Arahachi T (2001). Recent progress in the mechanism of action of insecticides: pyrethroids, fipronil and indoxacarb. *J Pest Sci*. 26: 277-285.
- Arfat Y, Mahmoodb N, Tahirc M U, Rashidd M, Anjume S, Zhaoa F, Di-Jie Lia Y L, Huda L, Znihaoa C, Shanga P, Qianaakey A (2014). Effect of imidacloprid on hepatotoxicity and nephrotoxicity male albino mice. *Toxicol Rep*. 1: 554-561.
- Awad O M, El-Fiki S A, Abou-Shanab R A I, Hassanin N M A, Abd Elrahman R (2014). Influence of exposure to pesticides on liver enzymes in male agriculture workers. *Global NEST J*. 16: 1-12.
- Badgujar P C, Jain S, Singh A, Punia j, Gupta G A, Chandratre G A (2013). Immunotoxic effects of imidacloprid following 28 days of oral exposure in BALB/c mice. *Environ Toxicol Pharmacol*. 35: 408-418.
- California Environmental Protection Agency (2004). Summary of Toxicology Data: Indoxacarb. Chemical Watch fact sheet Stats: Indoxacarb (2012). 32 (2) 21-24.
- Chhabra R, Singh L, Tandon M, Bubu R (2010). Indoxacarb poisoning: A rare presentation as methemoglobinemia. *Indian j Anaesth*. 54: 239-241.
- Choudhary N, Sharma M, Verma P, Joshi S C (2003). Hepato and nephrotoxicity in rat exposed to endosulfan. *J Environ Biol*. 24 (3): 305-308.
- Choudhary C and Deshmukh P (2007). Acute and supchronic toxicity study of *Semecarpus anacardium* on hemoglobin percent and RBC count of male albino rat. *J Herbal Med Toxicol*. 1: 43-45.
- Dinter A and Wiles A J (2000). Safety of the new Dupont insecticide indoxacarb to beneficial arthropoda an overview. *Integrated Control in Viticulture IOBC/wprs Bulletin*. 22 (9): 149 – 156.
- Eissa F I and Zidan N A (2009). Hematological, biochemical and histopathological alterations induced by abamectin and *Bacillus thuringiensis* in male albino rat. *Australian J Basic Appl Sci*. 3(3): 2497-2505.
- El-Deeb A E A, Abd El-Aleem I M, Ghaleb S S (2007). Harmful effect of some insecticides on vital parameters of albino rats. *J Egyptian Soci Toxicol* 36: 53-60.
- EPA: Factsheet (2000). Indoxacarb. Office of Prevention, *Pesticides and Toxic Substances*, Washington D.C.
- EPA (2004). *Indoxacarb; Notice of Filing a Pesticide Petition on to Establish a Tolerance for a Certain Pesticide Chemical in or on Food*. In: Office of Prevention Pesticides and Toxic Substances, ed: Federal Registrar, OPP-2004-0034; FRL-7345-2.
- EPA (2007). *Indoxacarb; Pesticide Tolerance In: Office of Prevention Pesticides and Toxic Substances*, ed: Federal Registrar, EPA-HQOPP- 2005-0149; FRL-8137-8, Page 37633-37641.
- Gaskill C, Miller L, Mattoon J, Hoffmann W, Burton S, Gelens C, Ihle S, Miller J, Shaw D, Cribb A (2005). Liver histopathology and liver and serum alanine aminotransferase and alkaline phosphatase activities in Epileptic dogs receiving phenobarbital. *J Vet Pathol*. 42: 147-160.
- Goval S and Sandhu HS (2009). Toxic effects of sub-chronic oral exposure of indoxacarb on biochemical parameters in buffalo calves. *Toxicol Int*. 16 (2):141-146.
- Guyton A and Hall E (2006). *Text Book of Medical Physiology*. 11th ed. Elsevier, Inc, pp. 802-832.



- Jin K (2012). Rhabdomyolysis, methemoglobinemia and acute kidney injury after indoxacarb poisoning. *Clin Toxicol.* 50: 227.
- Ibrahim K S, Amer N M, El-Tahlawy E M, Abd Allah H M (2011). Reproductive outcome, hormones levels and liver enzymes in agricultural female workers. *J Adv Res.* 2: 185-189.
- Ismail N H A, Suliman S E, Bulldan A G A, Seri H I (2013). Hematological, biochemical and histopathological alterations induced by ivermectin in donkeys (*Equus asinus*). *Sudan J Sci Technol.* 14 (2): 1-14.
- Ivanova-Chemishanska L (1982). *Toxicity of Pesticides, Health Aspects of Chemical Safety.* Dithiocarbamates. p. 158–169. In WHO Copenhagen
- Kammon A M, Brar R S, Banga H S, Sodhi S (2010). Patho-biochemical studies on hepatotoxicity and nephrotoxicity on exposure to chlorpyrifos and imidacloprid in layer chickens. *Vet Arhiv.* 80 (5): 663-672.
- Kim H Y, Lee S B, Cho H W, Kang M G, Yang J S, Shin I S, Kim J C (2009). Evaluation of 13-week inhalation toxicity of sec-butanethiol in rats. *Food Chem Toxicol.* 47: 2294–2301
- Kostka G, Palute D, Kopec-Szlezak J, Ludwicki J K (2000). Early hepatic changes in rats induced by permethrin in comparison with DDT. *Toxicol.* 142: 135–143.
- Ksheerasagar R L and Kaliwal B B (2006). Histological and Biochemical Changes in the Liver of Albino Mice on Exposure to Insecticide, Carbosulfan. *Caspian J Environ Sci.* 4 (1): 67-70.
- Lapied B, Grolleau F and Satielle D B (2001). Indoxacarb, an oxadiazine insecticide, blocks insect neuronal sodium channels. *British J Pharmacol.* 132, 587 - 595.
- Litchfield H, Gupta R C, Doss R B, Bland S D., Canerdy T D (2015). Safety evaluation of permethrin and indoxacarb in dogs topically exposed to Actvyl^R Tick Plus. *J Vet Sci Technol.* 6: 218.
- Li J Bi D, Pan S, Zhang Y (2007). Effect of diet with thiram on liver antioxidant capacity and tibial dyschondroplasia in broilers. *British Poultry Sci.* 48: 724-728.
- Magar R S and Dube K V (2012) Impact of malathion on some haematological parameters of *Channa punctatus* (BLOCH). *Int J Biomed Adv Res.* 3(9): 683-685.
- Mansour S A and Mossa A H (2010). Oxidative damage, biochemical and histopathological alteration in rat exposed to chlorpyrifos and the role of zinc as antioxidant. *Pest Biochem Physiol.* 96 (1): 14–23.
- McCann S F, Annis G D, Shapiro R, Piotrowski D W, Lahm G P, Long J K, Lee K C, Hughes M M, Myers B J, Griswold S. M, Reeves, B W, March R W, Sharpe P L, Lowder P, Barnette W E, Wing, K. D. (2001). The discovery of indoxacarb: oxadiazines as a new class of pyrazoline-type insecticide. *Pest Manag Sci.* 57: 153-164.
- Nassar A M K (2016). Comparative endocrine disrupting effects of abamectin. *Int J Pharmacol Toxicol.* 4 (1): 89-92.
- Ojutiku R O, Asuwaju F P, Kolo R J, Obande R A, Agbelege O O (2013). Haematological effect of acute concentration of cypermethrin on juveniles of *Clarias gariepinus*. *Int J Eng Sci Invent.* 2 (3): 33-41.
- Park J S, Kim H, Lee S W, Min J H (2011). Successful treatment of methemoglobinemia and acute renal failure after indoxacarb poisoning. *Clin Toxicol.* 49:744 – 746.
- Poppenga R H and Oehme F W (2010). *Pesticide use and associated morbidity and mortality in Veterinary Medicine Hayes' Handbook of Pesticide Toxicology.* pp. 285-298.
- Rathnayaka R M M, Wijekoon C N, Sugathapala A G H, Ranathunga P E A (2016). Indoxacarb – a rare cause of poisoning *J Ceylon College Phy.* 47: 46-47.
- Rahman M F and Siddiqui M K J (2003). Biochemical enzyme activity in different tissues of rats exposed to a novel phosphorothionate (RPE-V). *J Environ Sci Health.* Part B Pesticides, Food Contaminants, and Agricultural Wastes. 38 (1): 59-71.
- Selmanoglu G, Barlas N, Songur S, Kocskaya (2001). Carbendazim-induced Haematological, Biochemical and Histopathological Changes to the Liver and Kidney of Male Rats. *J Human Exp Toxicol.* 20:625-630.
- Sandeep K, Chandra S, Mukhopadhyay C S, Jaspreet S, Arora J S, Sethi R S (2016). Indoxacarb interaction alters immunotoxic and genotoxic potential of endotoxin. *J Pest Sci.* 41 (3): 65-70.
- Shit S P, Panghal R S, Kumar V, Rana R D (2008). Acute toxicity and gross behavioural effects on indoxacarb in laboratory animals. *Haryana Vet.* 47: 49-51.
- Silver K S and Soderlund D M (2005). Action of pyrazoline-type insecticides at neuronal target sites. *Pest Biochem Physiol* 81: 136-143
- Silver K S, Song W, Nomura Y, Salgado V L, Dong K (2010). Mechanism of action of sodium channel



- blocker insecticides (SCBIs) on insect sodium channels. *Pest Biochem Physiol.* 97: 87-92.
- Tsurubuchi Y, Karasawa A, Nagata K, Shono T, Kono Y (2001). Insecticidal activity of oxadiazine insecticide indoxacarb and its *N*-decarbomethoxylated metabolite and their modulations of voltage-gated sodium channels. *Appl Entomol Zool.* 36 (3): 381–385.
- Tsurubuchi Y and Kono Y (2003). Modulation of sodium channels by the oxadiazine insecticide indoxacarb and its *N*-decarbomethoxylated metabolite in rat dorsal root ganglion neurons. *Pest Manag Sci.* 59: 999–1006.
- Wu Y J, Lin Y L, Huang H Y, Hsu B G. (2010). Methemoglobinemia induced by indoxacarb intoxication. *Clin Toxicol.* 48:766 – 767.
- Vosyliene M Z (1999). *The effect of heavy metal mixture of haematological parameters of rainbow trout. Heavy metals in environment.* An integrated approach Lovejoy DA (Ed.). p. 295-298.
- Van der Oost R, Beyer J, Vermeulen N P E (2003). Fish bioaccumulation and biomarkers in environmental risk assessment: a review. *Environ Toxicol Pharmacol.* 13:57–149.
- Veeraiah K, Srinivas Rao P, Symyuktha R A, Dhilleswarao H.(2013). Changes in biochemical parameters of fresh water fish *Labeo Rohita* exposed to lethal and sub-lethal concentrations of indoxacarb. *Int j Bioassays* 2 (10): 1382-1387.
- Von Stein R T and Soderlund D M (2012). Compound-specific effects of mutations at Val787 in DII-S6 of Nav1.4 sodium channels on the action of sodium channel inhibitor insecticides. *Neurotoxicol.* 33: 1381–1389.