

# War Ocular Injuries in Tripoli Eye Hospital, 2011

Karima Shalabi@

Department of Pediatric Ophthalmology, Tripoli Eye Hospital, Libya

Received 13 October 2014/ Accepted 17 December 2014

## ABSTRACT

The study was designed to study the type and severity of ocular injuries that had occurred during the Libyan revolution. It is a retrospective study that was conducted in Tripoli Eye Hospital from February 2011 to December 2011.

History was taken, ophthalmic examination, X-ray orbit and/or computerized tomography were done to rule out intraocular . B-scan ultrasonography was done to examine fundus (if required). The treatment varied according to type and severity of ocular injury.

Total number of patients was 225 out of them 204 male (90.6%) and 21 Female (9.3%). The most common causes were firearm shootings 44%, blunt trauma 28.4%, explosions 18.6% and mines 0.8%.

Most injured were men around 20 to 30 years, in right eye 50.2% (113), left eye 41.3% (93) and bilateral 8.4%. Closed eye injury 54.2%, open eye injury (45.7%) of the cases.

The most common injury was corneoscleral perforation, intraocular foreign body, ruptured globe 13eyes (5.7%).

Visual acuity was poor in severely injured eyes, no light perception bilaterally in 2.6%.

Other body injuries in 11 patients (4.8%) ranged from burns to limb amputations. The most common performed surgery was primary repair in 32 % (72 eyes) followed by vitrectomies in 6.2% (14 eyes), cataract surgery (12 eyes) 5.3%, evisceration in 1.3% (3 eyes).

During the Libyan revolution, war ocular injury had become increasingly common, in the same period the number of routine admissions was reduced as routine work was cancelled and road accidents declined secondary to severe fuel shortage. Visual prognosis is poor in severely injured eyes despite surgical interventions.

**Keywords** - *Libyan revolution; Intraocular foreign body; Hyphema; Vision.*

## INTRODUCTION

Ocular injury is an important cause of ocular morbidity.<sup>1</sup> It is defined as the result of mechanical, electrical, thermal or chemical energy damage to the eye.<sup>2</sup> Every year more than half a million potentially blinding ocular injuries occur globally, ocular trauma is the commonest cause of unilateral blindness.<sup>3</sup> Eye injuries divided into two groups: closed globe and open globe injuries. Injuries include non-penetrating mechanical injuries e.g hyphema, subconjunctival haemorrhage, commotio retinae, orbital fracture or penetrating eye injury. War ocular injuries are becoming increasingly common in different parts of the world.<sup>4</sup> The eye injury in war ranges from mild to serious blinding injury.<sup>5-7</sup>

## MATERIALS AND METHODS

This retrospective study was conducted at Tripoli Eye Hospital from February 2011 to December 2011 to assess patients with war ocular injury during Libyan revolution. The patients were assessed by ophthalmologist at casualty department in Tripoli Eye Hospital.

History was taken and ophthalmic examination was done. Patients were evaluated for types of ocular injury and extent of damage. Vision examination with Snellen

chart, slit lamp examination (haagstreit). Intraocular pressure measurement with Goldmann tonometry. Fundus examination with 90 dioptervolk lens, and or indirect ophthalmoscope, if no fundal view B-scan ultrasonography was done (Sonomed), X-ray was done in those patients with high suspicion of intraocular foreign body (IOFB) a computerized tomography scan was done (CAT) to rule out radio translucent foreign body. Primary care included control of high intraocular pressure, removal of superficial conjunctiva and corneal FB, primary repair was performed in eyes with perforating eye injury under general anesthesia, cataract and retinal surgery were also performed. Evisceration was performed in severely injured eyes. SPSS 17 was used for data analysis.

## RESULTS

Total number of cases was 225 including 204 male (90.6%), 21 female (9.3%) most of the cases were young males between 20 to 30 years (Figure 1). The causes were as following: firearm shooting 44%, blunt trauma as sticks 28.4%, explosions 18.6%, mines 0.8% (the affected two boys from Zlitan city with land mines) (Figure 2). Ocular injury was uni- lateral in 91.6 % and bilateral in 8.4% (Figure 3a,b). Right eyes in 50.2%, left eyes in 41.3 %



(Table 1). In 54.2% was closed eye injury and in 45.7% with open eye injury. No exact zone classification was assessed in most of patient files. The most common type of the eye injury was the corneo-scleral perforation. Ruptured globe in 13 eyes (5.7%). Other body injuries in 11 patients 4.8% (limb amputations and burns).

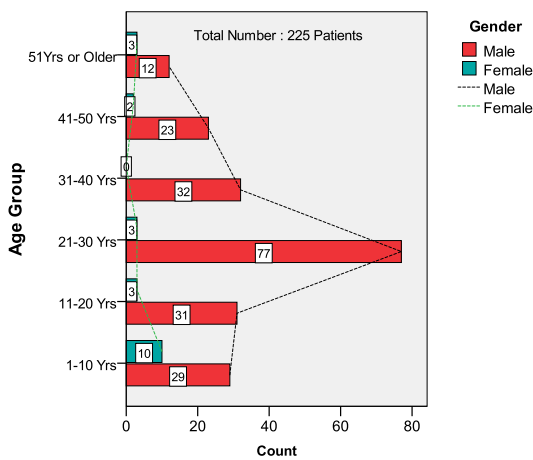
Visual outcome was favorable in non-perforating eye injury as compared with penetrating injuries that involve the posterior segment and in presence of intra-ocular

foreign body. 56.3% of patients achieved a visual acuity between 6/6 and 6/18. No perception of light was noted in 8.9%. However, final visual outcome could not be traced in some cases (Table 2).

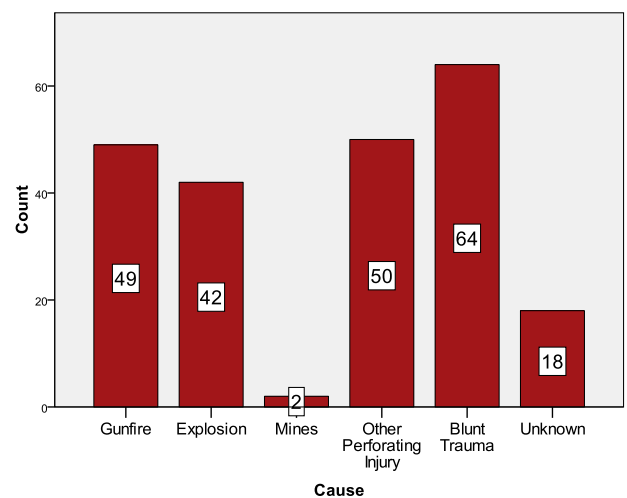
The treatment includes medical treatment and surgical treatment. Corneoscleral injuries were repaired in 72 eyes (32%) vitrectomy and cataract surgery was needed in 14 eyes (6.2%) and 12 eyes (5.3%) respectively. Three eyes (1.3%) were eviscerated.

**Table 1:** Gender and eye injury distribution

Injured eye		Gender	Age group						Total
			1-10 yrs	11-20 yrs	21-30 yrs	31-40 yrs	41-50 yrs	51 yrs or Older	
Rt eye	Gender	Male	14	17	40	13	11	6	101
		Female	6	2	2	0	1	1	12
		<b>Total</b>	<b>20</b>	<b>19</b>	<b>42</b>	<b>13</b>	<b>12</b>	<b>7</b>	<b>113</b>
Lt eye	Gender	Male	14	12	31	13	9	5	84
		Female	4	1	1	0	1	2	9
		<b>Total</b>	<b>18</b>	<b>13</b>	<b>32</b>	<b>13</b>	<b>10</b>	<b>7</b>	<b>93</b>
Both eyes	Gender	Male	1	2	6	6	3	1	19
		Female	0	0	0	0	0	0	0
		<b>Total</b>	<b>1</b>	<b>2</b>	<b>6</b>	<b>6</b>	<b>3</b>	<b>1</b>	<b>19</b>
<b>Total number of injured patients</b>								<b>225</b>	



**Figure 1:** Age and gender distribution

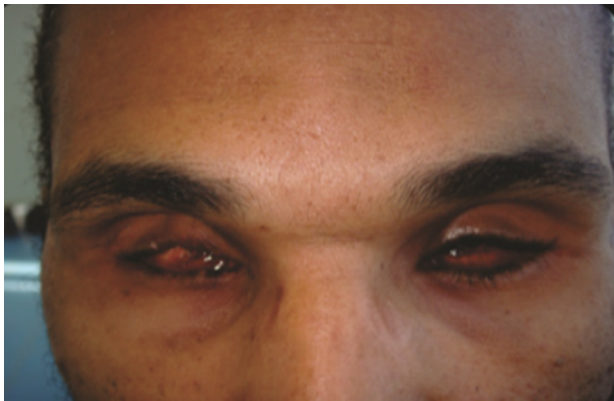

**Figure 2:** Causes of injury

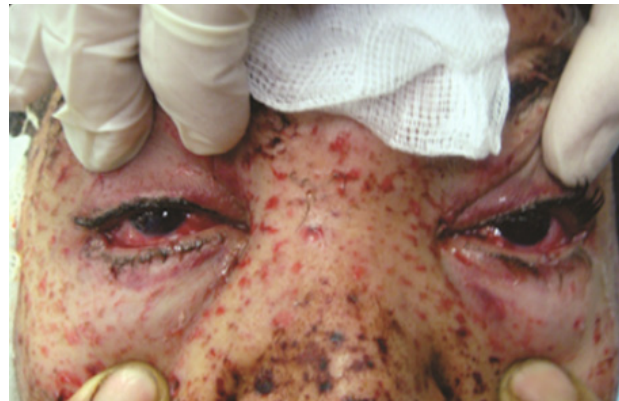**Table 2:** Visual equity in the right and left eye

		Vision Left						Total
		6/6 - 6/9	6/12 - 6/18	6/24 - 6/60	CF	HM and PL	No PL	
Vision right	6/6 - 6/9	37	6	15	9	22	4	93
	6/12-6/18	7	2	1	3	1	0	14
	6/24 - 6/60	15	1	1	1	1	0	19
	CF	8	0	4	2	1	0	15
	HM and PL	24	2	4	0	2	0	32
	No PL	12	0	0	1	2	2	17
<b>Total</b>		<b>103</b>	<b>11</b>	<b>25</b>	<b>16</b>	<b>29</b>	<b>6</b>	<b>190</b>





(a)



(b)

Figure 3 a,b: Bilateral ocular injury.

## DISCUSSION

War ocular injury is becoming increasingly common in different parts of the world. Ocular trauma victims are most commonly young males.<sup>1</sup> In our study 90.6% were young males aged between 20 to 30 years. Bilateral ocular injury in our study was 8.4%. Visual prognosis in the war ocular injury patients depends on the type and severity of the injury open eye injuries with IOFB had very poor visual outcome, patients with vision (hand movement in 16.8% and no perception of light in 8.9%.<sup>6</sup> The war injuries causes ocular with systemic injuries. In our study in 4.8% ranged from limb amputations, burns.

Some of the patients were admitted without listing the type of injury on the admission papers, whilst others were treated as outpatients.<sup>6</sup> In many cases vision of only injured eye was recorded. There is also underestimation of the number of minor injuries. During the same period the number of routine admissions drastically reduced, as routine work was cancelled and road accidents declined secondary to severe fuel shortage. Pediatric injuries were seen mostly secondary to common accidents such as falling or flying stone injuries.

## CONCLUSION

Visual prognosis for war ocular injury cases is poor, as many of patients had severe eye injury most of them need further interventions and visual rehabilitation.

## AKNOWLEDGEMENT

Great thanks to Drs; Milud Elaroud and Tarek Ezabi for their advice and comment. My thanks go to Drs; Fejra Khalifa, Tahani Ghnemi and Ieman Feghi for their help in data collection.

## REFERENCES

1. Gothwal VK, Adolph S, Jalali S and Naduvilath TJ (1999) Demography and prognostic factors of ocular injuries in south India, *Aus NZJ Ophthalmol.* **27**, 218-225.
2. Richard AZ (2004-2005) The American Academy of Ophthalmology (AAO), Section 13, Chapter 11, pp. 121-134.
3. Negrel AD and Thylefors B (1998) The global impact of eye injuries, *Ophthalmic Epidemiol.* **5**, 143-169.
4. Treister G (1969) Ocular casualties in Six Day War, *Am J Ophthalmol.* **68**, 669-675.
5. Jackson H (1996) Bilateral blindness due to trauma in Cambodia, *Eye* **10**, 517-520.
6. Friesen H, Asmat AA and Salim AG, Khan I (1990) Incidence of incurable blindness in the Afghan refugees in Pakistan, *Pak J Ophthalmol.* **6**, 61-63.
7. Weichel ED and Coyler MH (2008) Combat ocular trauma and systemic injury, *CurrOphthalmol.* **19**, 519-525.

