

## Diagnosis and Surgical Treatment of Carotid Body Tumor: a Case Report

Saleh Hadia<sup>1</sup>, Mohamed M. Saih<sup>2</sup> and Ammar Elgayed<sup>1@</sup>

<sup>1</sup>Department of General Surgery; <sup>2</sup>Department of Vascular Surgery, Tripoli Medical Center, Tripoli- Libya

Received 12 July 2013/Accepted 10 September 2013

### ABSTRACT

The study aimed to introduce our experience in the diagnosis and treatment of carotid body tumor (CBT). CBT was confirmed by incisional biopsy under local anaesthesia and histopathology finding. Resection of the tumor under the carotid adventitial plane was performed.

The result showed neither death nor any complication occurred in our case. Follow-up of the patient revealed neither recurrence nor metastasis. CBT should be considered in the differential diagnosis of neck lumps. Although digital subtraction angiography (DSA) is the gold standard for the diagnosis of CBT, it was not done in our case. We depended on the histopathology results. After confirmation, thorough perioperative examination, sufficient perioperative preparation and correct surgical approaches, will result in satisfactory surgical effect.

**Keywords** - Digital subtraction angiography (DSA); Potato tumor.

### INTRODUCTION

Carotid body tumor (CBT) is one of the most commonly seen jugular paraganglioma involving the carotid body chemoreceptors, but rarely clinically apparent, so the differential diagnosis and management remain difficult.

A 21 years old male patient with CBT was referred to us, from oncology department. We would like to investigate the experience in the diagnosis and management of CBT through a retrospective analysis of the clinical data.

#### Case Report

A 21 years old male patient was referred from oncology department, as left submandibular lymph node enlargement for biopsy. Main complaints were left neck swelling and dysphagia. Clinically, the patient had palpable mass about 4 to 5 cm below left submandibular angle. Laryngeal examination revealed bulged left tonsil. CT scan without contrast showed about 4 to 5 cm mass at the level of the carotid bifurcation, extended from lateral pharyngeal wall to the left mandibular angle.

#### Surgical technique

Under local anesthesia, incisional biopsy has been carried out and sent to histopathology unit. The result came out as carotid body tumor (Potato tumor).

Under general anesthesia, left laterally inclined incision along the anterior border of the sternomastoid muscle was performed intraoperatively. We found 4 to 5 cm mass occupying bifurcation of carotid artery, including external and internal carotid arteries. After clear visualization of the anatomic structures, such as the common carotid artery, the internal carotid vein, the cranial nerves, and, the accessory nerve; the common carotid artery and,

the internal and external carotid veins were sufficiently liberated for a good separation, then, the common carotid artery and the proximal end of the tumor artery were blocked, using blood vessel blocking bands for the convenient control of the blood flow and, finally they were carefully separated along the tumor body so that, the blood vessels feeding the tumor could be radically removed. Separation was performed with relatively separated tumor body from the artery under the carotid adventitial plane. The specimen was pathologically confirmed as carotid body tumor.

### RESULTS

Patient was discharged in third postoperative day with good wound healing. No postoperative complications were observed such as, cerebral ischemia or, nerve injuries. Patient was on regular follow-up for up to three years, without any complication, recurrence or, metastasis.

### DISCUSSION

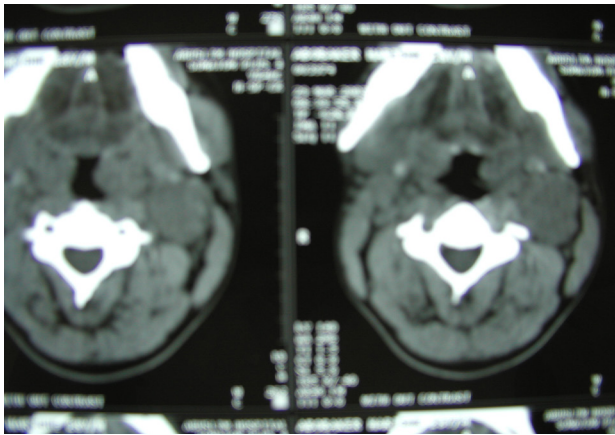
Carotid body tumors are a rare class of paraganglioma arising from the upper neck, but should be considered in the differential diagnosis of neck lumps. A wrong diagnosis of cervical lymphadenopathy, followed by excision biopsy may have serious consequences. The only way to minimize such consequences, is to be aware of their existence in the first place.<sup>1</sup>

The genetic etiology of carotid body tumors is suggested by the familial occurrence of the neoplasm, although, environmental influences are also implied by the fact that, the tumor is more common in those living at high altitudes. However, the development of sporadic tumors

occurring at sea level, which account for the majority of cases remains unknown.<sup>2</sup> It is usually asymptomatic but large masses may encroach upon the parapharyngeal space producing dysphagia, pain, and cranial nerve palsies.<sup>3</sup>

A surgical classification for carotid body tumors was proposed by Shamlin et al. in 1971.<sup>4</sup> Group I: tumors are relatively small with minimal attachment to the carotid vessels, and surgical excision can be performed safely. Group II: tumors are larger with moderate arterial attachments and can be resected with precise surgical dissection. Group III: tumors are large neoplasms, encasing the carotid arteries and can be resected only, with arterial sacrifice.<sup>4</sup>

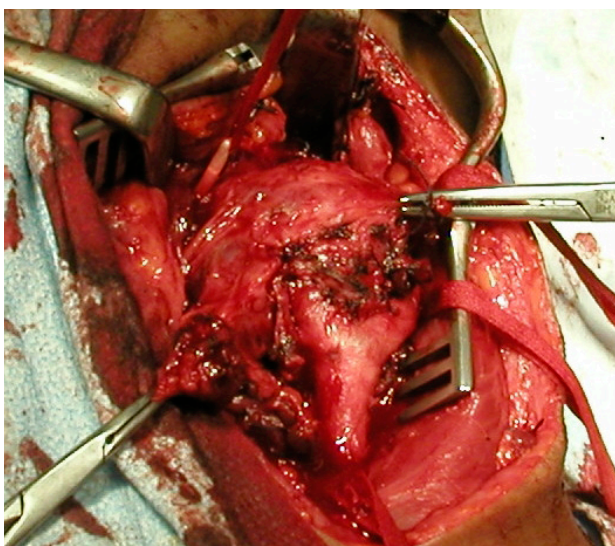
Contrast-enhanced CT scans (Figure 1) and MRI, demonstrate enhancing soft-tissue masses at characteristic locations key to the diagnosis.



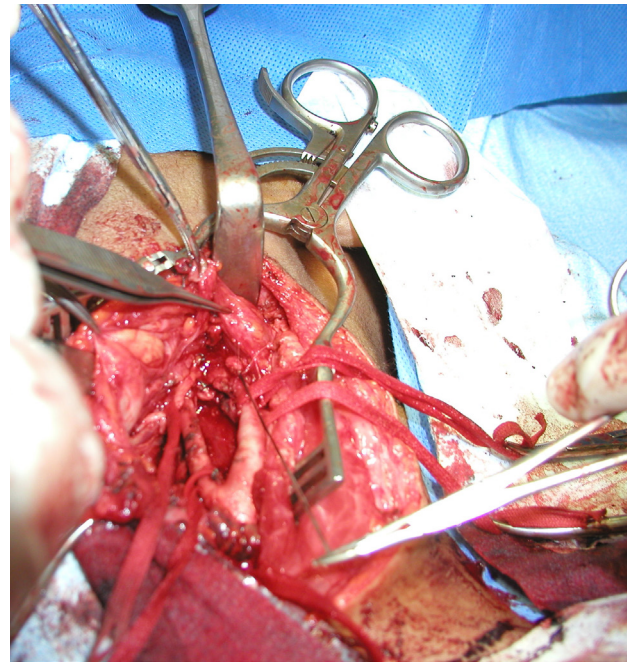
**Figure 1:** Preop CT scan.

Ultrasonography can demonstrate the extent of the masses and show their locations.<sup>5</sup> Arteriography, the gold standard for diagnosing CBTs, demonstrates a pathognomonic tumor blush, as well as, the feeding vessels of the tumor; and is an excellent screening tool for concomitant paragangliomas.<sup>6</sup>

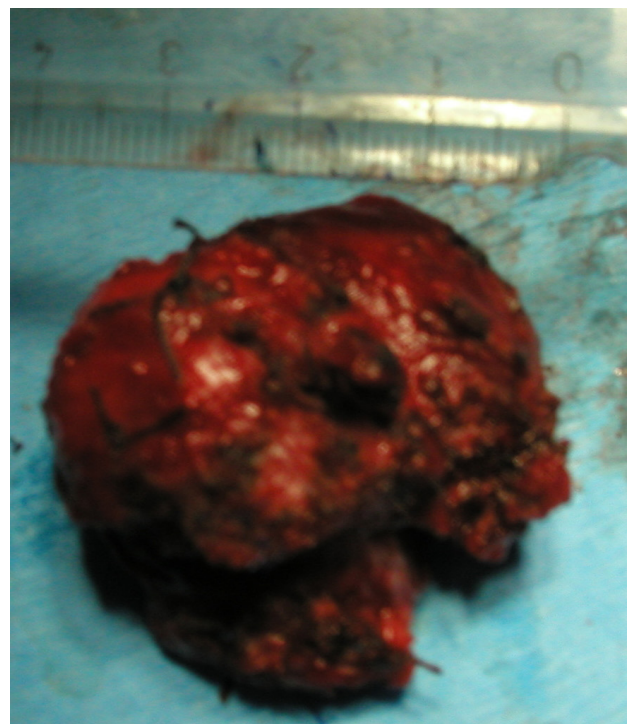
Surgical resection is the treatment of choice for carotid body tumors (Figures 2, 3 and 4).



**Figure 2:** Operative desected tumor.



**Figure 3:** Excised tumor.



**Figure 4:** Potato tumor.

Embolization immediately before surgery, decreases blood loss and facilitates tumor removal.<sup>7</sup> Early operative management is warranted to avoid the possibility of eventual metastasis and, progressive local invasion to the point of inoperability. In case of tumors intimately in contact with carotid arteries, the treatment by vascular surgeon is highly recommended.<sup>8</sup>

**REFERENCES**

- [1] Naughton J, Morley E, Chan D, Fong Y, Bosanquet D, Lewis M (2011) Carotid body tumours, *Br J Hosp Med* **72**(10), 559-564.
- [2] Wang DG, Barros D'Sa AA, Johnston CF, Buchanan KD (1996) Oncogene expression in carotid body tumors, *Cancer* **77**(12), 2581-2587.
- [3] DeVita Jr et al. (2007) *Cancer: Principles and Practice of Oncology*, 3rd edn, pp. 570-571.
- [4] Shamblin WR, Remine WH, Sheps SG, Harrison EG Jr (1971) Carotid body tumor (chemodectoma): clinicopathologic analysis of 90 cases, *Am J Surg.* **122**(6), 732-739.
- [5] Robert AK, Lawrence MD (2013) *Imaging of Head and Neck Glomus Tumors*. Medscape.
- [6] Dhiman DS, Sharma YP, Sarin N (2000) US and CT in carotid body tumor, *J Radiol Imaging* **10**, 39-40.
- [7] Wang SJ, Wang MB, Barauskas TM, Calcaterra TC (2000) Surgical Management of Carotid Body Tumors, *Otolaryngol Head Neck Surg* **123**(3), 202-206.
- [8] Davidovic LB, Djukic VB, Vasic DM, Sindjelic RP and Duvnjak SN (2005) Diagnosis and treatment of carotid body paraganglioma: 21 years of experience at a clinical center of Serbia, *World Journal of Surgical Oncology* **3**,10.