Tripolitana Medical Journal; 2018, Vol. 7, No. 1, pp. 11 - 18

Research Article

ISSN 2077-5628

Surgical Versus Non Surgical Treatment of Fractures of the Mandibular Condyle

Salah Eddin Kurdi[1,2@], **Adel Alsalami**[2] **and Hilal Nser**[1]

[1]Department of Oral and Maxillofacial, Faculty of Dentistry, University of Tripoli
[2]Abuslim Trauma Center, Tripoli, Libya

Received 19 February 2018 / Accepted 14 April 2018

ABSTRACT

The mandible is frequently injured after facial trauma, and 25 to 40% of mandibular fractures involve the condyle. Management of mandibular condylar fractures remains an ongoing matter of controversy in maxillofacial surgery. The current study was designed to assess significant differences in clinical outcomes between surgical and non surgical methods of treatment for mandibular condylar fractures.

The study consisted of 134 patients. 107 patients had non-isolated unilateral and 27 patients had bilateral condylar fracture. Surgical method (open reduction) was conducted in 56 patients with unilateral condylar fractures and 15 patients with bilateral condylar fracture. Non surgical method, (closed reduction) was done in 51 cases of unilateral and 12 cases of bilateral condylar fracture between 2005- 2015. In non surgical method 54 patients underwent maxillomandibular fixation with arch bars and 9 patients underwent maxillomandibular fixation using Ivy eyelet wiring under local anesthesia.

The maxillomandibular fixation was maintained for 2- 4 weeks. In surgical method, under general anesthesia; approaches used were submandibular in 13 cases. mini-retromandibular incision was used in 58 patients. Fixation was carried with 4 holes straight miniplate. Elastic maxillomandibular fixation was used for 5 to 7 days postoperatively only for patients with bilateral condylar fracture.

134 patients with condylar fractures were included in this study. Out of 134 patients 108 were males and 26 females. Road traffic accidents were the most common cause of trauma, 98 of 134 patients (73%), gunshot, 26 patients (19.5%), work injury, 6 patients (4.5%), and sports injury 4 patients (4.5%). The age distribution showed a typical peak between 20 and 40 years (70%). There were 103 subcondylar fractures (77%), 16 cases (12%) were condylar head (intracapsular) fracture and 15 (11%) was condylar neck fracture. There were 15 associated other mandibular fracture (body, angle, parasymphysis (12%); and the rest were isolated condylar fractures (92 patients had unilateral and 27 patients had bilateral condylar fracture).

Fracture without displacement of the mandibular condyle neck, traditionally been managed with non surgical method (closed reduction technique) and the functional result of the non surgical method is dependent entirely on the accidental position of the fragments.

Any of the following points was an indication for surgical method (open reduction);

- A unilateral fracture with considerable overriding of the fragments.
- A bilateral fracture with considerable overriding and resultant open bite.
- Gross malalignment of condylar fragment i.e. situated at an angle to the ramus and projecting over it.
- A position of the condyle that causes interference with the movement of the jaw or limits its opening.

Key words- *Condyle fracture; ORIF*.

INTRUDACTION

The mandible is frequently injured after facial trauma, and 25 to 40% of mandibular fractures involve the condyle.[1-3] Management of mandibular condylar fractures remains an ongoing matter of controversy in maxillofacial surgery. This controversy is reflected in the wide variety of opinions and proposed treatment modalities offered in the literature.[4] For decades, closed reduction has been the preferred treatment because treatment is easier and less invasive,[5] and the results are comparable, with no surgical complications. However, closed reduction may comprise varying periods of intermaxillary fixation (IMF) (0 to 6 weeks) followed by aggressive physiotherapy.[6] In addition, long-term complications such as pain, arthritis, malocclusion, deviation of the mandible on opening and closing movements, temporomandibular joint (TMJ) dysfunction, facial asymmetry, and ankylosis may occur in patients with condylar injuries treated in a closed manner.[6,7] If there is severe displacement or dislocation, surgical management seems to be preferred.[8-10] Open reduction–internal fixation (ORIF) allows anatomic repositioning and immediate functional movements of the jaw,[11] but has the potential complications of damaging the facial nerve and of forming visible scars.[4] With the implementation of rigid internal fixation over the past 30

@ Author to whom correspondence should be addressed: Dr Salah Eddin Kurdi;*Tel:00218925229492*; *E-mail:* kurdisalah@hotmail.com

years, the indications for surgical treatment of mandibular condylar fractures have broadened.

Although there are various guidelines regarding the management of condylar fractures of the mandible by open reduction or closed reduction, there is still continuing debate over how to best manage these fractures.

This is attributable in part to a potential misinterpretation of the literature from decades prior, a lack of uniformity of classification of the various anatomic components of the mandibular condyle, a lack of scientifically valid studies comparing treatments, and a perceived potential to cause harm through the open approach based in part on the surgeon's lack of experience and critical examination of the literature.[12]

Other factors confounding the strategy for the management of condylar fractures are the anatomic position of these fractures; the influence of the fractures and surgery on facial growth; and the potential complications, such as malocclusion, chin deviation, ankylosis of the TMJ, and internal derangement of the joint.[5,13]

This study had several limitations. Fourteen of the studies that were used in our analysis included patients with associated mandibular and midface fractures.[4,12,14-24] It is believed that a second fracture of the mandible can confound the outcome data because the fixation requirements for a double fracture are often different from those for an isolated fracture.[25] Biomechanically, a mandible with bilateral condylar fractures is a much more complicated construct than one with a unilateral condylar fracture. Rehabilitating such patients using closed reduction is more difficult because of the deficiency in structural support from the lack of both craniomandibular articulations. We included patients with bilateral fractures because some of the studies had included these patients and they were impossible to separate. Theoretically, their inclusion can blur the data because some of the measures (laterotrusion, protrusion, deviation on opening) make less sense when used for patients with bilateral fractures of the condyle. However, the number of patients with bilateral fractures was small.

MATERIALS AND METHODS

The study consisted of 134 patients. 107 patients had unilateral fractures and 27 patients had bilateral condylar fracture. Surgical method was carried out in 56 patients with unilateral condylar fractures and 15 patients with bilateral condylar fracture. Non surgical method was done in 51 cases of unilateral and 12 cases of bilateral condylar fracture between 2005- 2015. In non surgical 54 patients underwent maxillomandibular fixation with arch bars and 9 patients underwent maxillomandibular fixation using Ivy eyelet wiring under local anesthesia. The maxillomandibular fixation was maintained for 2-4 weeks. In surgical method, under general anesthesia; approaches used were submandibular in 13 cases; mini-retromandibular incision was used in 58 patients. Fixation was carried with 4 holes straight miniplate. Elastic maxillomandibular fixation was used for 5 to 7 days postoperatively only for patients with bilateral condylar fracture. Postoperative instructions regarding mouth-opening exercises and physiotherapy were given to all the patients in both groups.

The radiographic examination included standard Orthopantomogram (OPG), CT scan that were taken after trauma and 3 months or more after completion of the treatment. The two groups were compared for their pre-operative and post-operative mouth opening, lateral movements and occlusion with a follow up period of 3 to 12 months.

RESULTS

134 patients with condylar fractures were included in this study. Out of 134 patients 108 were males (80.6%) and 26 females (19.4%).

Road traffic accidents were the most common cause of trauma, 98 of 134 (73.0%). Gunshot 26 patients (19.5%). Work injury 6 patients (4.5%). Sports injury 4 patients (4.5%).

Age range in 7 patients is from 1 day to 10 yrs (5.5%), in 20 patients from 11-20 yrs (15.0%), in 70 patients from 21 -30 yrs (52.0%), in 24 patients from 31-40 yrs (18.0%), in 6 patients from 41-50 yrs (4.5%), from 51-60 yrs in 4 patients (3.0%), and in 3 patients from 61 yrs to 70 yrs (2.0%).

96 patients (71.6%), reside within the city limits of Tripoli and remaining 38 patients, (28.4%) came the from rural areas. 54 patients, (40.0%) were referred from other hospitals.

There were 103 subcondylar fractures (77.0%), 16 cases (12.0%) were condylar head (intracapsular) fracture (Figures 1, 2) and 15 (11.0%) was condylar neck fracture (Figure 3).

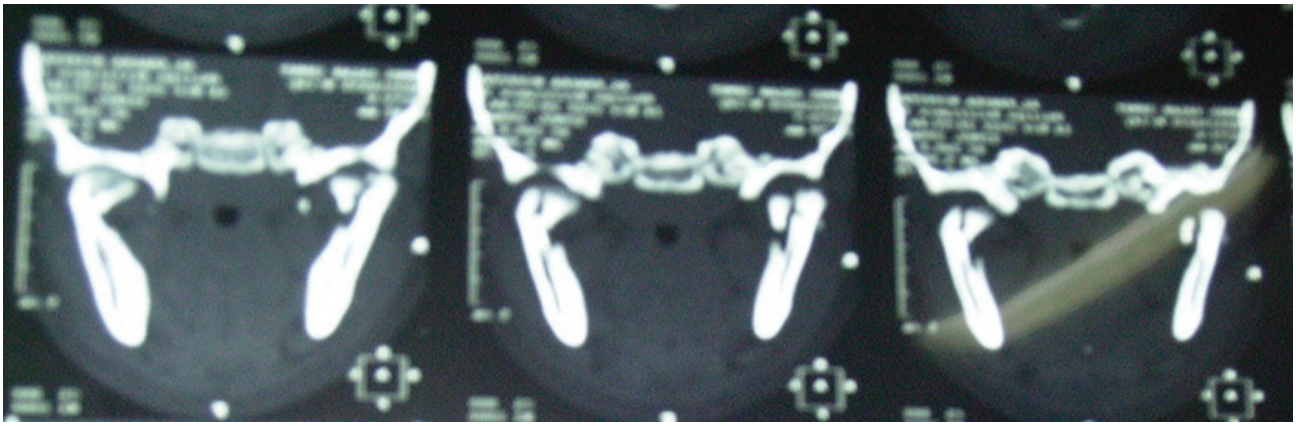

Figure 1: Bilateral condyles fracture with displacement (condylar head).

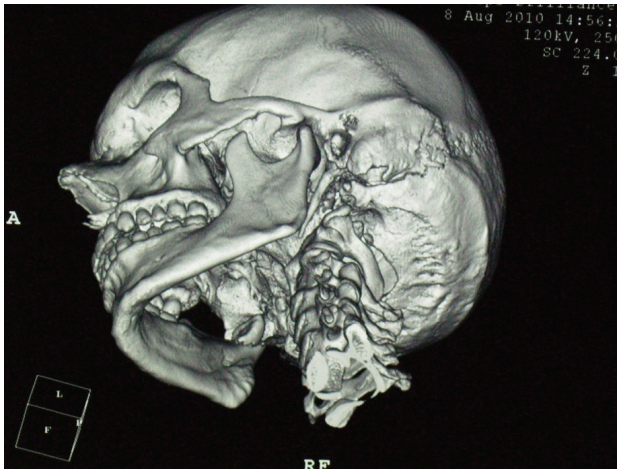

Figure 2: Condylar head fracture. 3D view.

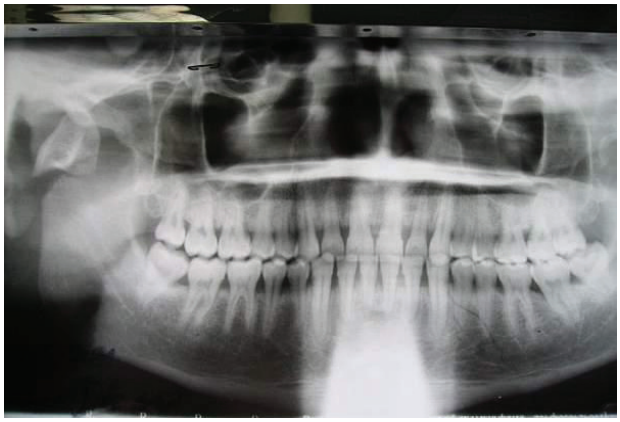

Figure 3: Unilateral fracture of subcondyl with displacement right side

There were 56 condylar fractures with medial displacement (41.8%), 46 fractures with lateral displacement (34.3%), and 32 mandibular condyl fractures without displacement (23.9%).

There were 15 associated other mandibular fracture (body, angle, mentone (12%) (Figure 4); and the rest were isolated condylar fractures (92 patients had unilateral and 27 patients had bilateral condylar fracture) (Figure 1).

Figure 4: Bilateral fracture of subcondyl with displacement left side and mentone right side

Among the 134 patients, 63 (47%) underwent non surgical (closed reduction) which included maxillomandibular fixation ranging from 2-4 weeks followed by active mouth opening exercise (Figure 5).

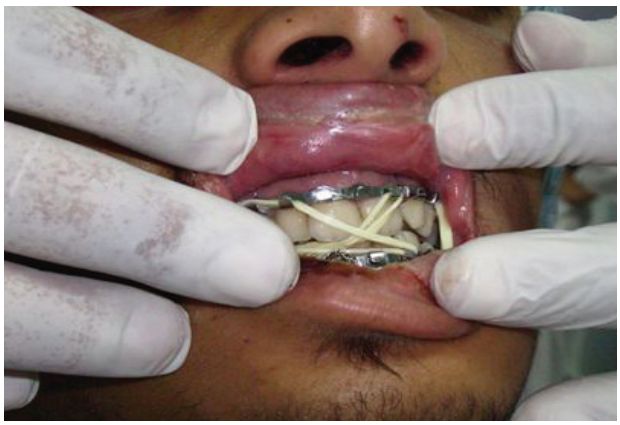

Figure 5: Non surgical (close reduction with elastic inter maxillary fixation)

The other 71 (53%) underwent surgical method (open reduction and internal fixation) with 2 mm titanium straight miniplate (Figures 6,7).

Figure 6: Surgical method (open reduction and internal fixation) for Condyles fracture (intra operative pictures)

Figure 7: Surgical method -open reduction and internal fixation for condyles fractures.

Postoperative instructions regarding mouth-opening exercises and physiotherapy were given.

Follow up period ranged from 3-12 months. Functional recovery after non-surgical and surgical treatment showed satisfactory results.

Rowe and Williams[26] consider 35 mm of interincisal distance is a very satisfactory value for mouth opening. The maximum interincisal opening ranged from 31- 40 mm in patients who underwent closed reduction. Among these, 7 patients (11%) had reduced mouth opening of 31 mm, while in the open reduction group none of them had limited mouth opening, least being 36 mm (Figure 8).

Figure 8: Maximal interincial opening

Clicking of the temperomandibular joint on mouth opening was absent in both the groups.

Lateral excursive movements were within normal limits for both groups. No pains on lateral excursive movements were elicited in both groups.

No malocclusion was also noticed in both groups (Figure 9), and no significant mandibular deviation was noted in both groups (Figure 10).

Figure 9: Postoperative normal mouth occlusion

Figure 10: No significant mandibular deviation

Pain in the temperomandibular joint was noted in 14 (20%) patients during the immediate postoperative period treated by open reduction. 24 patients (38%) treated by closed reduction had persistent pain in the temperomandibular joint for first month which later subsided gradually.

9 patients (12.7%) were noticed with transient facial nerve weakness of marginal mandibular branch following open reduction and internal fixation, which subsided within a period of 2 weeks (Figure 11).

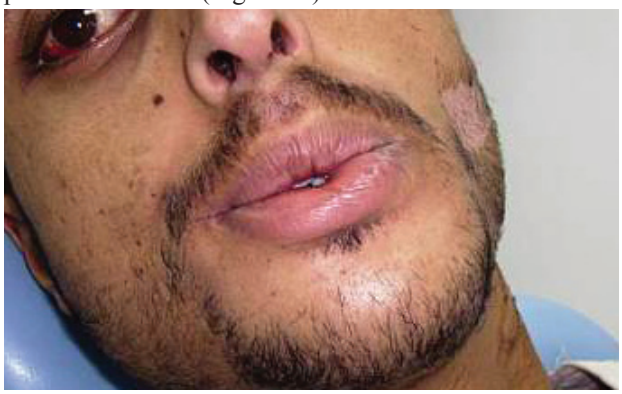

Figure 11: Normal function of facial nerve branches

Postoperative infection, wound dehiscence and unaesthetic scarring was noted in 3 patients (4.2%) in the surgical group at the submandibular incision sites.

DISCUSSION

The incidence of fracture involving the mandibular condyle varies throughout the literature. Early reports revealed an incidence as low as 8% of the mandibular fractures with later reports claiming as high as 50%.[27]

P Marker et al[28] in his study of patients with mandibular fractures, found that 41% had a fracture of one or both condyles. Men were most commonly affected (M: F: 2:1). Unilateral fractures were more common (72%) than bilateral (28%). Subcondylar fractures were the most common, both in unilateral and bilateral group. In our study the most affected patients were male (80.6%). Unilateral fractures were the most common (79.9%), than

bilateral fractures (20.1%). Subcondylar region was the most common site of fracture.

Pedro M. Villarreal et al[29] in his study found that traffic accidents was the most frequent cause in all ranges of age, the second in frequency was sports injury in children and teenagers and causal accidents in adults.

By gender, the most frequent etiology was traffic accidents in both men and women. The second most common cause was altercations in men and causal accidents in women. In our study road traffic accidents were the most common cause (73%).

Lindahl[30] (1977) found that all types of condylar fracture irrespective of occlusion and that of the location of the most distal occlusal contact did not influence the type or magnitude of dislocation of the condylar fragment. One third of patients with condylar fractures also sustained injuries to the teeth and the same study showed that, in patients with unilateral fractures, injuries to the teeth were more often seen with intracapsular fractures than with subcondylar fractures.

Condylar fractures have been variously classified by different authors. Brophy (1915) classified fractures of the condylar process by the location and direction of the fracture.[26] Thoma (1945) categorized mandibular condyle fractures by the degree of displacement as well as dislocation into 4 types.[26] Mac Lennan (1952) gave clinical classification depending on the degree of displacement into 4 types. Rowe and Killey (1955) devised a classification based on relationship of the temperomandibular joint capsule and concomitant injury as Intracapsular or high condylar fractures, extracapsular or low condylar or subcondylar fractures, fractures associated with injury to the capsule, ligment and meniscus and fractures involving the adjacent bone.[26] Dingman and Natvig (1964) classified the fractures of the condylar process as high, middle and low.[26] High fractures occurred at or above the level of the lateral pterygoid muscle; middle, below this attachment; and low at the base of the condylar process. Spiessel and Schorell (1972) classified condylar fractures into 6 types based on the site of fracture, displacement and dislocation.[26,27,30]

The different schools of thought concerning the basic philosophy of the management of condylar factures are (1) conservative and functional or (2) surgical methods.[26, 27]

Zide and Kent's (1983) report regarding the indication for open reduction of mandibular fractures has been the "gold standard" for the past decade and half.[15]

Absolute indications were when there was displacement into middle cranial fossa, impossibility of obtaining adequate occlusion by closed reduction, lateral extracapsular displacement and invasion by foreign body (e.g. gunshot wound).

The relative indications were in cases of bilateral fractures in edentulous patients without a splint, unilateral or bilateral condylar fractures where splinting cannot be accomplished for medical reasons or because physiotherapy is impossible, periodontal problems, loss of teeth, unilateral condylar fractures with unstable base. Zide (1989) added open fracture with potential for fibrosis in the list of absolute indications.[30]

AAOMS special committee on parameters of care gave the following Indications for open reduction (2001) Physical evidence of fracture, imaging evidence of facture, malocclusion, mandibular dysfunction, abnormal relationship of jaws, presence of foreign bodies, laceration and /or hemorrhage in external auditory canal, hemotympanum, cerebrospinal fluid otorrhea, effusion, hemarthrosis.[30]

Johannes Hidding[31] et al (1992), in his study on surgical versus non-surgical treatment of fracture condyle, the results were nearly equal in both the groups. They concluded that surgery should be performed whenever the vascular supply of the displaced part of the condyle is compromised and hence recommended open reduction in cases of dislocated subcondylar or neck fractures.

Luc M.H. Smets[32] et al in their study on non-surgical treatment of fracture condyle in adults concluded that it was fair to consider surgical repositioning and rigid internal fixation in selected patients with shortening of the ascending ramus of 8mm or more; or when considerable displacement or angulation in a coronal and or sagittal plane is present.

Edward Ellis[33] et al (2000) stated that open treatment must involve fixation that is sufficiently stable to allow full active function immediately after surgery. For the vast majority of fractures in their study much stronger titanium plates with bicortical screws were used, the use of miniplate should be avoided if active use of the jaw is desired, because a certain number of them will fracture.

According to Rowe and Williams[26] interincisal mouth opening of 35mm is considered as satisfactory value for mouth opening. Urpo Silvennoinen et al (1994) in their study on 92 dentate patients treated non-surgically for unilateral condylar fractures, after an average follow up 14 patients had limited mouth opening after release of maxillomandibular fixation. With functional training all of these patients achieved normal mouth opening (> 40 mm).[25]

Hyde. N[34] et al (2002) in their study of 54 patients of condylar fractures, 33 underwent open reduction and 21-closed reduction. Mouth opening varied between the two groups. In the open reduction group the mean interincisal opening was 42 mm and in the closed group the mean was 32 mm.

Essam A Almoraissi and Edward Ellis[35] (2015) in their study used results of fifteen studies compared mouth interincisal opening between the closed reduction (n = 464) and open reduction and internal fixation (n = 332) groups.[1,14,15,20,24,36,39,40] There was a statistically significant advantage for the open reduction and internal fixation group. For instance, this meta-analysis showed that open reduction and internal fixation patients had a greater postoperative mouth interincisal opening than patients treated with closed reduction. This finding is consistent with some studies[7,17,21,22,31,33,36,41] and inconsistent with others.[4,14,23,24,36,39]

In our study the mouth interincisal opening ranged from 31- 40mm in patients who were treated by closed reduction

and 36- 45mm in those treated by open reduction and internal fixation. 7 patients (11%) treated conservatively had reduced mouth opening of 31mm.

G. De Riu[1] et al (2001) in their comparative studies observed no significant differences in the two groups for protrusive, lateral, or opening movements. Both groups showed similar signs of mandibular recovery and absence of muscular and joint pain.

Nils Worsaae and Jens J, Thorn[42] (1994) in their study found no significant difference in, mouth opening or laterotrusive or protrusive movement between the two groups.

Yasuharu Takenoshita[43] et al (1990): in their comparative study found all patients maintained an adequate inter-occlusal relation, with good occlusal contacts. Generally, acceptable function of the joint was acquired in all cases.

Essam A Almoraissi and Edward Ellis[35] (2015) in their systematic review and meta-analysis study found the laterotrusive movement was better in open reduction and internal fixation patients, indicating better condylar motion (WMD, 1.14 mm; 95% CI, 0.73 to 1.55 mm; *P* = .001).

This finding is compatible with the results of some studies,[23,37,38,44] but disagrees with the results of others.[21,22,39] In addition, the open reduction and internal fixation group had greater protrusive movement than the closed reduction group (WMD, 0.99 mm; 95% CI, 0.70 to 1.29 mm; *P* = .001), similar to the results of previous literature[15,18,23,37,38,40,44] and opposite to others.[22,39] Chin deviation toward the fractured side on mouth opening was lower in the ORIF group than in patients treated with closed reduction. This finding also indicates that the mobility of the condyle on the fractured side is better in patients treated in an open manner. The OR was 0.62, meaning that using open reduction and internal fixation in the treatment of mandibular condylar fractures decreases the incidence of chin deviation by 38% compared with using closed reduction. This finding is in agreement with most studies.[4,18,37,44] Concerning occlusal discrepancies, the open reduction and internal fixation group was superior regarding reducing postoperative malocclusion (OR,0.41 mm; 95% CI, 0.26 to 0.62 mm; *P* = .001). This finding is in accordance with most previous results.[14,16-19,21,24,38, 45,46,]

The 5 studies that assessed pain on a VAS 6 months or more after treatment showed better pain reduction in the open reduction and internal fixation group.[37,18,23,40] In addition, the results of our study showed that there was an advantage for open reduction and internal fixation in reducing TMJ pain, noise, and clicking but this advantage did not reach a statistically significant level.

The OR was 0.57, meaning that using open reduction and internal fixation in the treatment of mandibular condylar fractures decreases the incidence of TMJ pain, tenderness, noise, and clicking by 43% compared with using closed treatment.

In our study lateral excursive movements were within normal limits and painless for both groups. No significant mandibular deviation nor malocclusion was noted.

Pain in the temperomandibular joint was noted in 14 (20%) patients in the immediate post operative period treated by open reduction, which subsided within a week while 24 patients (38%) treated by close reduction had persistent pain for first one month which later got subsided. Early recovery of function in relation to mastication and speech were found in patients treated by open reduction when compared to patients treated with closed reduction.

Manisali [47] et al (2003) in their study came across temporary facial nerve weakness in 30% of their cases that resolved within 3 months. Edward Ellis (2000)[9] in his study came across (17.2%) patients with facial nerve weakness, which resolved in 6 months. 9 patients (12.7%) treated by open reduction and internal fixation had a transient facial nerve weakness, which subsided within a period of 2 weeks. This could be attributed to neuroedema due to intra operative hemorrhage.

M.F. Devlin[41] et al (2000) in their study on open reduction by a retromandibular approach, one (2.5%) patient developed a hypertrophic scar and 3 (7.5%) patients had transient facial nerve weakness.

Essam A Almoraissi and Edward Ellis[35] (2015) in their systematic review and meta-analysis study used 10 studies evaluated nerve VII function after ORIF of condylar fr actures.[8,14,15,18,22,36,45,48,49]The incidence of facial nerve injury ranged from 0 to 21%, but it was temporary in most of the patients. Overall, from the available data,22 of 265 patients treated with ORIF (5.83%) had postoperative facial nerve weakness; however, in the vast majority of the cases, the nerve function totally recovered in less than 6 months (16 of 22 patients).

Data about unacceptable scarring were limited, but in most studies, the scar was described as imperceptible and acceptable by the patient.[49]

In our study postoperative infection, wound dehiscence and unaesthetic scarring were noted in only 3 patients (4.2%) who was treated by open reduction and internal fixation by a submandibular approach, but scar acceptable by the most patients.

Patients treated by open reduction and rigid internal fixation had the advantage of more rapid return to pre-traumatic occlusion and enhanced nutrition. On the other hand non-surgically treated patients required prolonged maxillomandibular fixation with periodic adjustments of elastics.

CONCLUSION

1. Fracture without displacement of the mandibular condyle neck, traditionally been managed with non surgical method (closed reduction technique) and the functional result of the closed reduction is dependent entirely on the accidental position of the fragments.

2. Any of the following points was an indication for surgical method (open reduction);

- A unilateral fracture with considerable overriding of the fragments.
- A bilateral fracture with considerable overriding and resultant open bite.

- Gross malalignment of condylar fragment i.e. situated at an angle to the ramus and projecting over it.
- A position of the condyle that causes interference with the movement of the jaw or limits its opening.

REFERENCES

1. De Riu G, Gamba U, Anghinoni M and Sesenna E (2001) A comparison of open and closed treatment of condylar fractures: A change in philosophy, *Int J Oral Maxillofac Surg* **30**, 384-391.

2. Marker P, Nielsen A and Bastian HL (2000) Fractures of the mandibular condyle. Part 1: Patterns of distribution of types and causes of fractures in 348 patients, *Br J Oral Maxillofac Surg* **38**, 417-429.

3. Ellis E and Throckmorton GS (2005) Treatment of mandibular condylar process fractures: Biological considerations, *J Oral Maxillofac Surg* **63**, 115-124.

4. YangWG, Chen CT, Tsay PK and Chen YR (2002) Functional results of unilateral mandibular condylar process fractures after open and closed treatment, *J Trauma* **52**, 498-509.

5. Brandt MT and Haug RH (2003) Open versus closed reduction of adult mandibular condyle fractures: A review of the literature regarding the evolution of current thoughts on management, *J Oral Maxillofac Surg* **61**, 1324-1331.

6. Suzuki T, Kawamura H, Kasahara T, *et al*. (2004) Resorbable poly-Llactide plates and screws for the treatment of mandibular condylar process fractures: A clinical and radiologic follow-up study, *J Oral Maxillofac Surg* **62**, 919-927.

7. Singh V, Bhagol A, Goel M, *et al.* (2010) Outcomes of open versus closed treatment of mandibular subcondylar fractures: A prospective randomized study, *J Oral Maxillofac Surg* **68**, 1304-1311.

8. Manisali M, Amin M, Aghabeigi B, *et al* (2003) Retromandibular approach to the mandibular condyle: A clinical and cadaveric study, *Int J Oral Maxillofac Surg* **32**, 253-261.

9. Sagiura T, Yamamoto K, Murakami K, *et al.* (2001) A comparative evaluation of osteosynthesis with lag-screws, miniplates, or Kirschner wires for mandibular condylar process fractures, *J Oral Maxillofac Surg* **59**, 1161-1172.

10. Iizuka T, L€adrach K and Geering AH. (1998) Open reduction without fixation of dislocated condylar process fractures: Long-term clinical and radiologic analysis, *J Oral Maxillofac Surg* **56**, 553-562.

11. Undt G, Kermer C, Rasse M, *et al*. (1999) Transoral miniplate osteosynthesis of condylar neck fractures, *Oral Surg Oral Med Oral Pathol Oral Radiol Endod* **88**, 534-541.

12. Haug RH and Brandt MT (2007) Closed reduction, open reduction, and endoscopic assistance: Current thoughts on the management of mandibular condyle fractures, *Plast Reconstr Surg* **120**, 90S.

13. Assael LA (2003) Open versus closed treatment of adult mandibular condyle fractures: An alternative interpretation of the evidence, *J Oral Maxillofac Surg* **61**, 1333-1341.

14. Worsaae N and Thorn JJ. (1994) Surgical versus nonsurgical treatment of unilateral dislocated low subcondylar fractures: A clinical study of 52 cases, *J Oral Maxillofac Surg* **52**, 353-362.

15. Palmieri C, Ellis E and Throckmorton G (1999) Mandibular motion after closed and open treatment of unilateral mandibular condylar process fractures. *J Oral Maxillofac Surg* **7**, 764-771.

16. Ellis E, Simon P and Throckmorton GS (2000) Occlusal results after open or closed treatment of fractures of the mandibular condylar process, *J Oral Maxillofac Surg* **58**, 260-268.

17. Hlawitschka M, Loukota R and Eckelt U (2005) Functional and radiological results of open and closed treatment of intracapsular (diacapitular) condylar fractures of the mandible, *Int J Oral Maxillofac Surg***34** , 597-607.

18. Eckelt U, Schneider M, Erasmus F, *et al*. (2006) Open versus closed treatment of fractures of the mandibular condylar process a prospective randomized multi-centre study, *J Craniomaxillofac Surg* **34**, 306-313.

19. Landes CA and Lipphardt R (2006) Prospective evaluation of a pragmatic treatment rationale: Open reduction and internal fixation of displaced and dislocated condyle and condylar head fractures and closed reduction of non-displaced, non-dislocated fractures Part II: High condylar and condylar head fractures, *Int J Oral Maxillofac Surg* **35**, 115-128.

20. Ishihama K, Iida S, Kimura T, *et al.* (2007) Comparison of surgical and nonsurgical treatment of bilateral condylar fractures based on maximal mouth opening, *Cranio* **25**, 16-25.

21. Landes CA, Day K, Lipphardt R and Sader R (2008) Prospective closed treatment of non displaced and non-dislocated condylar neck and head fractures versus open reposition internal fixation of displaced and dislocated fracture, *Oral Maxillofac Surg* **12**, 79-90.

22. Landes CA, Day K, Lipphardt R and Sader R (2008) Closed versus open operative treatment of nondisplaced diacapitular (Class VI) fractures, *J Oral Maxillofac Surg* **66**, 1586-1594.

23. Schneider M, Erasmus F, Gerlach KL, *et al.* (2008) Open reduction and internal fixation versus closed treatment and mandibulomaxillary fixation of fractures of the mandibular condylar process: A randomized, prospective, multicenter study with special evaluation of fracture level, *J Oral Maxillofac Surg***66** , 2537-2546.

24. Kotrashetti SM, Lingaraj JB and Khurana V (2013) A comparative study of closed versus open reduction and internal fixation (using retromandibular approach) in the management of subcondylar fracture, *Oral Surg Oral Med Oral Pathol Oral Radiol* 115, e7.

25. Ellis E (2013) Open reduction and internal fixation of combined angle and body/symphysis fractures of the mandible: How much fixation is enough? *J Oral Maxillofac Surg* **71**, 726-735.

26. Rowe and Williams (1994) Textbook of Maxillofacial injuries, Volume 1, Churchill Livingstone, 405-470.

27. Raymond J Fonseca (1997) Textbook of Oral and Maxillofacial Surgery. 2nd edition Volume 1, WB Saunders, 527-567.

28. Suzuki T, Kawamura H, Kasahara T, *et al.* (2004) Resorbable poly-Llactide plates and screws for the treatment of mandibular condylar process fractures: A clinical and radiologic follow-up study, *Journal of Oral and Maxillofacial Surgery* **62**, 919-927.

29. Pedro M..Villareal., Florencio Monje., Luis M. Junquera., Jesus Mateo and Cristina Gonzalez (2004) Mandibular condyle factures: determinants of treatment and outcome, *Journal of Oral and Maxillofacial Surgery* **62**, 155-163.

30. Todd M. Brandt, and Richard H. Haug (2003) Open versus closed reduction of adult mandibular condyle fractures: a review of literature regarding the evolution of current thoughts on management, *Journal of Oral and Maxillofacial Surgery* **61**, 1324-1332.

31. Johannes Hidding., Raphael Wolf., and Dieter Pingel (1992) Surgical versus non-surgical treatment of fractures of the articular process of the mandible. *Journal of Cranio-Maxillofacial Surgery*. 20, 345-357.

32. Luc M. H., Smets., Philip A., Van Damme and Paul Stoelinga

(2003) Non-surgical treatment of condylar fractures in adults: A retrospective analysis, *Journal of Cranio-Maxillofacial Surgery* **31**, 162-167.

33. Edward Ellis, Patricia Simon and Gaylord S. Throckmorton (2000) Occlusal results after open or closed treatment of fractures of the mandibular condylar process, *Journal of Oral and Maxillofacial Surgery*. **58**, 260-268.

34. Hyde N, Mainsali., M,B. Aghabeigi., Sneddon K., and Newman. (2002) The role of open reduction and internal fixation in unilateral fractures of the mandibular condyle. A prospective study, *British Journal of Oral and Maxillofacial Surgery* **40**, 19-26.

35. Essam A Almoraissi and Edward Ellis (2015) Surgical treatment of adult mandibular condylar fractures provides better outcomes than closed treatment: A systematic review and meta-analysis, *Journal of Oral and Maxillofacial Surgery* **73**, 482-493.

36. Santler G, Karcher H, Ruda C and Kole E (1999) Fractures of the condylar process: Surgical versus nonsurgical treatment. *J Oral Maxillofac Surg* **57,** 392-400.

37. Haug RH and Assael LA (2001) Outcomes of open versus closed treatment of mandibular subcondylar fractures, *J Oral Maxillofac Surg* **59**, 370-381.

38. Danda AK, Muthusekhar MR, Narayanan V*, et al. (*2010) Open versus closed treatment of unilateral subcondylar and condylar neck fractures: A prospective, randomized clinical study, *J Oral Maxillofac Surg* **68**, 1238-1245.

39. Sforza C, Ugolini A, Sozzi D, *et al*. (2011) Three-dimensional mandibular motion after closed and open reduction of unilateral mandibular condylar process fractures, *J Craniomaxillofac Surg* **39**, 249-257.

40. Gupta M, Iyer N, Das D and Nagaraj J (2012) Analysis of different treatment protocols for fractures of condylar process of mandible, *J Oral Maxillofac Surg* **70**, 83-92.

41. Devlin M.F., Hislop W.S. and Carton T.M (2002) Open reduction and internal fixation of fractured mandibular condyles by a retromandibular approach. Surgical morbidity and informed consent, *British Journal of Oral and Maxillofacial Surgery* **40**, 23-31.

42. Nils Worsaae and Jens J. Thorn (1994) Surgical versus nonsurgical treatment of unilateral dislocated low subcondylar fractures: a clinical study of 52 cases, *Journal of Oral and Maxillofacial Surgery* **52**, 353-360.

43. Yasuharu Takenoshita., Hiroaki Ishibashi., and Masuichiro Oka (1990) Comparison of functional recovery after nonsurgical and surgical treatment of condylar fractures, *Journal of Oral and Maxillofacial Surgery*. **48**, 1191-1199.

44. Stiesch-Scholz M, Schmidt S, Eckardt A (2005) Condylar motion after open and closed treatment of mandibular condylar fractures, *J Oral Maxillofac Surg* **63**, 1304-1310.

45. Oezmen Y, Mischkowski RA, Lenzen J and Fischbach R (1998) MRI examination of the TMJ and functional results after conservative and surgical treatment of mandibular condyle fractures, *Int J Oral Maxillofac Surg* **27**, 33-41.

46. Singh V, Bhagol A and Dhingra R (2012) A comparative clinical evaluation of the outcome of patients treated for bilateral fracture of the mandibular condyles, *J Craniomaxillofac Surg* **40**, 464-472.

47. Manisali M., Amin-M., Aghabeigi B., and Newman L. (2003) Retromandibular approach to the mandibular condyle: A clinical and cadaveric study, *International Journal of Oral and Maxillofacial Surgery* **32**, 253-266.

48. Konstantinovic VS and Dimitrijevic B (1992) Surgical versus conservative treatment of unilateral condylar process fractures: Clinical and radiographic evaluation of 80 patients, *J Oral Maxillofac Surg***50** , 349-357.

49. Ellis E, McFadden D, Simon P and Throckmorton G (2002) Surgical complications with open treatment of mandibular condylar process fractures, *J Oral Maxillofac Surg* **58**, 950-959.