

Full Length Research Paper

Caprine Coccidiosis: An outbreak in the Green Mountain in Libya

M.A.M. Sharif^{1,2*}, M.M.A. Alagab², I.M. Eldaghayes^{2,3}, A.M. Kammon^{2,3} and A.S. Dayhum^{2,3}

¹Department of Pathology, Faculty of Veterinary Medicine, University of Omar Al-Mukhtar, Albeida, Libya.

²National Center of Animal Health (NCAH), Libya.

³Faculty of Veterinary Medicine, University of Tripoli, Libya.

Received 24 January 2014; Accepted 21 April 2015

This study involved a herd consisting of 200 goats in Green Mountain area, suffering from decrease in weight gain, bloody diarrhoea and severe anaemia and in some cases death within few days. Generally, there was no response to the treatment with antibiotics, anthelmintics and multivitamins. The last animal that died was submitted for post-mortem examination. The disease affecting the herd was diagnosed as coccidiosis. This is the first report of caprine coccidiosis in the Green Mountain Area in Libya.

Key words: Coccidiosis, *Eimeria*, caprine, goat, small ruminant, Libya.

INTRODUCTION

Coccidiosis is an economically important disease. It affects a wide range of animals including cattle, sheep, goats, horses, camels, dogs and cats as well as different avian species (Hussein et al., 1987; Foreyt, 1997; Taylor et al., 2007; Pangasa and Singla, 2007; Pangasa et al., 2007; Singla et al., 2007). In goats and sheep, coccidiosis causes enteric disease resulting in diarrhea, inefficient weight gains and occasionally death (Foreyt, 1990). The disease in small ruminants is caused by some species of the genus *Eimeria* including *Eimeria christenseni*, *Eimeria caprina*, *Eimeria arloingi*, *Eimeria hirci*, *Eimeria ninakohlyakimovae*, *Eimeria aligevi* (Foreyt, 1997). Infection of goats with coccidiosis occurs through ingestion of sporulated oocysts. In the small intestine, sporulated oocysts release sporozoites which infect intestinal epithelial cells (Foreyt, 1990). The *Eimeria* spp are host-specific and are not transmitted from sheep to

goats. *E. arloingi*, *E. christenseni* and *E. ovinoidalis* are highly pathogenic in goat kids. The parasite is responsible for more 50% of the cases that showed hemorrhagic diarrhea in goat (Radad and Khalil, 2011). Clinical signs include diarrhea with or without mucus or blood, dehydration, emaciation, weakness, anorexia, and death. Some goats show constipation and die acutely without diarrhea (Kahn and Line, 2010).

Usually, stages and lesions are confined to the small intestine, which may appear congested, hemorrhagic, or ulcerated, and have scattered pale, yellow to white macroscopic plaques in the mucosa. Histologically, villous epithelium is sloughed and inflammatory cells are seen in the lamina propria and submucosa (Kahn and Line, 2010). The intestinal whitish nodules show proliferative enteritis with presence of different stages of the *Eimeria* in the hyperplastic epithelium (Kheirandish et

*Corresponding author. E-mail: m_sharif2000de@yahoo.com.

Author(s) agree that this article remain permanently open access under the terms of the [Creative Commons Attribution License 4.0 International License](http://creativecommons.org/licenses/by/4.0/)

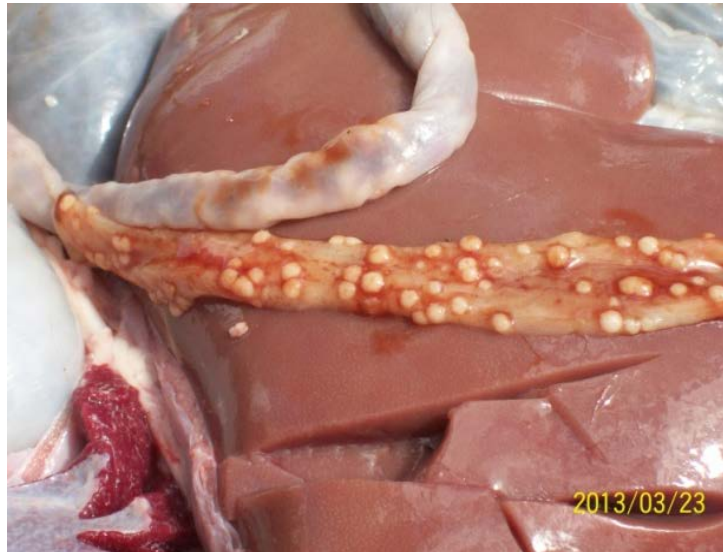


Figure 1. Diffuse thickened intestinal mucosa with white multiple nodules at the surface and with haemorrhagic fluid content.

et al., 2012). In addition, hepatobiliary coccidiosis with liver failure in dairy goats has been reported (Kahn and Line, 2010). Here the first report of caprine coccidiosis in the Green Mountain Area in Libya is documented.

MATERIALS AND METHODS

A herd consisting of 200 heads of goats in a region belonging to Almarj city in the Green Mountain area was suffering from various symptoms. Subclinical cases which occur in most animals and in different ages which showed decrease in feed intake and weight gain, and with the absence of diarrhoea was looked into. Symptoms of clinical cases which occurred mainly in young animals less than one year old varied from some loss of appetite and decrease in weight gain and slight, short lived diarrhoea to severe cases involving great amounts of dark, bloody and foul smelling diarrhoea, fluidy feces containing mucous and blood, anaemia, loss of weight, rough hair coat, dehydration, and in some cases (11 cases) death within few days. Generally, there was no response to the treatment with antibiotics such as oxytetracycline, penicillin and gentamycin and many other anthelmintics and multivitamins. An animal that died was submitted for post-mortem examination. The excessive mesenteric attachments were trimmed off from the intestines and lymph nodes. Later on, the intestinal samples were cut into suitable segments. Fixation was carried out using 10% neutral buffered formalin. Samples were subjected to further processing steps that included dehydration, clearing, embedding, sectioning of 5 μ m thickness and routine Haematoxylin & Eosin staining. All slides were examined using light microscopy.

RESULTS

Gross pathology

Post-mortem examination revealed that the animal suffered from severe anaemia and moderate dehydration, the intestinal mucosa was thickened with a white nodular

surface and focal areas of haemorrhage (Figure 1). All other organs showed no significant pathological changes.

Laboratory results

Histopathological examination of hematoxylin and eosin (H&E) stained sections of jejunum revealed proliferative changes in the intestinal villi (Figure 2) and presence of different stages of coccidia in the enterocytes (Figure 3). Examination of mesenteric lymph nodes showed lymphocytic depletion and mild neutrophilic infiltration. All other organs showed no significant pathological changes. Microscopic examination of wet smear from the formalin fixed mucosa shows coccidia oocysts in the epithelial tissue (Figure 4).

DISCUSSION

Sheep and goat farming in Libya especially in the green mountain area is based on an outdoor grazing system which in combination with periods of high stocking density and poor husbandry contributes to an increased incidence of infectious diseases among different livestock. In case of coccidiosis, such grazing system helps to deposit oocysts from either infected or carrier animals into the environment and vice versa to infect new animals (Foreyt, 1997). Destruction of intestinal mucosa by coccidia results in hemorrhagic enteritis, as observed also in our report. In our case, histologically, intestinal mucosa showed proliferation of intestinal villi and presence of different coccidial stages in enterocytes. Moreover, mesenteric lymph nodes were slightly enlarged and showed lymphocytic depletion and mild

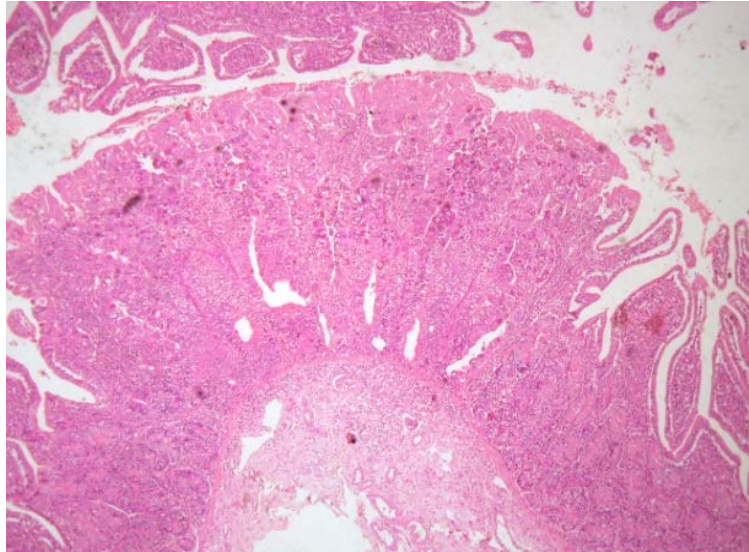


Figure 2. Histological section of jejunum showing proliferative changes of the intestinal villi. H&E stain, x40.

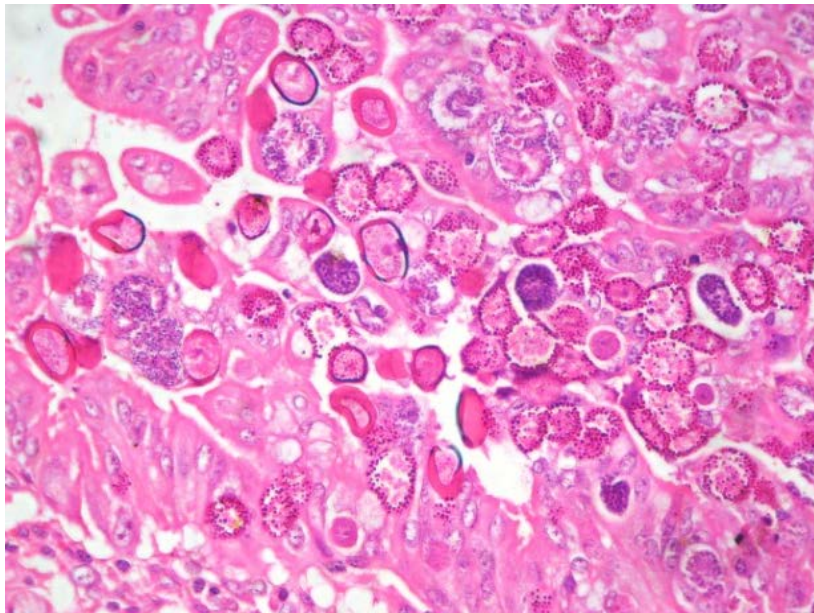


Figure 3. Presence of different stages of coccidia in the hyperplastic epithelium. H&E stain, x400.

neutrophilic infiltration. No coccidian parasites were observed in lymph nodes and recruitment of neutrophils to lymph nodes seemed to be due to secondary infection. All our results matched with previously published results (Koudela and Bokiva, 1998; Dai et al., 2006). However, coccidial schizonts were reported to be found in mesenteric lymph nodes of infected goats with *Eimeria apsheronica* (Kanyari, 1990).

Due to lack of information and the distribution of the

disease, and because the disease is not considered before the present study as one of the wasting diseases in ruminants in Libya, we advise to consider this disease as one of the responsible causes of the low production in this area and therefore, we can explain and diagnose cases due to chronic or acute coccidiosis. The parasite is widely spread and affects high percentages of sheep and goats. For example, the incidence of ovine coccidia in Egypt was 37% (Morrsy, 1983), and 41% in Saudi Arabia

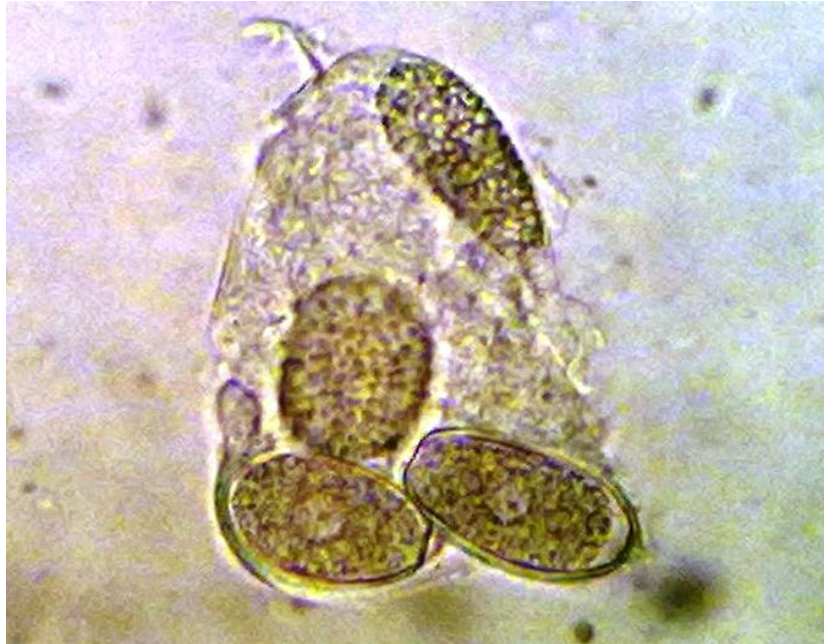

Figure 4. Microscopic examination of wet smear of the affected mucosa shows coccidia oocysts in the epithelial tissue, $\times 1000$.

(Fawzia, 2007). Therefore, screening of the disease in Libya is also highly recommended and can easily be done using the simple microscopic examination. Control is aimed firstly at preventing access of goats to large numbers of oocysts, and secondly at reducing stress in the goats' environment. The use of preventive drugs is a third avenue of control that may be necessary in high-risk situations. Occurrence of this disease in this severity can be explained and discussed by the following reasons:

1. Failure of diagnosis of veterinarians because of the lack of laboratory diagnosis in these areas and therefore they do not use the proper medication to treat or reduce the coccidial outbreaks.
2. The use of anticoccidial drugs or feed additives is uncommon for sheep and goats in Libya. Therefore, the major anticoccidial drugs such as Amprolium in water and Decoquinate, Lasalocid, Monensin, Sulfaguanidine and Sulfamethazine in feed (Foreyt, 1997; Menzies, 2012) should be used to treat and prevent the disease in sheep and goats especially in the herds that suffer from decreased feed intake and weight gain.
3. Coccidial infections are self-limiting, and the host may develop immunity. So, the life cycle in such animals is progressively inhibited (Soulsby, 1982).

CONCLUSION AND RECOMMENDATION

In contrast, young animals are more susceptible more than old animals due to the acquired immunity, but it

should be considered that old animals can be act as source of infection for young animals and treatment should be given for all animals in the herd and may be in the neighbor's herds in such cases. Since the animals in these areas rely on grazing, the use of anticoccidial drugs in the feed will be of limited importance in such cases, therefore, we recommend using the treatment and prevention in drinking water.

Conflict of interest

Authors have none to declare.

REFERENCES

- Dai YB, Liu XY, Liu M, Tao JP (2006). Pathogenic effects of the coccidium *Eimeria* ninakohlyakimovae in goats. *Vet. Res. Commun.* 30:149-160.
- Fawzia HT (2007). Prevalence and comparative morphological study of four *Eimeria* sp. of sheep in Jeddah area, Saudi Arabia. *J. Biol. Sci.* 7(2):413-416.
- Foreyt WJ (1990). Coccidiosis and cryptosporidiosis in sheep and goats. *Vet. Clin. North Am. Food Anim. Pract.* 6:655-670.
- Foreyt WJ (1997). *Veterinary Parasitology Reference Manual*. Fourth Edition, SCAVMA Bookstore USA pp. 66–69, 71.
- Hussein HS, Kasim AA, Shawa YR (1987). The prevalence and pathology of *Eimeria* infections in camels in Saudi Arabia. *J. Comp. Pathol.* 97:293-97.
- Kahn CM, Line S editors (2010). *The Merck Veterinary Manual*, 10th Edition, MERCK & CO., INC. and WHITEHOUSE STATION, N.J., USA.
- Kanyari PW (1990). *Eimeria* apsheronica in the goat: endogenous development and host cellular response. *Int. J. Parasitol.* 20:625-30.

- Kheirandish R, Nourollahi-Fard SR, Yadegari Z (2012). Prevalance and pathology of coccidiosis in goats in southeastern Iran. *J. Parasit. Dis.* 38(1):27-31.
- Koudela B and Bokiva A (1998). Coccidiosis in goats in the Czech Republic. *Vet. Parasitol.* 76:261-67.
- Menzies P (2012). Handbook for the Control of Internal Parasites of Sheep and Goats. Available at: http://www.oacc.info/DOCs/Extension/Handbook_Control_of_Parasites_of_Sheep_Dec2010.pdf.
- Morrisy NC (1983). Studies on some hygienic measures for control of ovine coccidiosis. B.V. Sc. Cairo University.
- Pangasa A, Singla LD (2007). Effect of coccidiostats and immunomodulators on haematology of *Eimeria tenella* infected broilers. *Indian Vet. J.* 84:1131-1134.
- Pangasa A, Singla LD, Sood N, Singh, Juyal PD (2007) Histopathological evaluation of anticoccidial activity of an ayurvedic coccidiostat, in induced *Eimeria tenella* infection in chicken. *Indian J. Anim. Sci.* 77(3):214-216.
- Radad K, Khalil S (2011). Coccidiosis, Paratuberculosis and Enterotoxaemia in Saudi Goats. *Braz. J. Vet. Pathol.* 4(3):219-224.
- Singla LD, Pangasa A, Juyal PD (2007). Caecal coccidiosis: efficacy of ayurvedic and allopathic coccidiostats in immunomodulated broiler chicks. Proceedings of the 12th International Conference of the Association of Institutions of Tropical Veterinary Medicine held from August 19-22, 2007 at Montpellier, France pp. 89-93.
- Taylor MA Coop RL, Wall RL editors (2007). *Veterinary Parasitology*, 3rd edition. Blackwell Publishing, Oxford UK.
- Soulsby EJJ (1982). *Helminths, arthropods and protozoa of domesticated animals* (7th edition). London: Bailliere Tindall, pp. 598, 599.